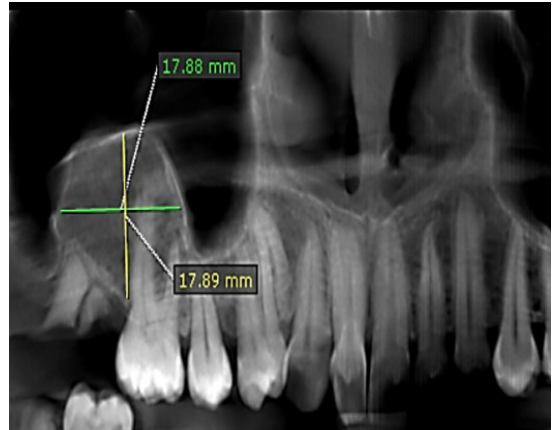
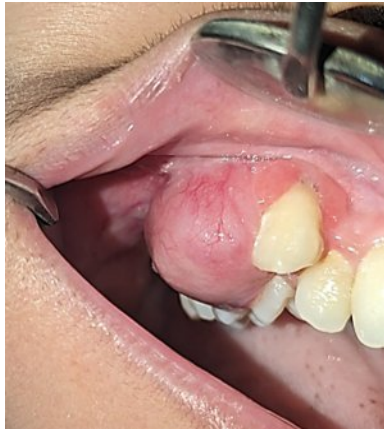
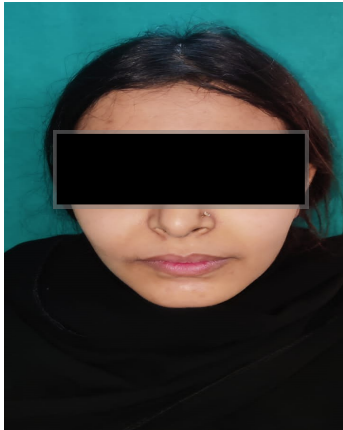
**NAME : AFSHAN JABEEN AGE/SEX : 30/F OP NO : 202312280104**

**DIAGNOSIS : PERIPHERAL OSSIFYING FIBROMA INVOLVING RIGHT MAXILLA**

**TREATMENT : SURGICAL EXCISION OF THE LESION**

**PROFESSORS : Dr G KOMALI POSTGRADUATE : Dr KONDA MAHITHA**

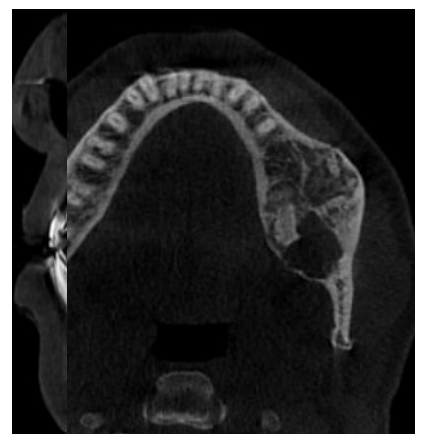
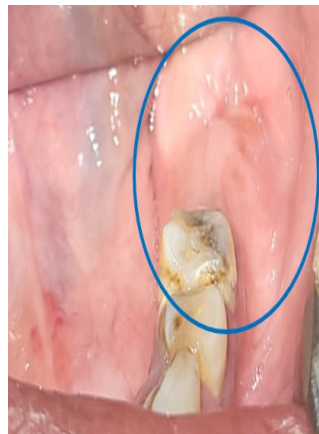
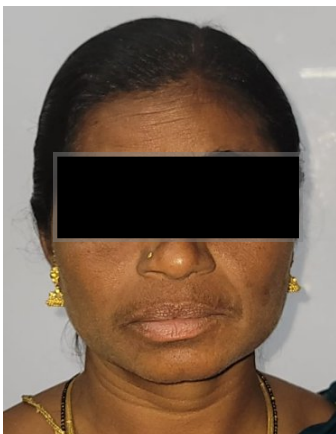
**NAME : L RUKAMMA AGE/SEX : 42/F OP NO : 202308220015**

**DIAGNOSIS : AMELOBLASTOMA INVOLVING EDENTULOUS REGION**

**TREATMENT : SURGICAL EXCISION OF THE LESION**

**PROFESSORS : Dr B RAJ KUMAR POSTGRADUATE : Dr SRUSHTI BACHUWAR,  
Dr VARSHINI THUMMU**



**NAME : B MOHAN AGE/SEX : 54/M OP NO : 202401230062**

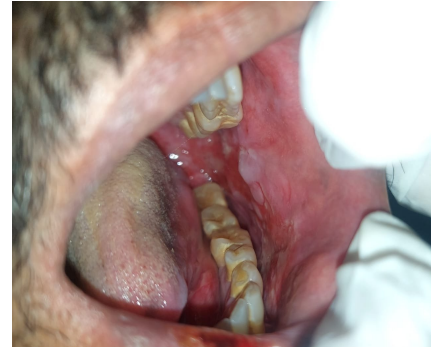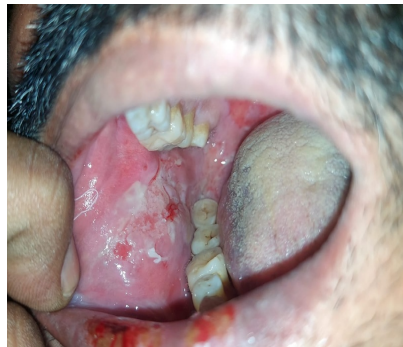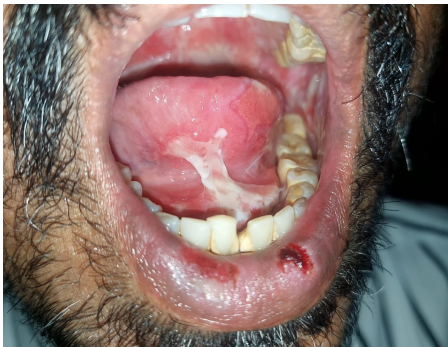**DIAGNOSIS : PEMPHIGUS VULAGRIS**

**TREATMENT : SYSTEMIC CORTICOSTEROIDS FOLLOWED BY  
IMMUNOMODULATION THERAPY**

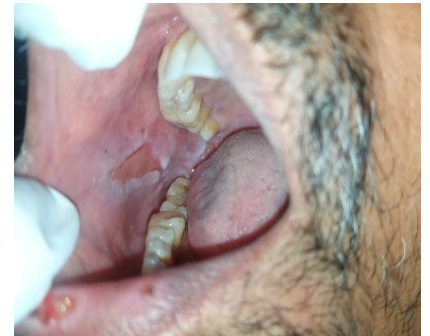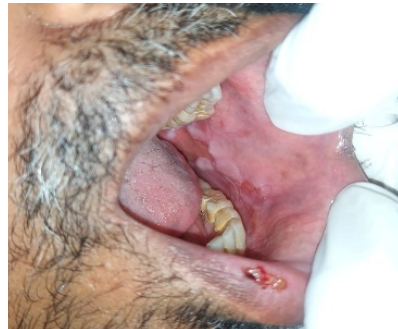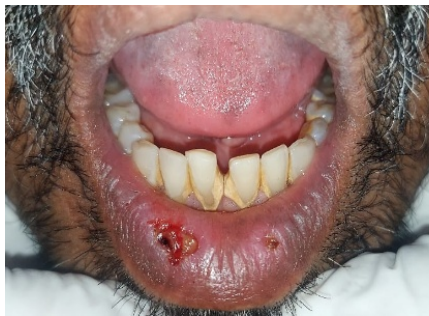**PROFESSORS : Dr B MAMATHA**

**POSTGRADUATE : Dr AKULA SONISHA**

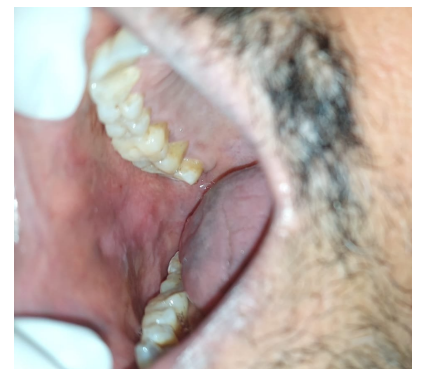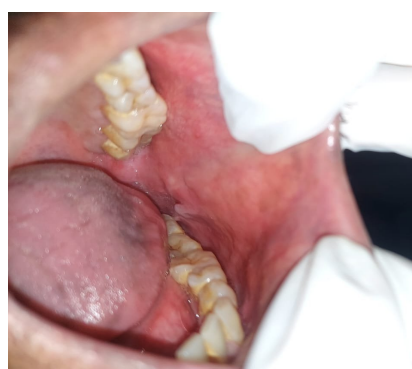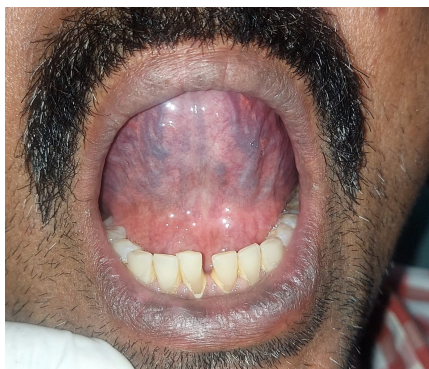**PRE TREATMENT**



**DURING MEDICAL  
MANAGEMENT**



**AFTER MEDICAL  
MANAGEMENT AND DURING FOLLOWUP**



**NAME : P VARALAXMI    AGE/SEX : 63/F    OP NO : 202508250046**

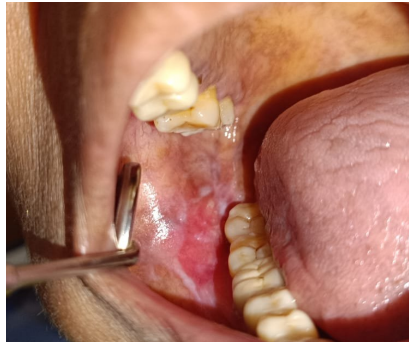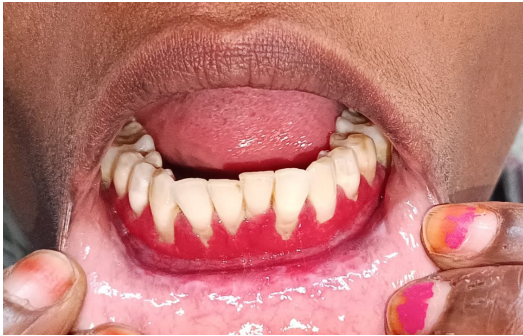**DIAGNOSIS : EROSION TYPE OF LICHEN PLANUS**

**TREATMENT : PHOTODYNAMIC THERAPY**

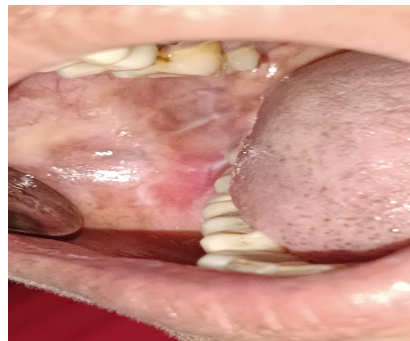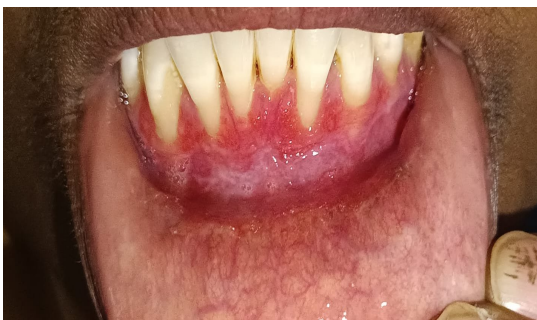
**PROFESSORS : Dr G KOMALI**

**POSTGRADUATE : Dr NIKITHA**

**PRE TREATMENT**



**POST TREATMENT**



**NAME : NAVEEN    AGE/SEX : 43/M    OP NO : 20259180021**

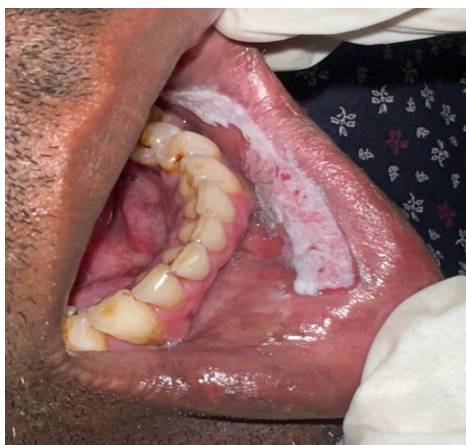**DIAGNOSIS : VERRUCOUS TYPE OF LEUCOPLAKIA**

**TREATMENT : LASER EXCISION**

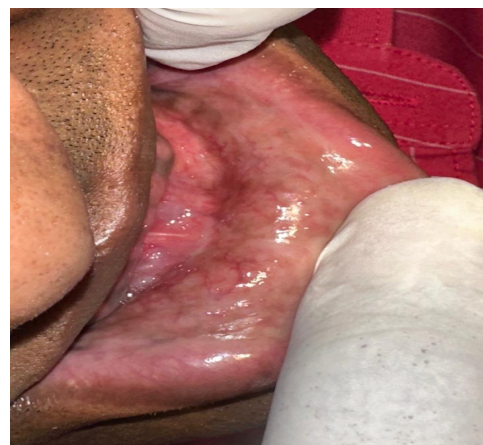**PROFESSORS : Dr B MAMATHA**

**POSTGRADUATE : Dr P JATIN**

**PRE TREATMENT**



**POST TREATMENT**



**NAME : B AADARSH**

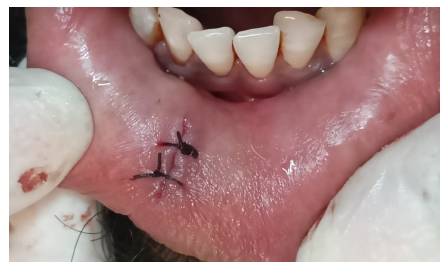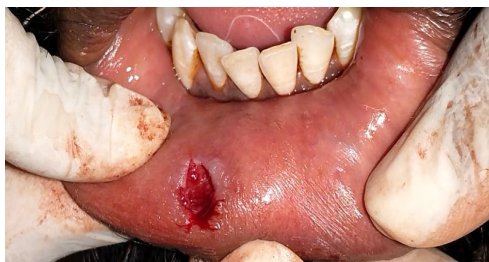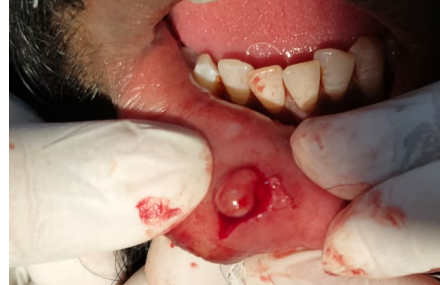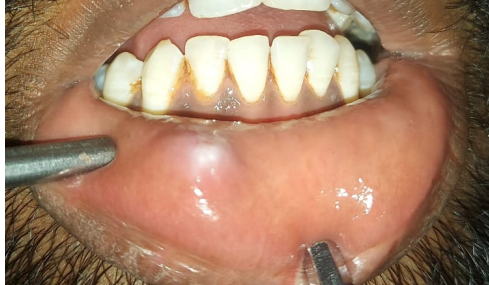**AGE/SEX : 23/M OP NO : 202604060033**

**DIAGNOSIS : MUCOCELE INVOLVING LOWER LABIAL MUCOSA**

**TREATMENT : EXCISIONAL BIOPSY**

**PROFESSORS : Dr G KOMALI**

**POSTGRADUATE : Dr AKULA SONISHA**



**NAME : ABDUL AZIZ**

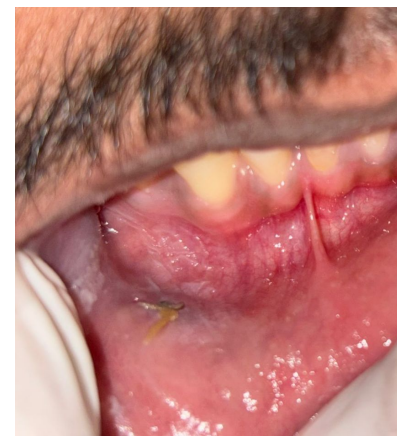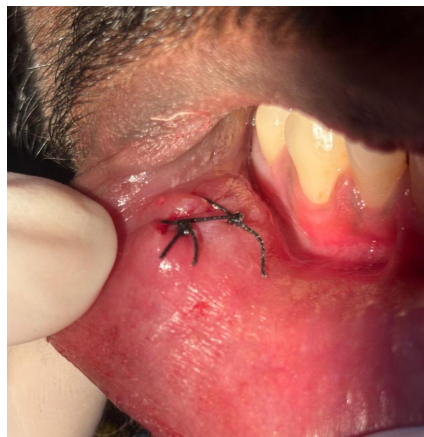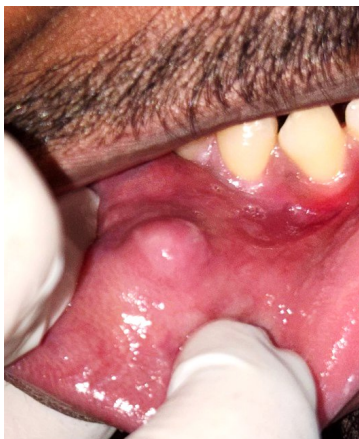**AGE/SEX : 18/F**

**OP NO : 202603280062**

**RADIOGRAPHIC DIAGNOSIS: MUCOUS EXTRAVASATION CYST INVOLVING LOWER LABIAL & BUCCAL MUCOSA IRT 44,45**

**PROFESSORS : DR G. KOMALI**

**POSTGRADUATE : DR AKANKSHA**

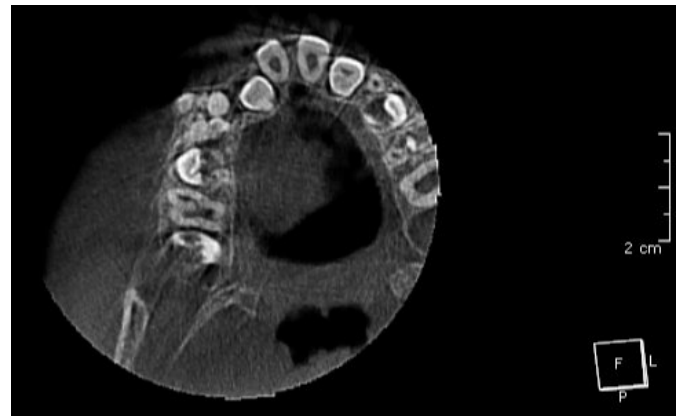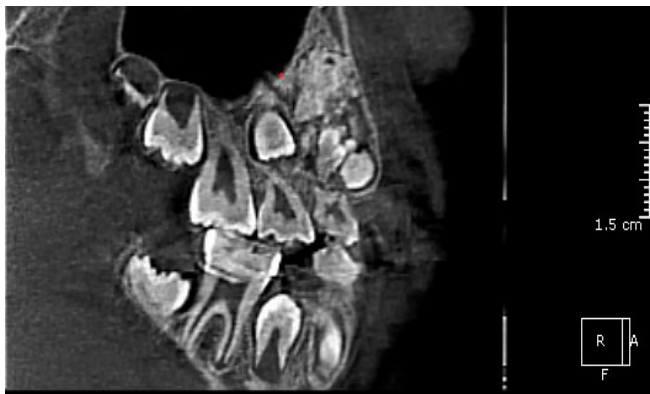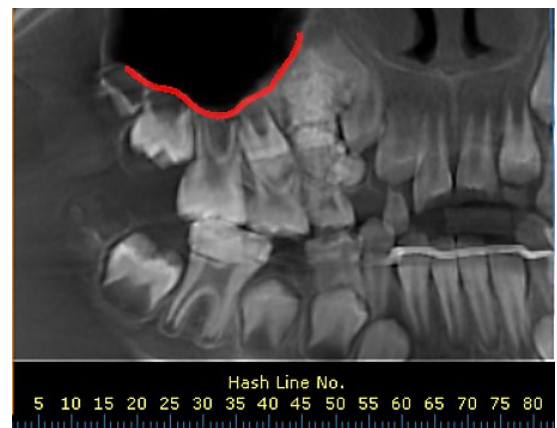
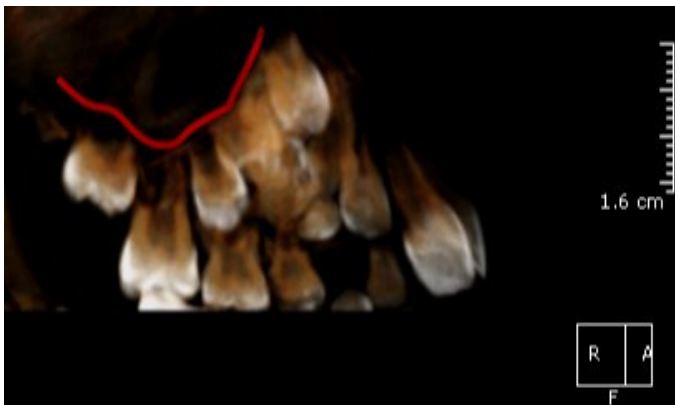


NAME : CATHERINE

AGE/SEX : 7/F

OP NO : 202412140031

**RADIOGRAPHIC DIAGNOSIS: COMPLEX AND COMPOUND ODONTOMA INVOLVING PERIAPICAL REGION IRT 54 AND CANINE REGION OF FIRST QUADRANT**



PROFESSORS : DR G KOMALI

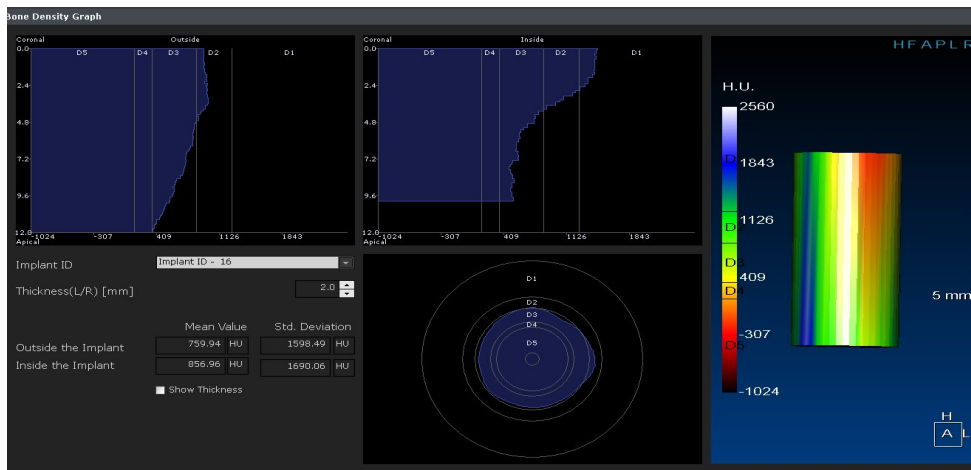
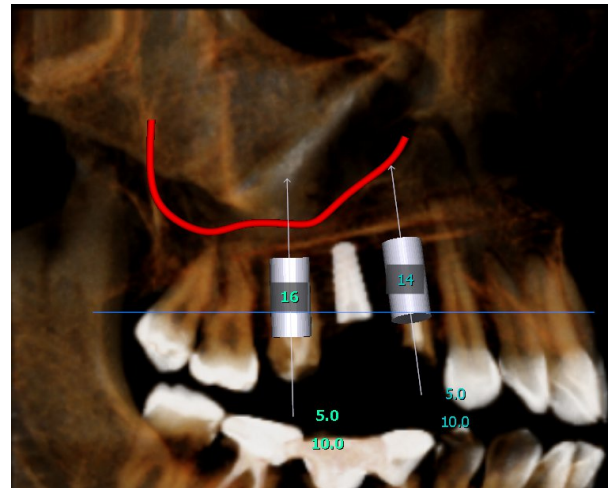

POSTGRADUATE : DR AKULA SONISHA

NAME : SHEELA PAWAR AGE/SEX : 35/F OP NO : 202601290029

RADIOGRAPHIC DIAGNOSIS: GROSSLY DECAY IRT 14, 16

PROFESSORS : DR B MAMATHA

POSTGRADUATE : DR SURAGONI LAHARI



BONE DENSITY GRAPH

NAME : RAMACHANDRA

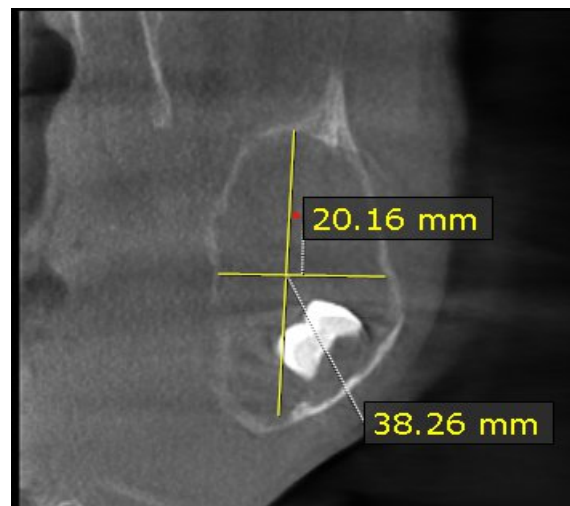
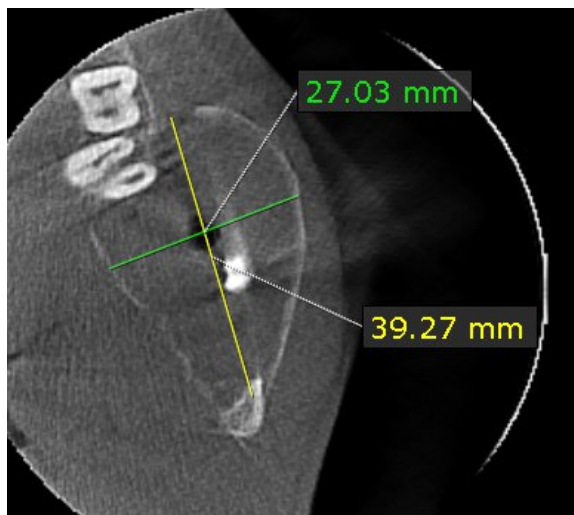
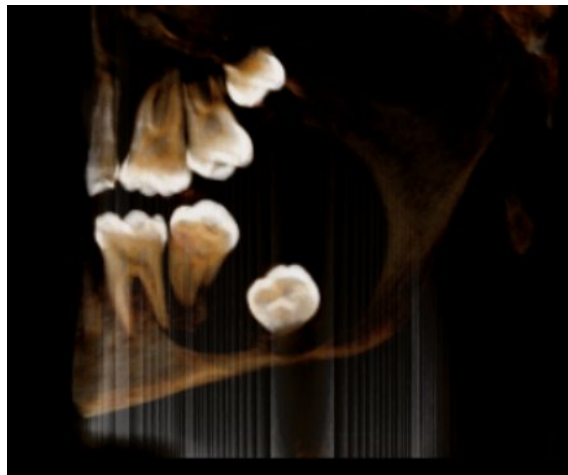
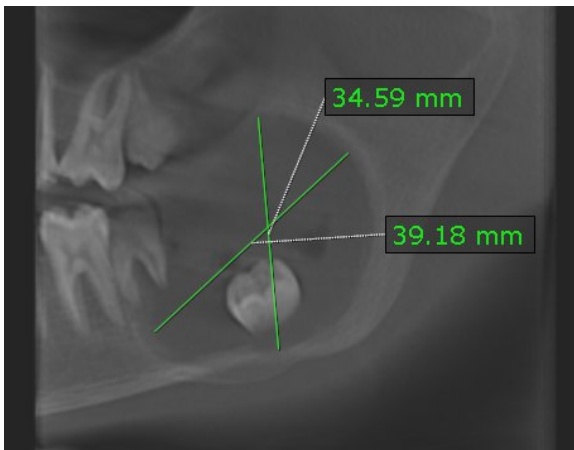
AGE/SEX : 14/M

OP NO : 202603200038

RADIOGRAPHIC DIAGNOSIS: AMELOBLASTOMA INVOLVING LEFT MANDIBLE

PROFESSORS : DR B MAMATHA

POSTGRADUATE : DR P JATIN GOUD



NAME : VAISHNAVI

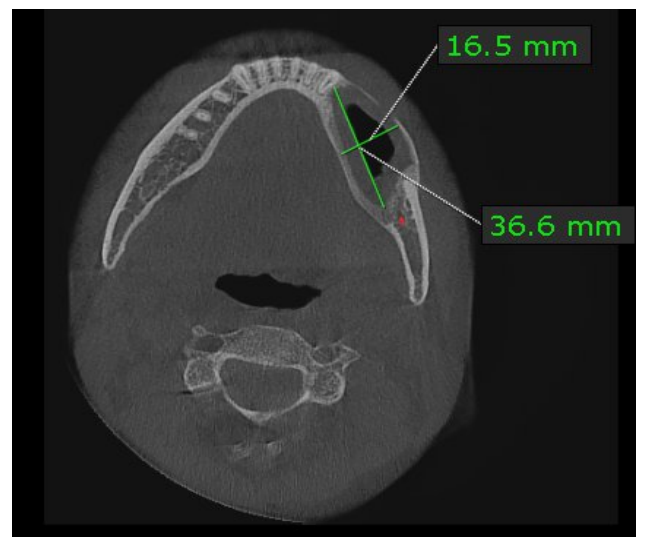
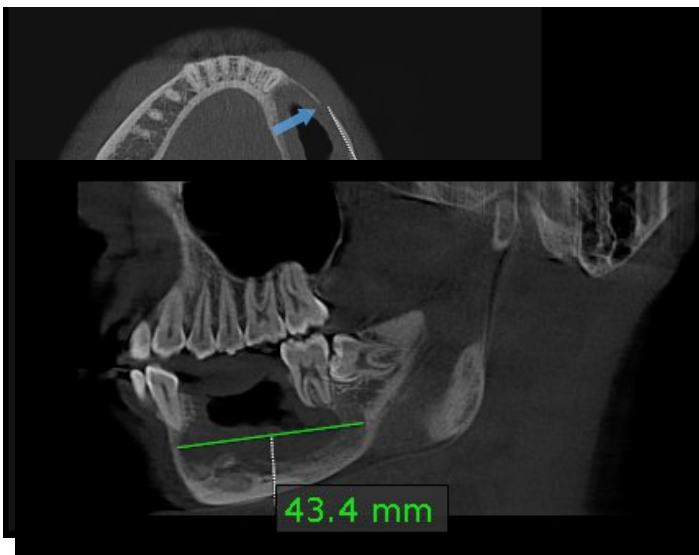
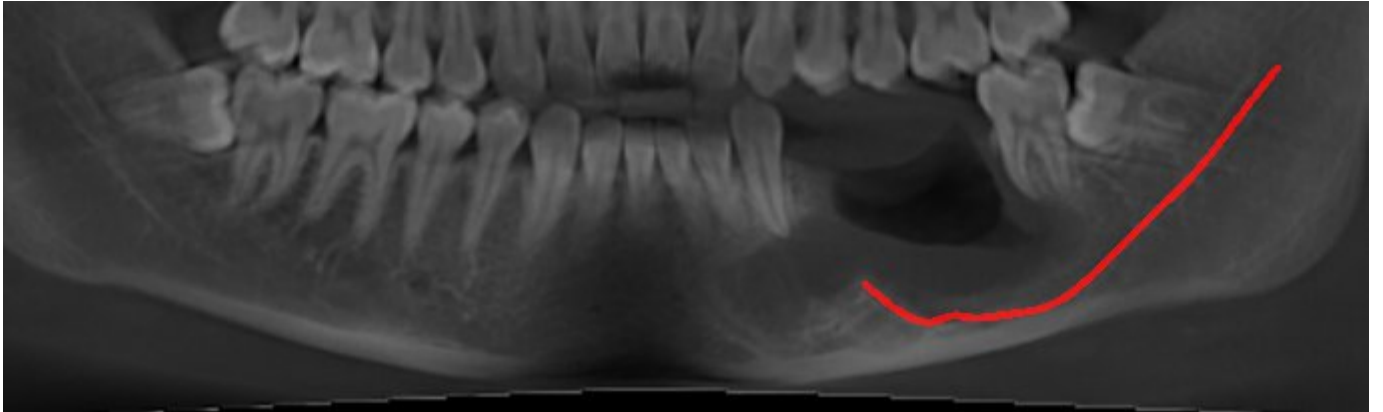AGE/SEX : 19/F

OP NO : 202412130052

RADIOGRAPHIC DIAGNOSIS: ODONTOGENIC KERATOCYST INVOLVING LEFT  
BODY OF MANDIBLE

PROFESSORS : DR B MAMATHA

POSTGRADUATE : DR SURAGONI LAHARI



NAME : SAHITHI

AGE/SEX : 14/F

OP NO : 202601050025

**RADIOGRAPHIC DIAGNOSIS: CENTRAL OSSIFYING FIBROMA INVOLVING THE RIGHT BODY OF THE MANDIBLE.**

PROFESSORS : DR B RAJ KUMAR

POSTGRADUATE : DR MANISHA

