

CASE I:

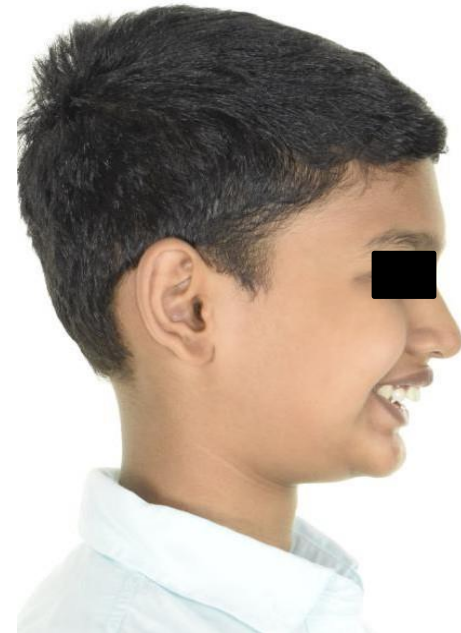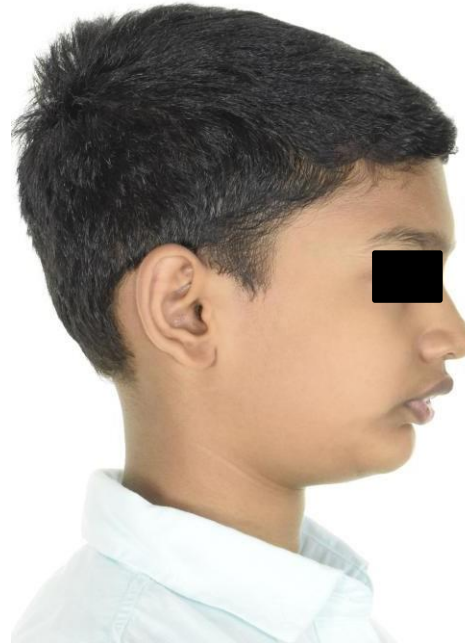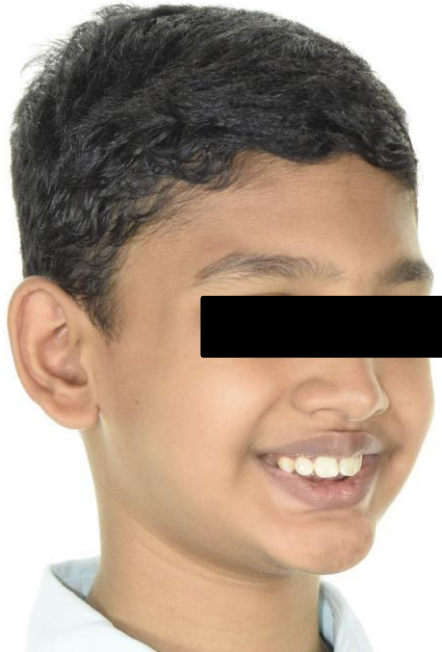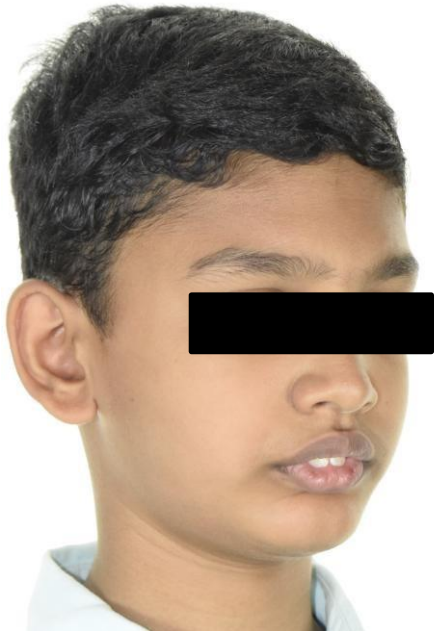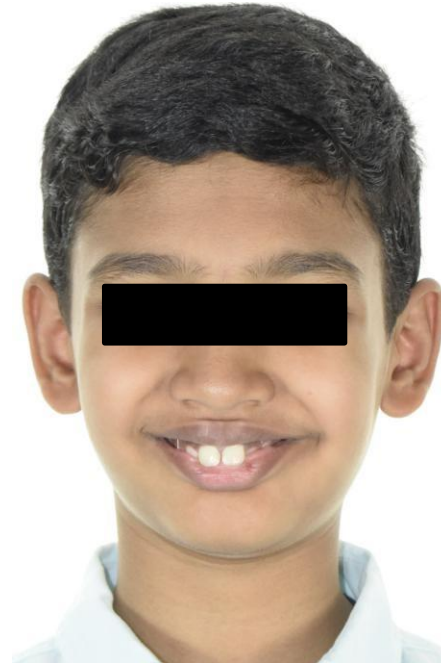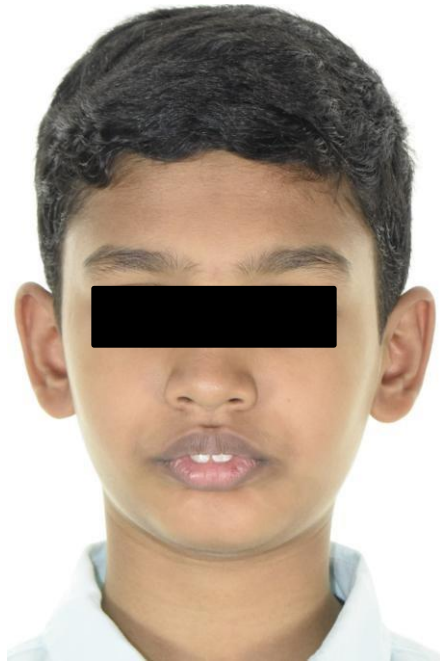NAME: DHRUV ; AGE: 12YEARS/ MALE; OPNO: 202205140025

**DIAGNOSIS: ANGLES CLASS II DIVISION 1 WITH RETROGNATHIC
MAXILLA**

**TREATMENT PLAN : TWINBLOCK WITH FIXED
MECHANOTHERAPHY**

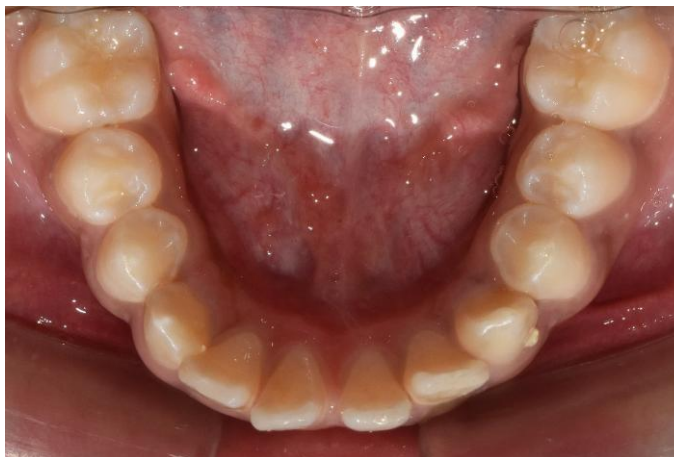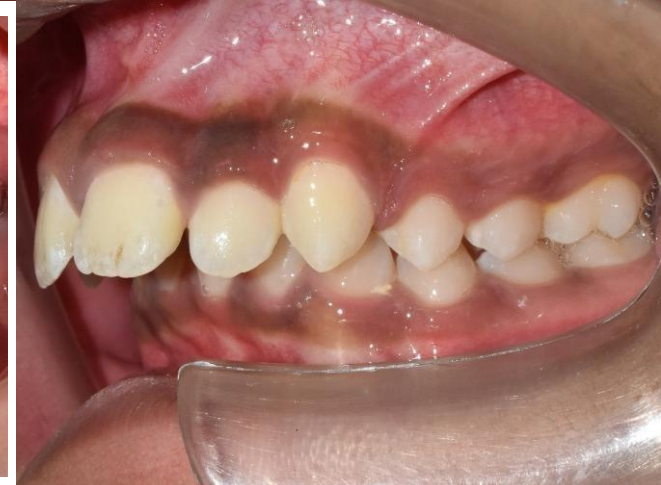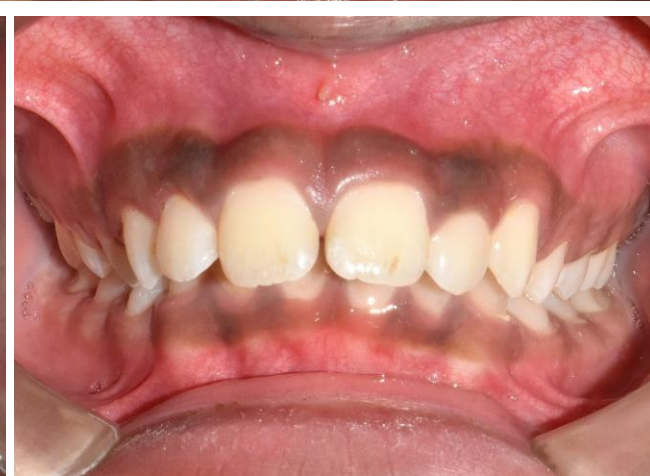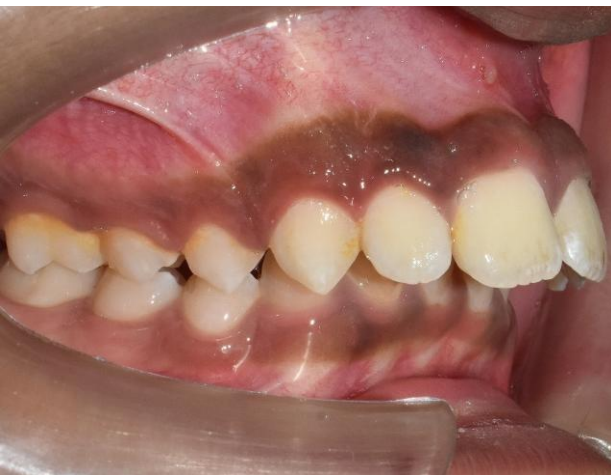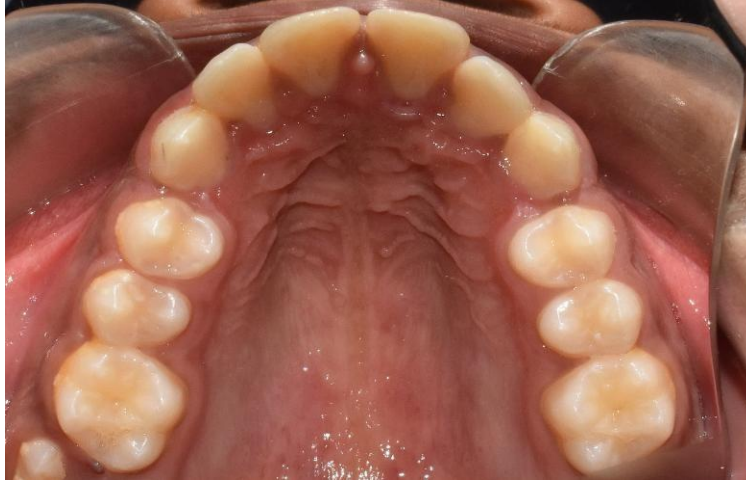**PRE TREATMENT
PHOTOS**

**NAME : DHRUV
AGE/SEX :
OP.NO :202205140025**



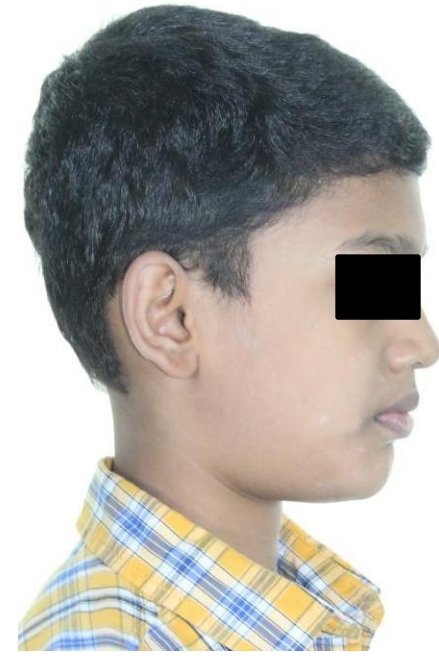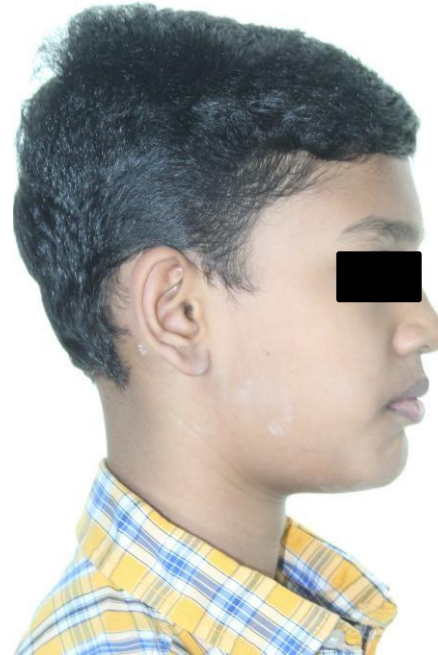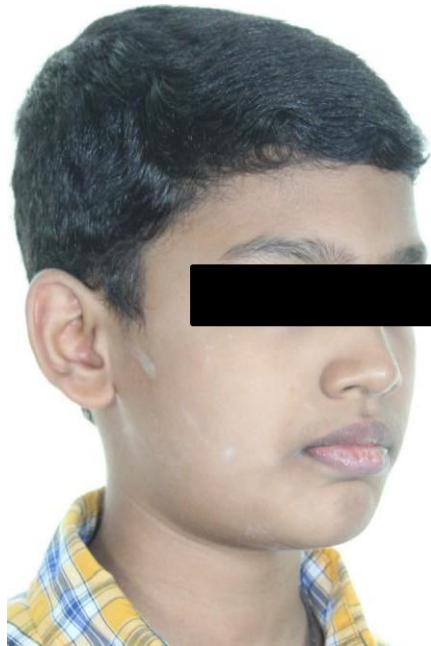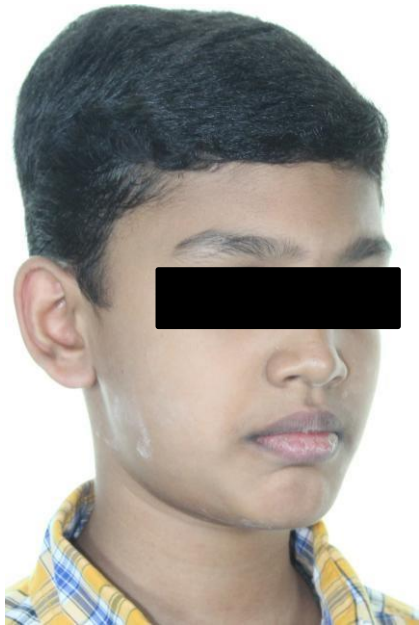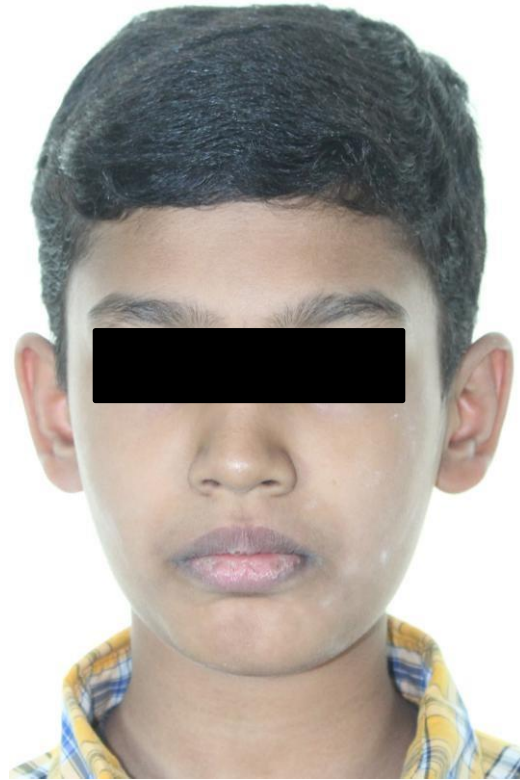**PRE TREATMENT
PHOTOS**

DHRUV

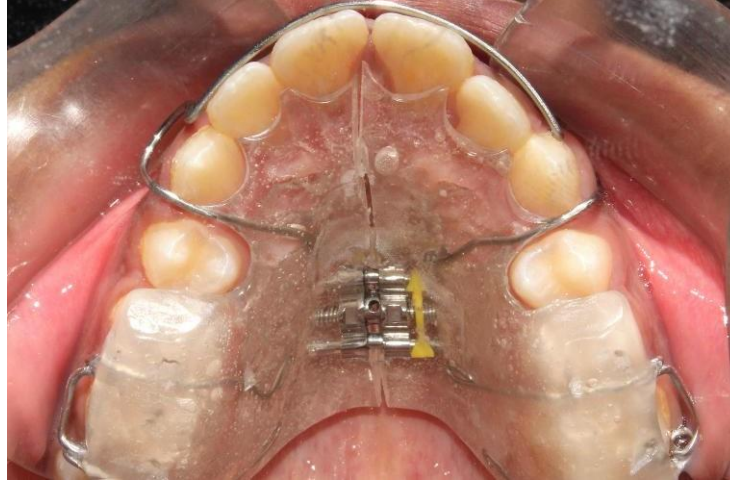


**TWIN BLOCK
EXTRAORAL
PHOTOS**

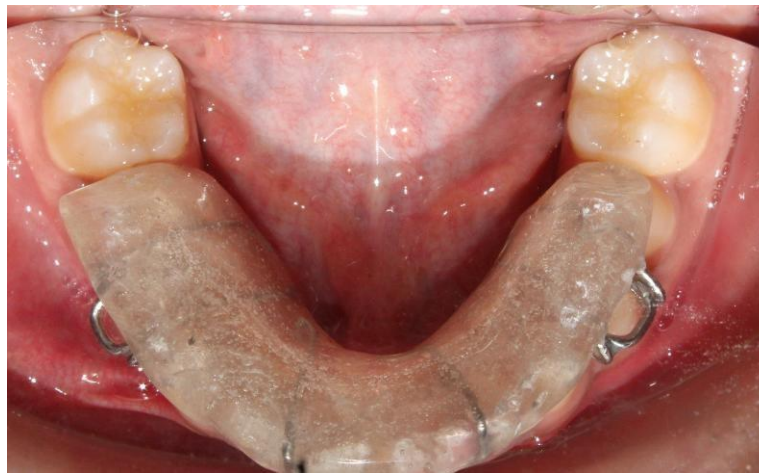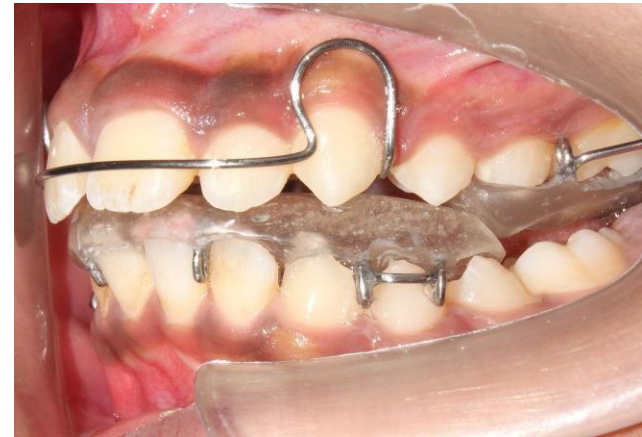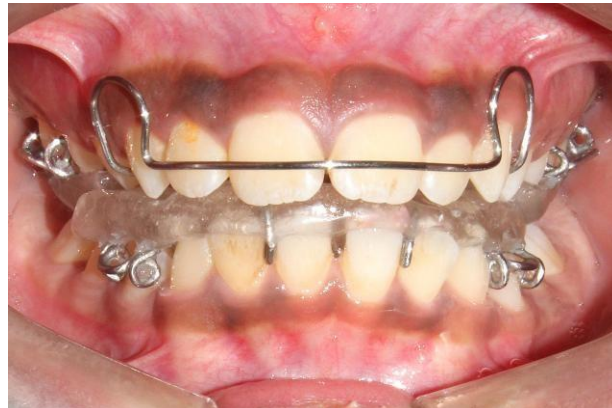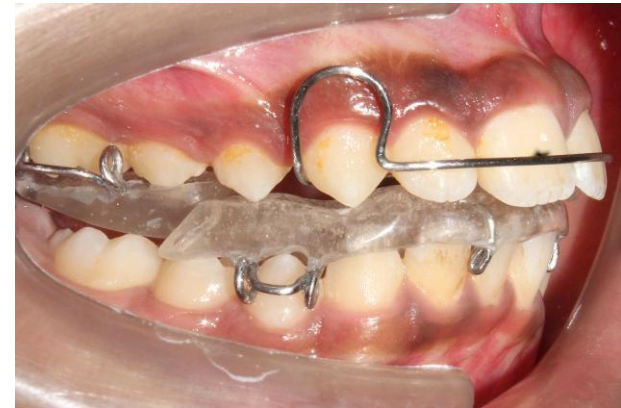**DHRUV
12Y/M**



**TWIN BLOCK
PHOTOS**

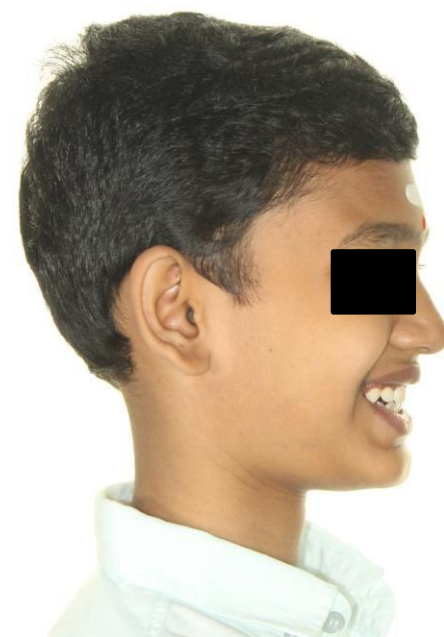
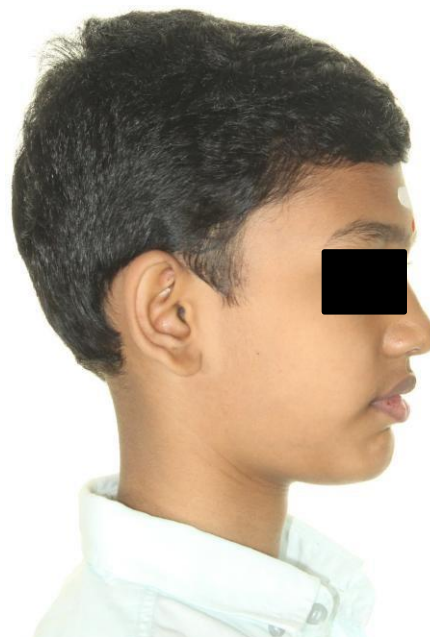
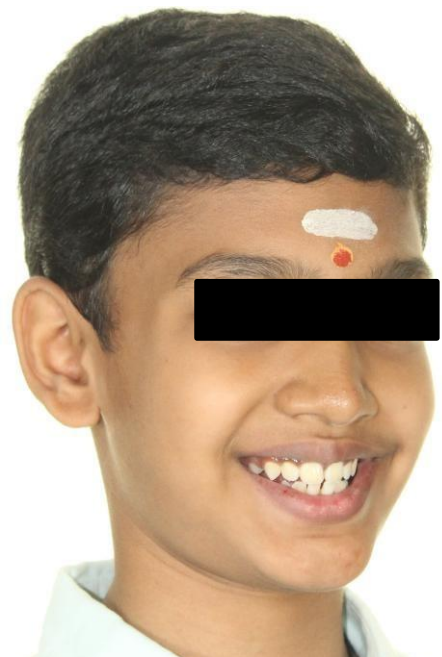
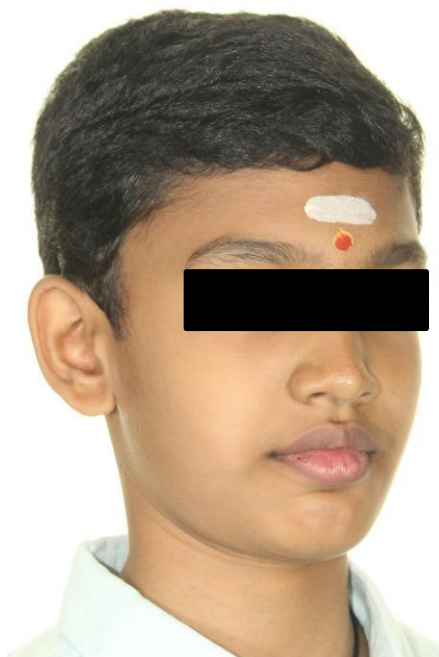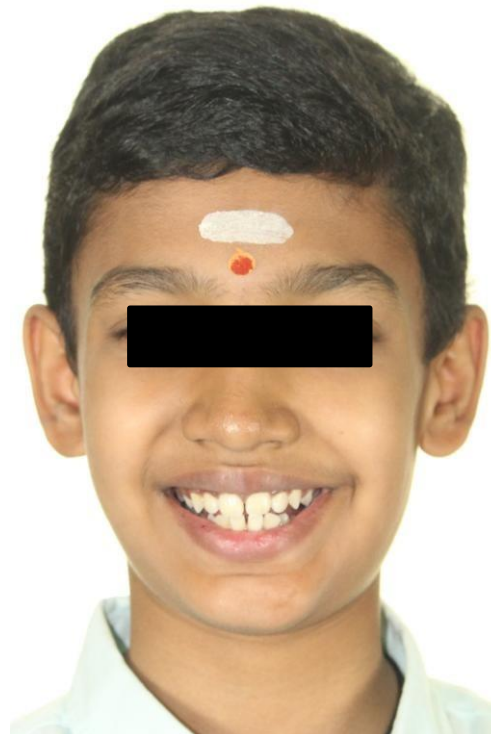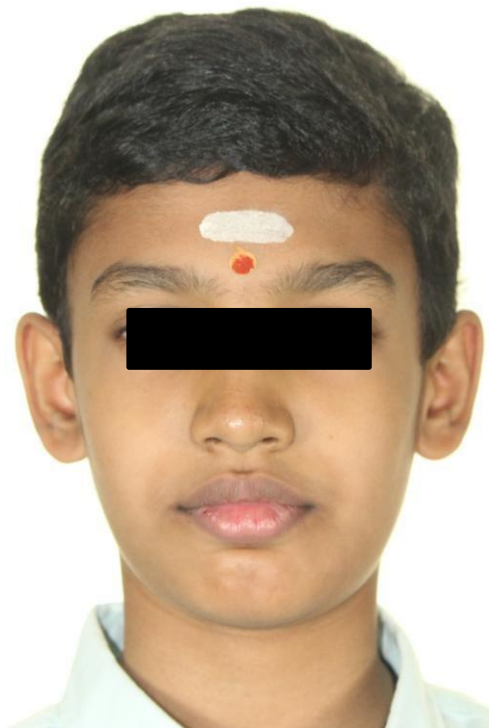DHRUV

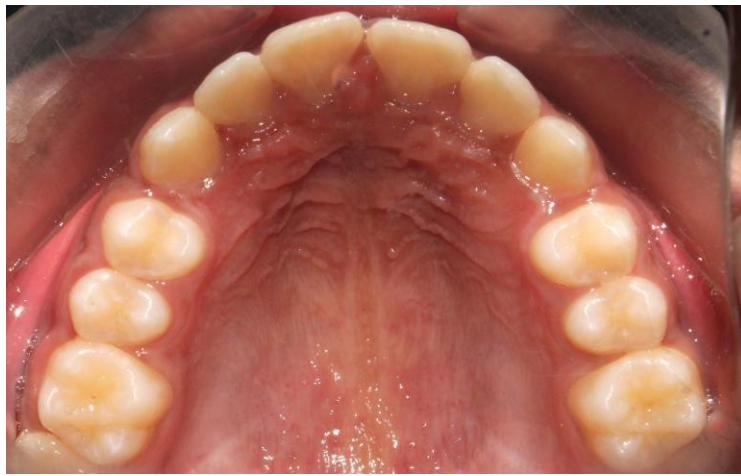

POST TWIN BLOCK
PHOTOS

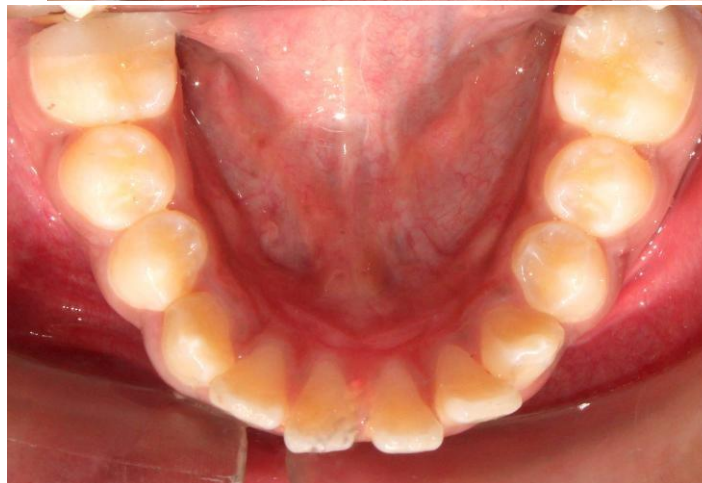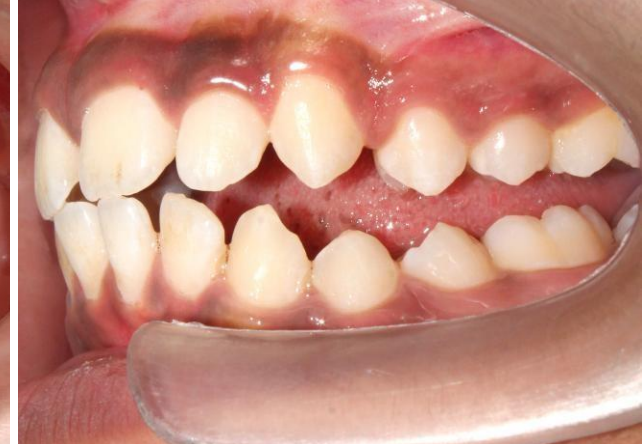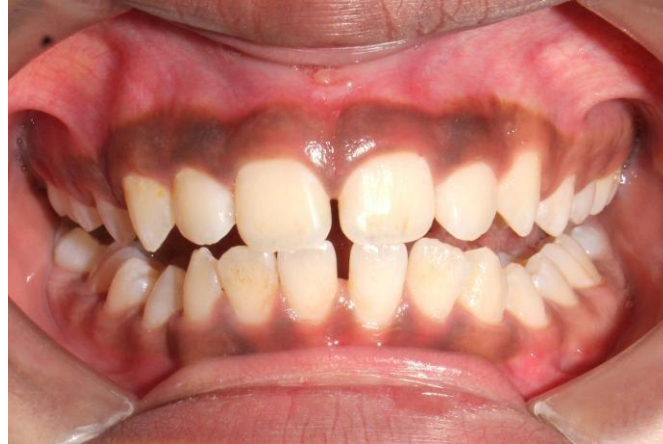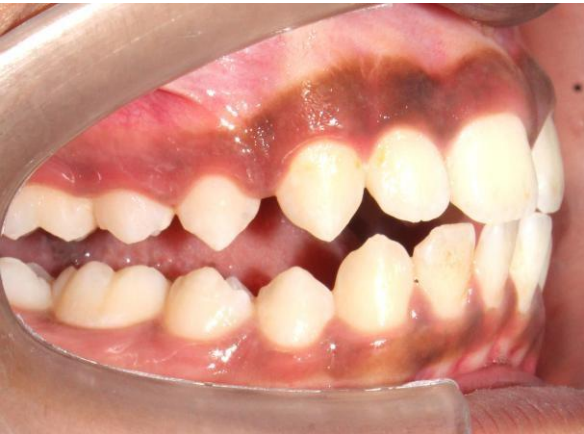DHRUV



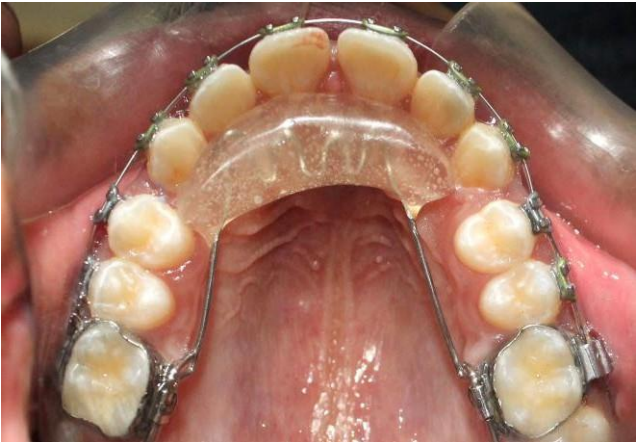**POST TWIN BLOCK
PHOTOS**



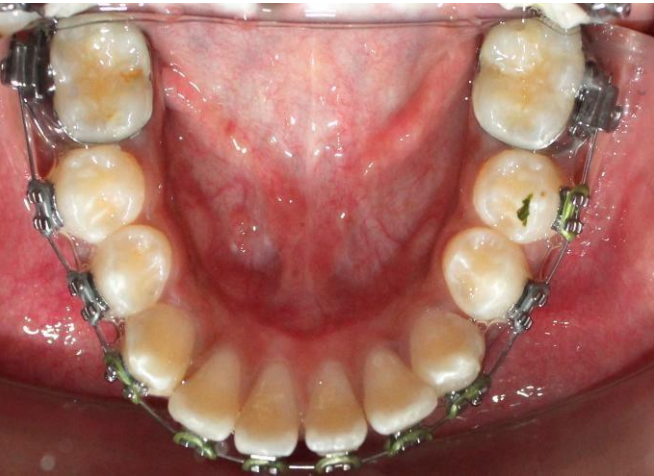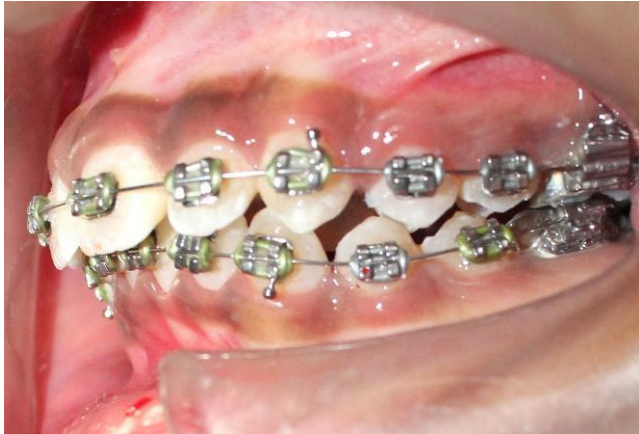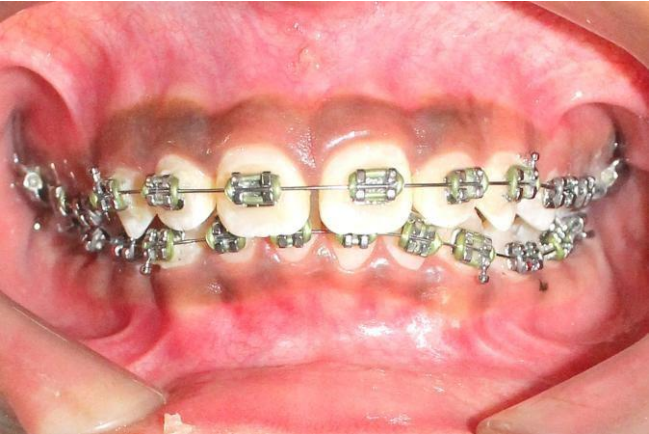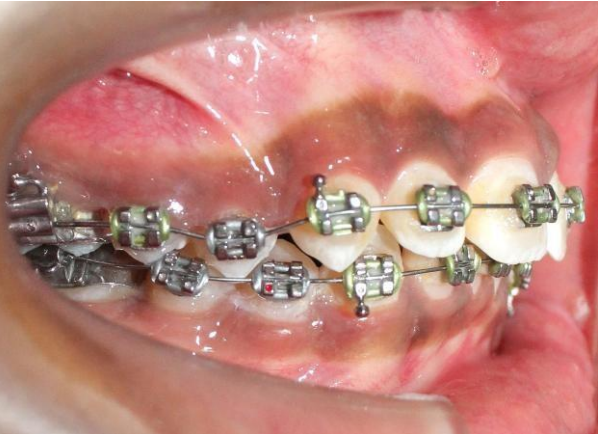DHRUV



**STRAP UP
PHOTOS**

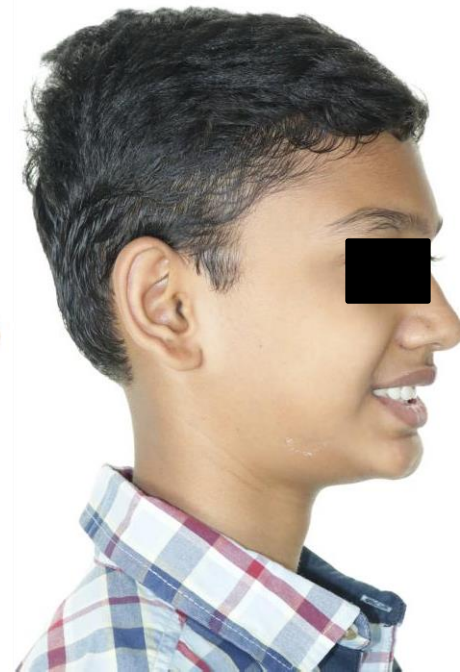
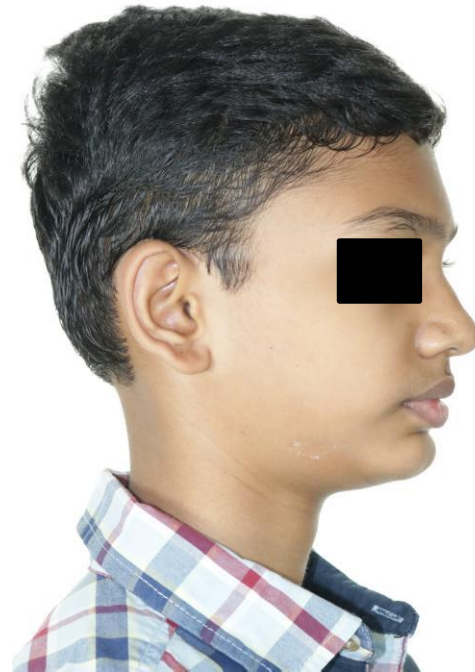
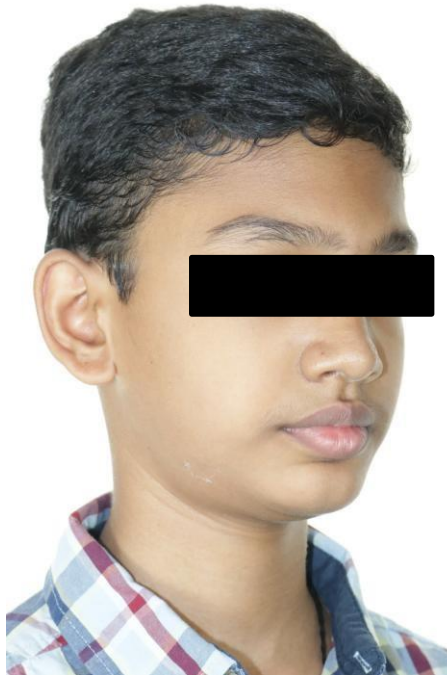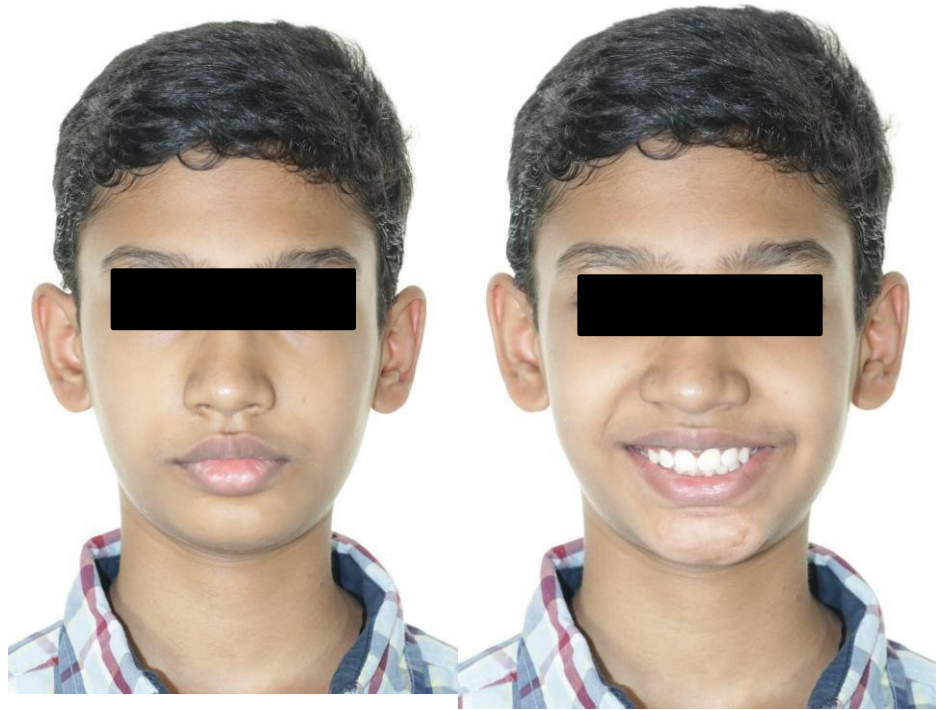DHRUV



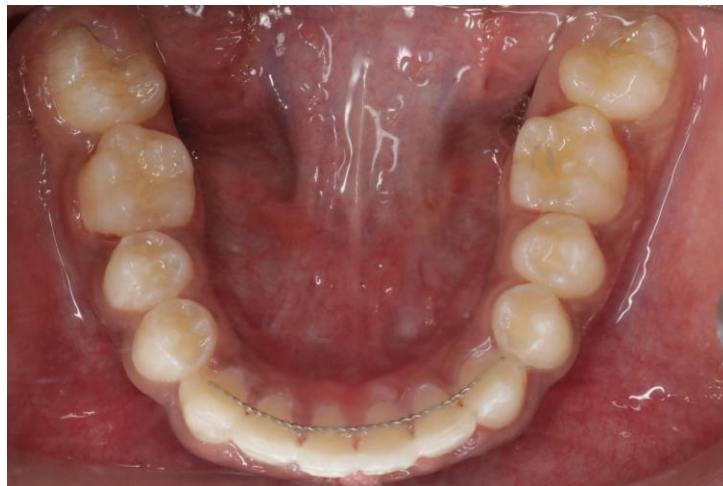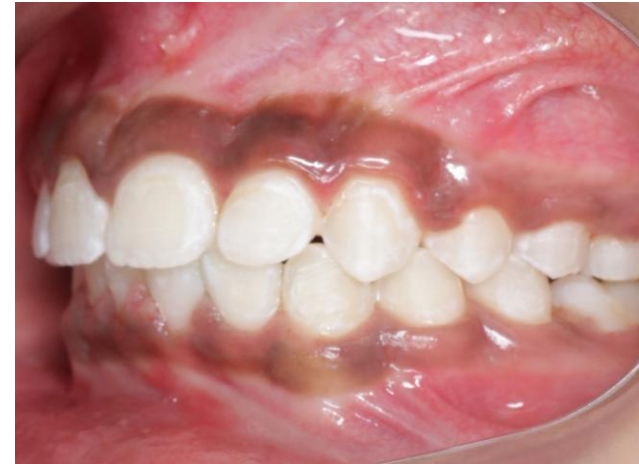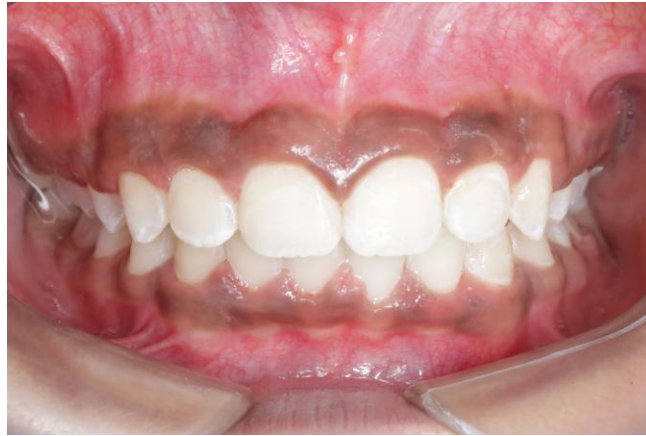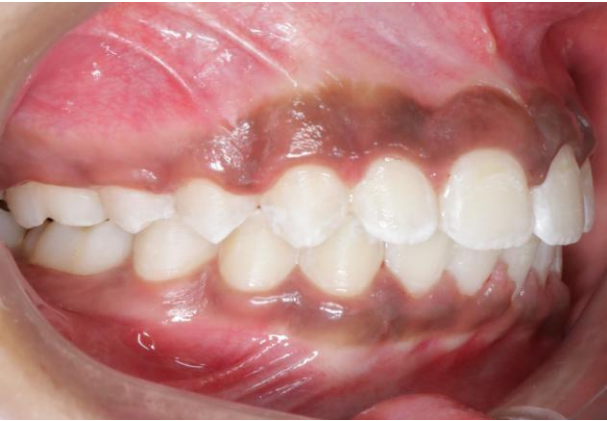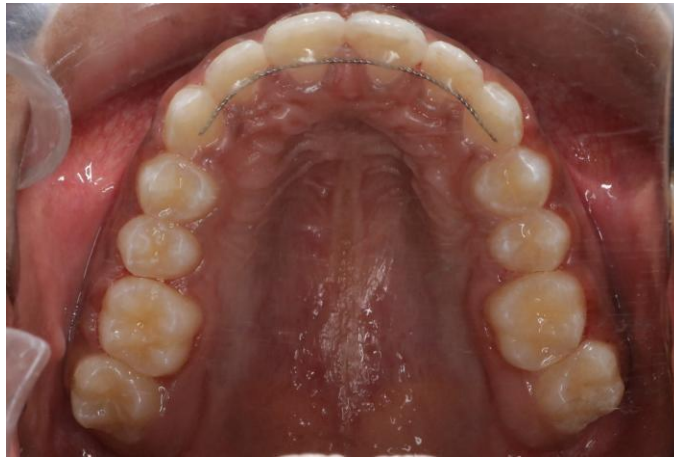**POST DEBOND
PHOTOS**

DHRUV



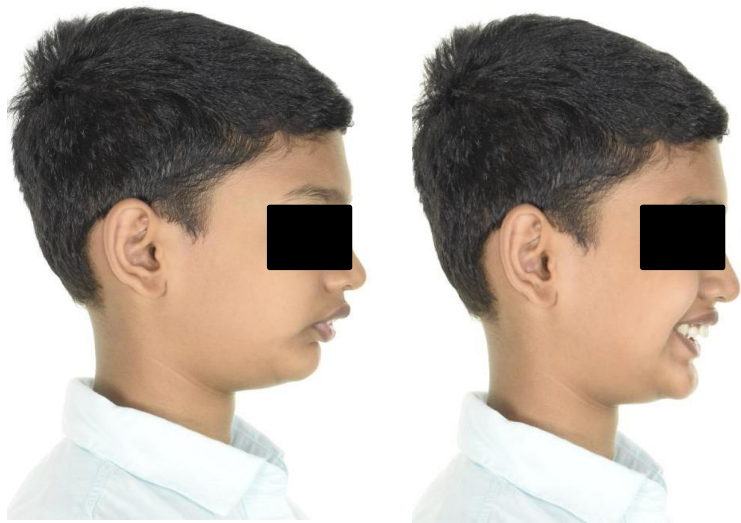
**POST DENBOND
PHOTOS**

DHRUV

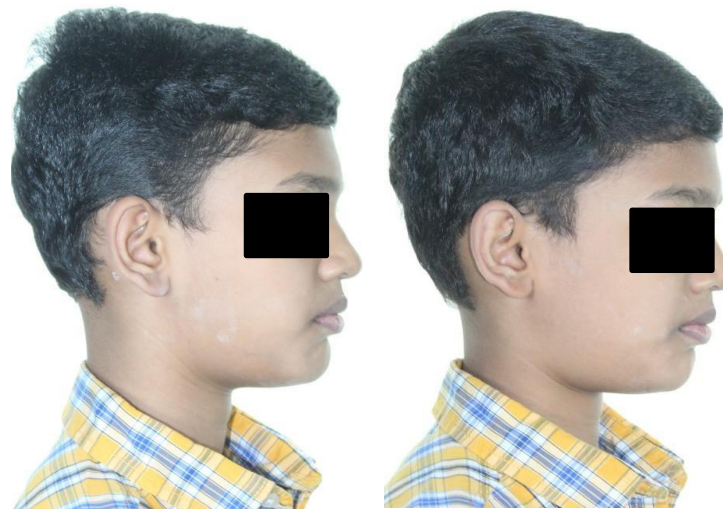

**PROFILE
PHOTOS**

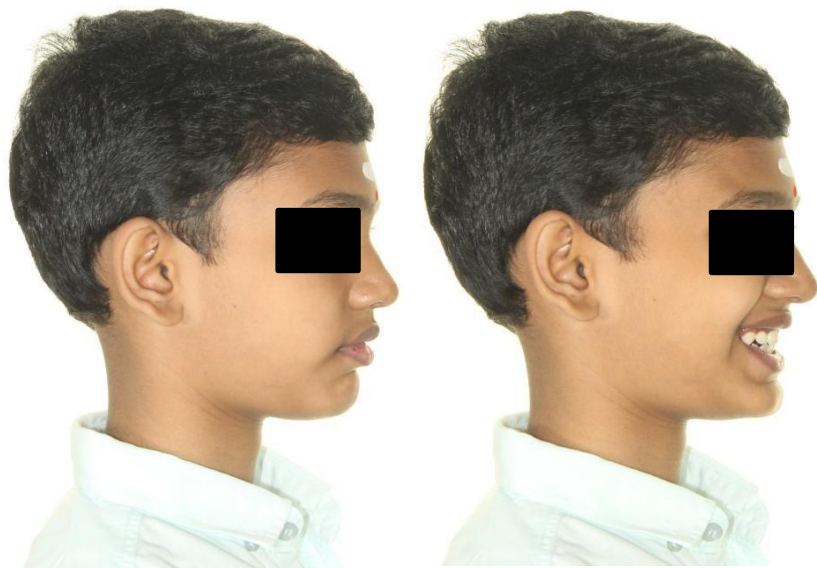**NAME : DHRUV
AGE/SEX :**



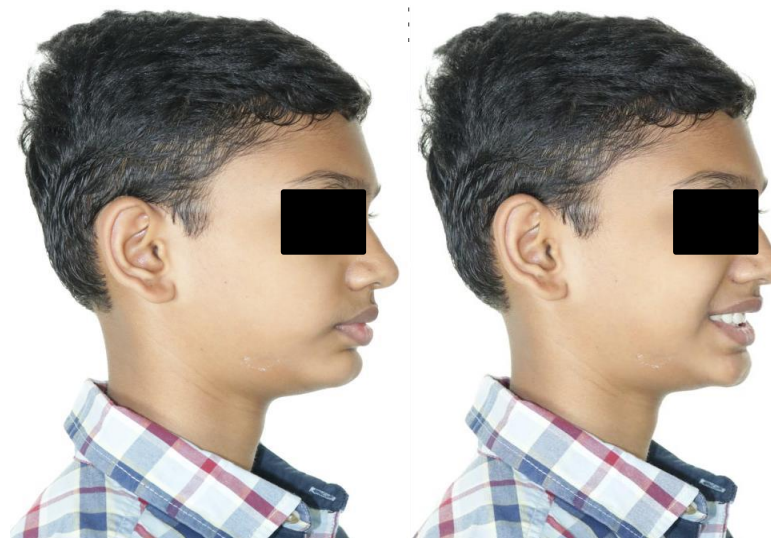PRE-TREATMENT



TWIN BLOCK-



POST TWIN BLOCK



POST-DEBOND

CASE II:

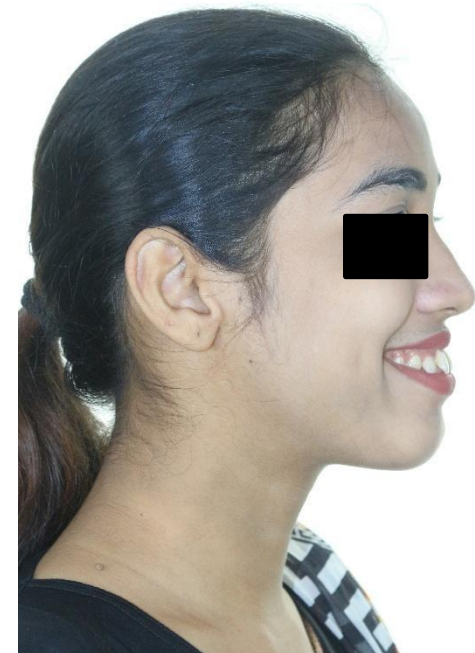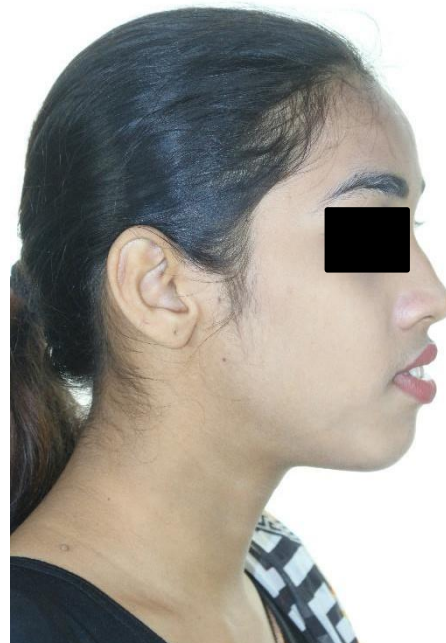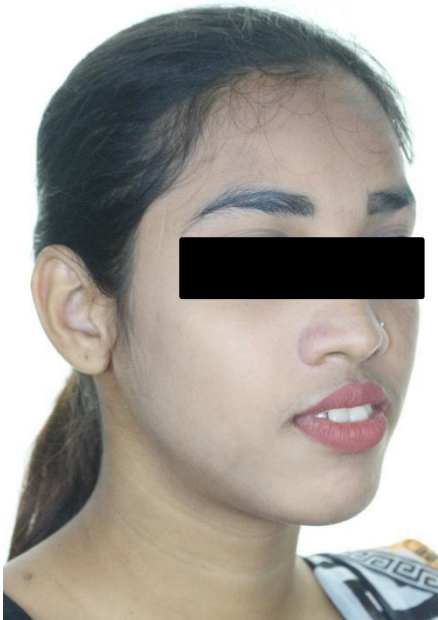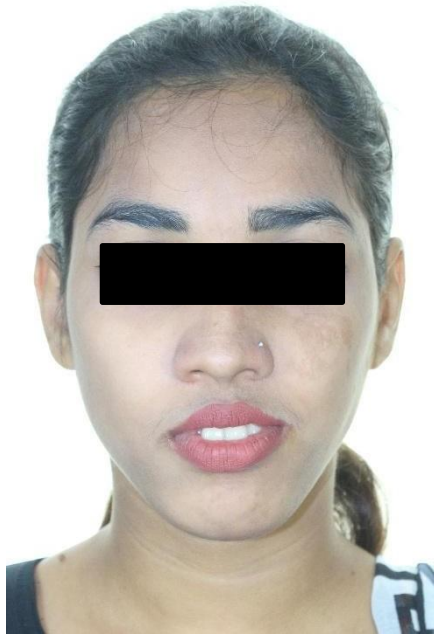NAME: ARSHIYA ; AGE: 20YEARS/FEMALE; OPNO: 2017112380004

**DIAGNOSIS: ANGLES CLASS I MALOCLLUSION WITH
BIMAXILLARY PROTRUSION**

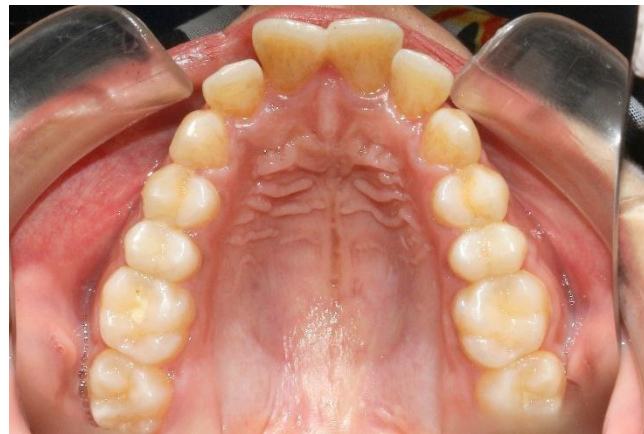TREATMENT PLAN : ALL FOUR 1ST PREMOLAR EXTRACTIONS

**PRE TREATMENT
PHOTOS**

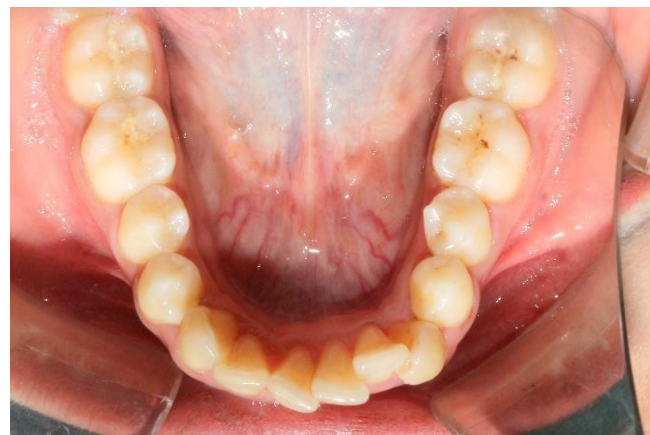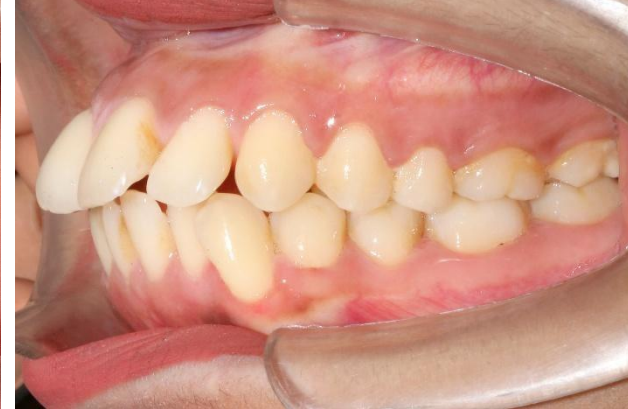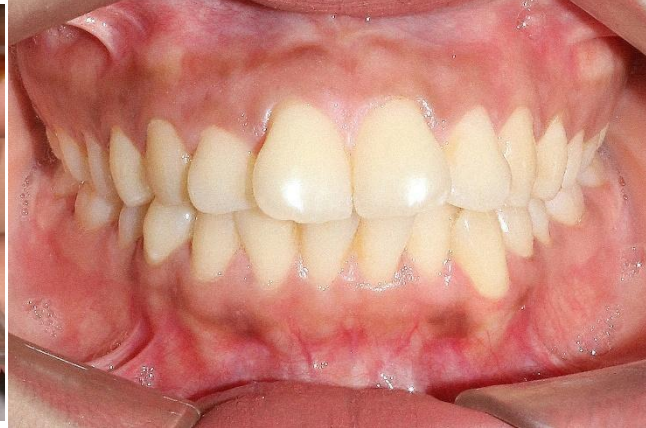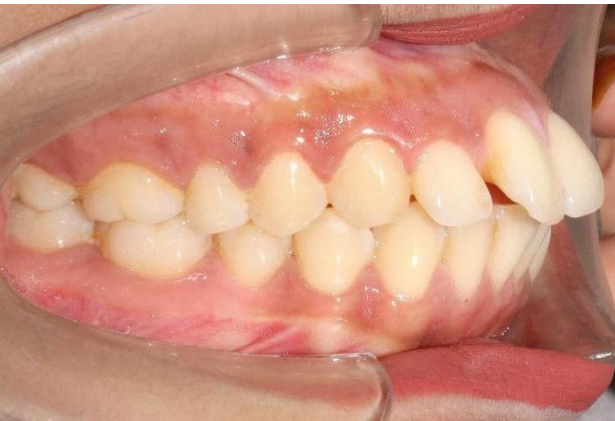**ARSHIYA
20/F**



**PRE TREATMENT
PHOTOS**

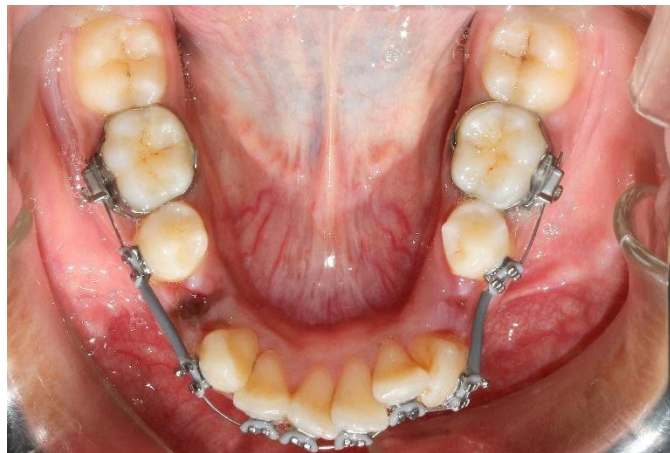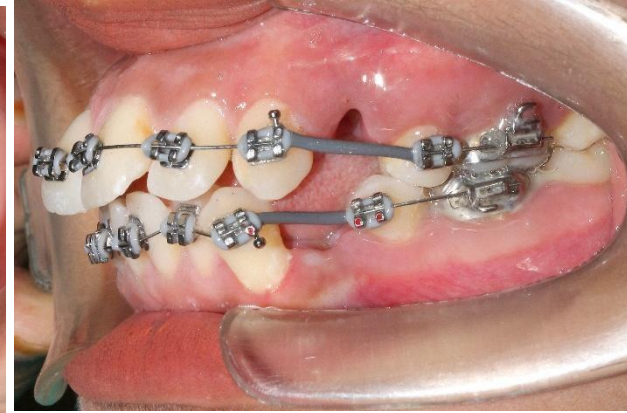
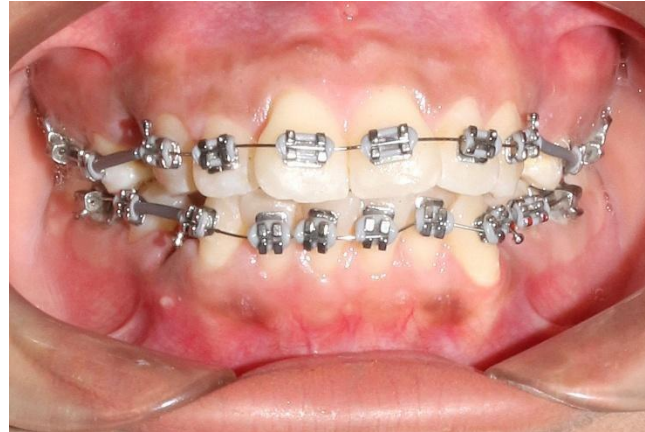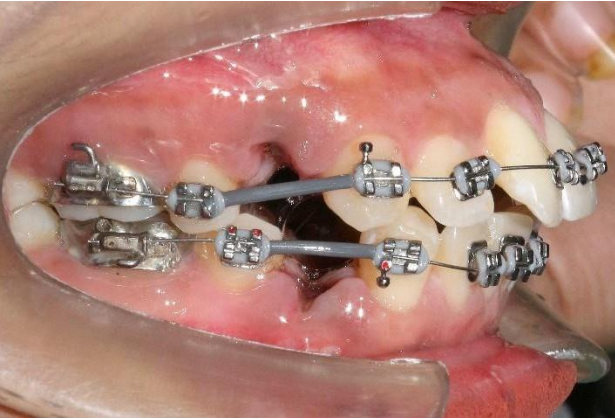
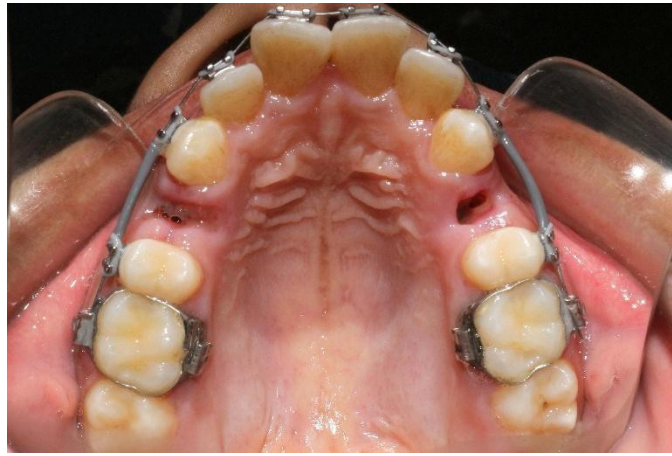


ARSHIYA

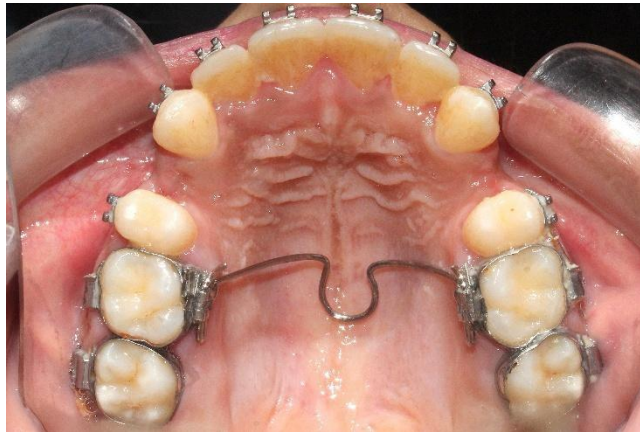


**ALL 4'S EXTRACTION
STRAPUP
PHOTOS**

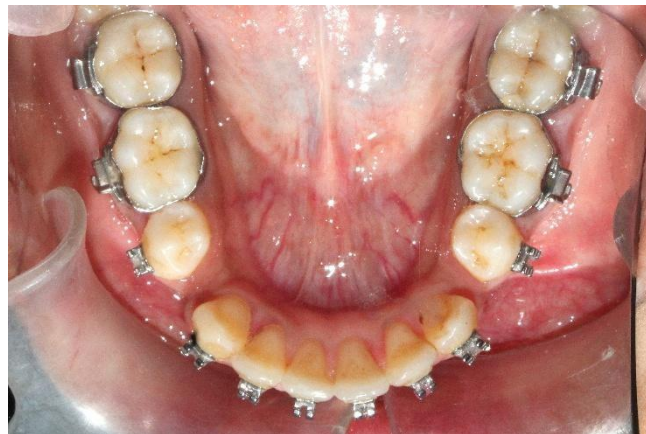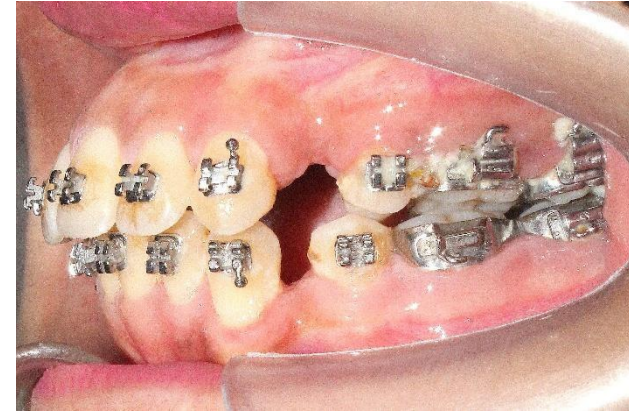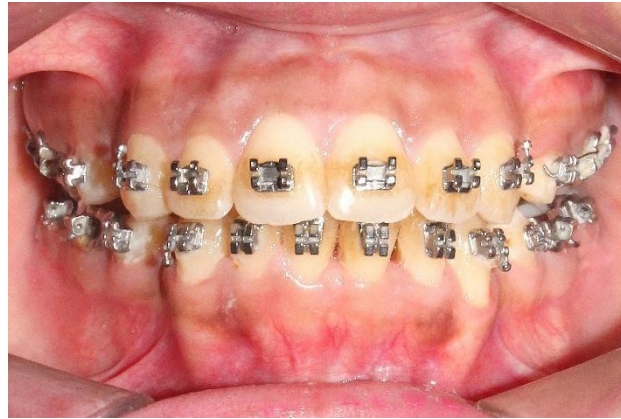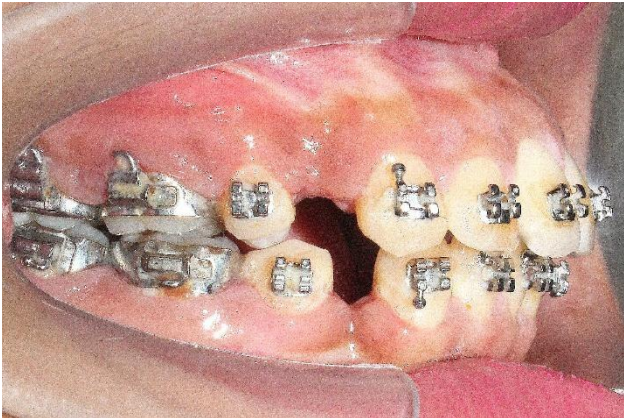ARSHIYA



**PRE RETRACTION
PHOTOS**

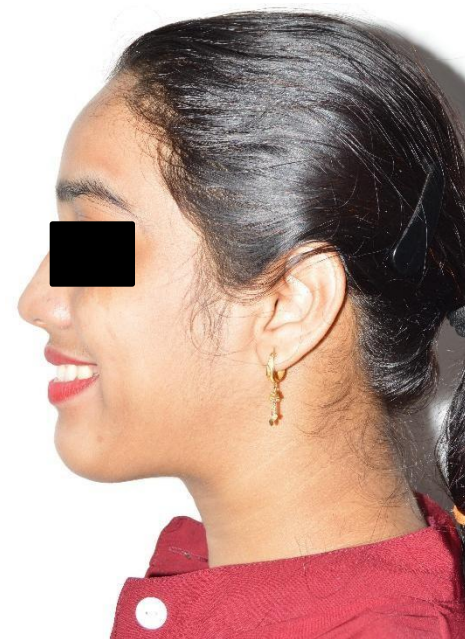
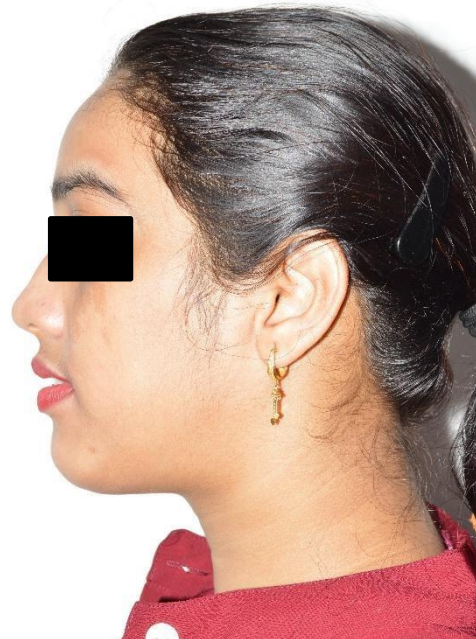
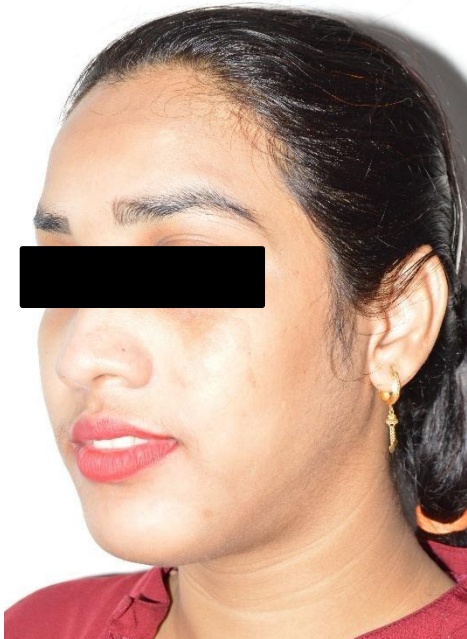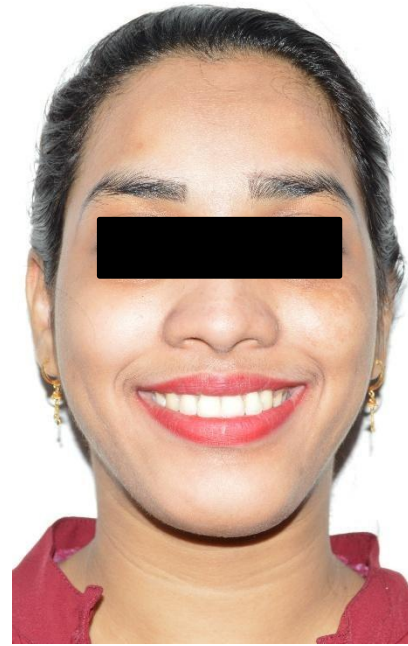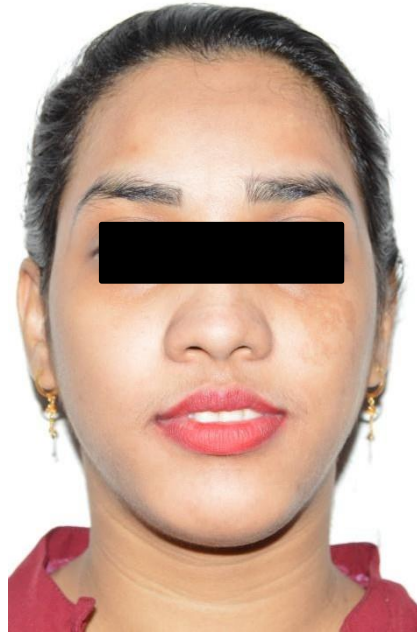ARSHIYA



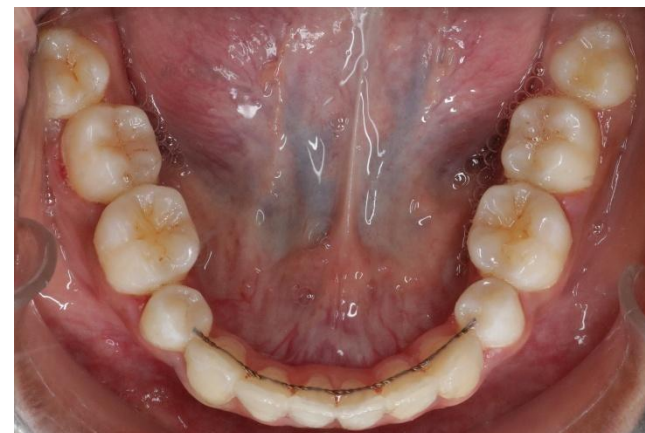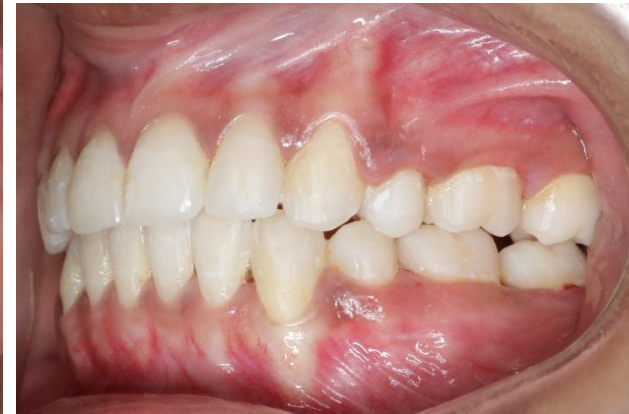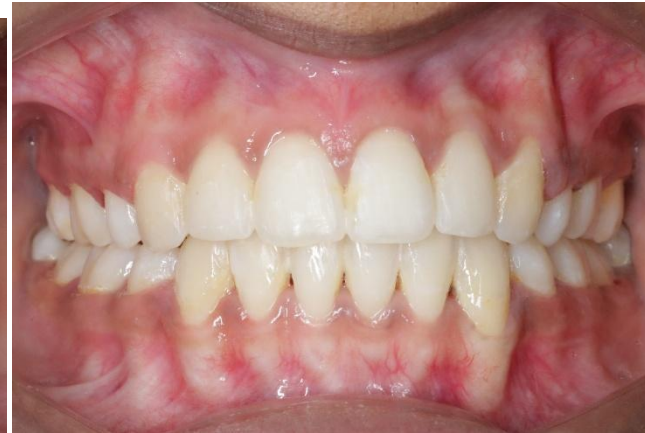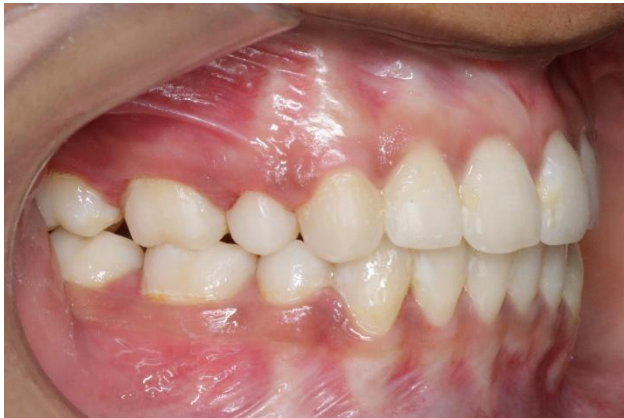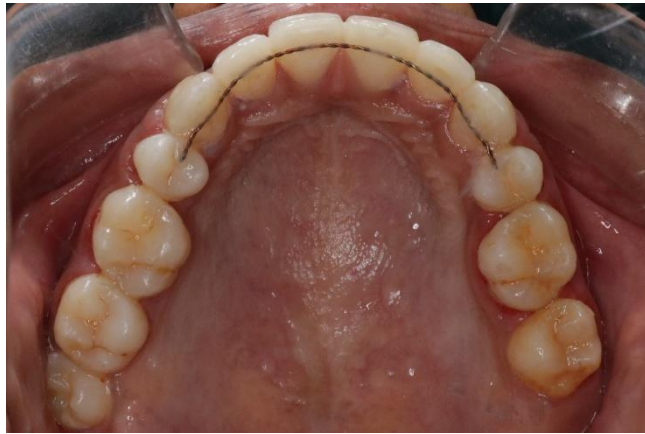**POST DENBOND
PHOTOS**

ARSHIYA



**POST DENBOND
PHOTOS**

ARSHIYA



CASE III:

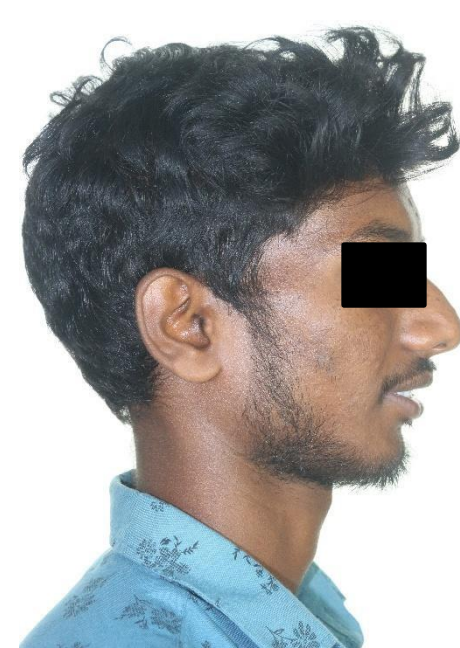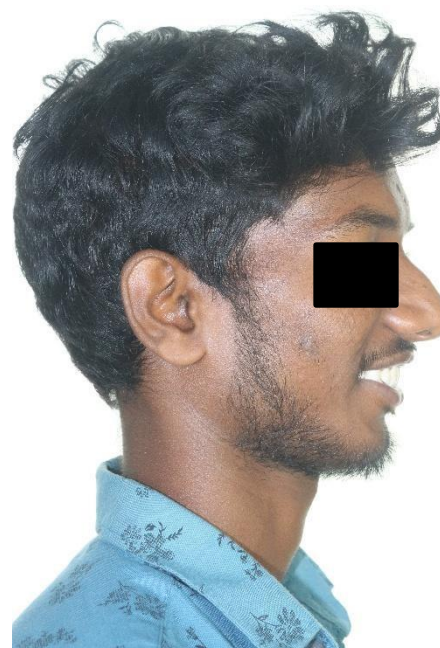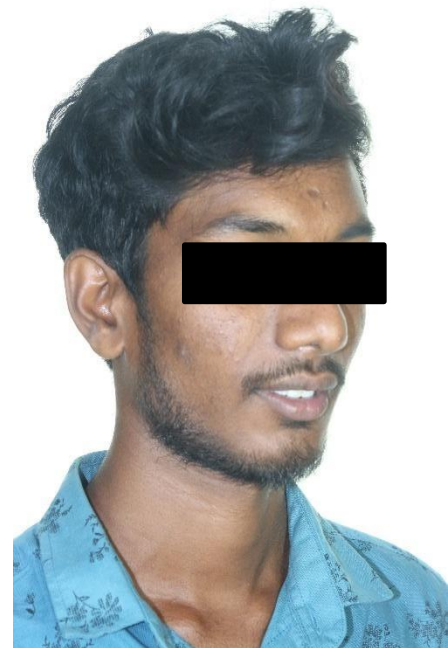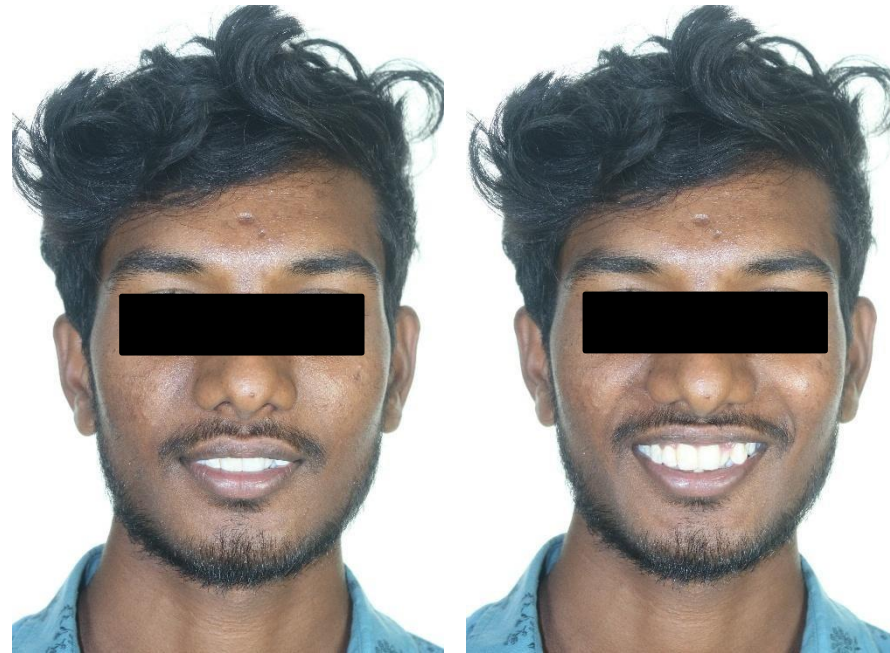NAME: SHASHIKANTH ; AGE: 23YEARS/MALE; OPNO: 202107050010

DIAGNOSIS: ANGLES CLASS I MALOCLLUSION WITH CROWDING

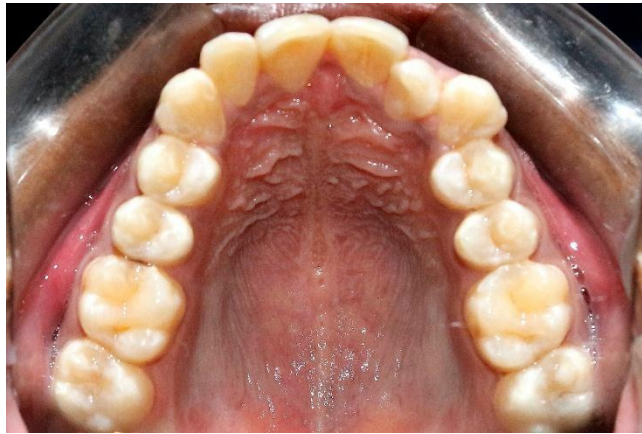**TREATMENT PLAN : ALL FOUR 1ST PREMOLAR EXTRACTIONS WITH
UPPER ANTERIORS INTRUSION**

**PRE TREATMENT
PHOTOS**

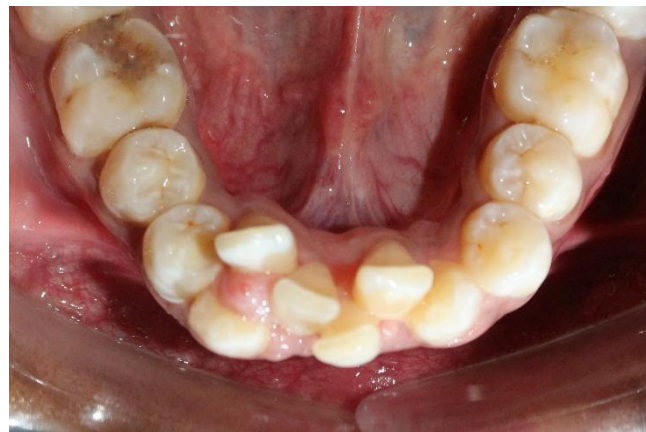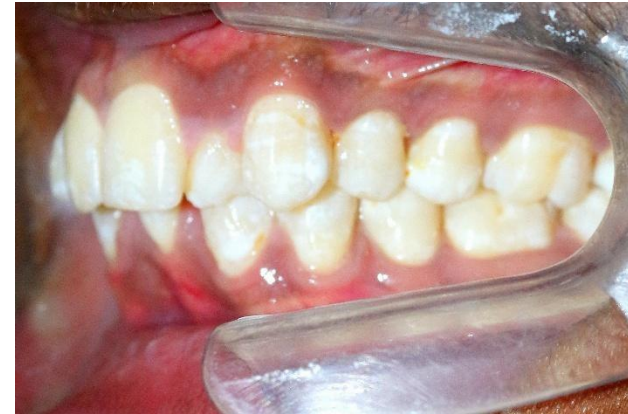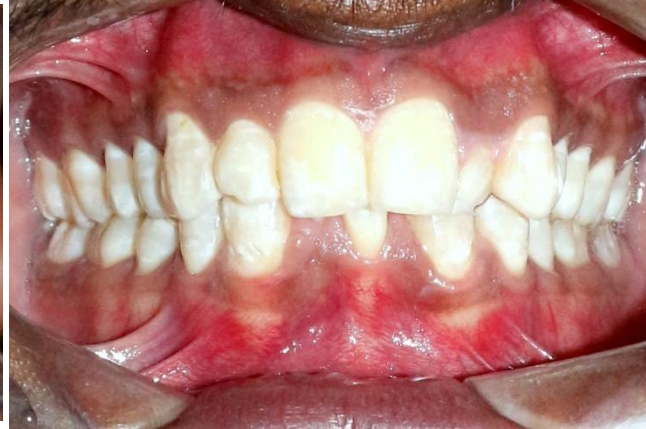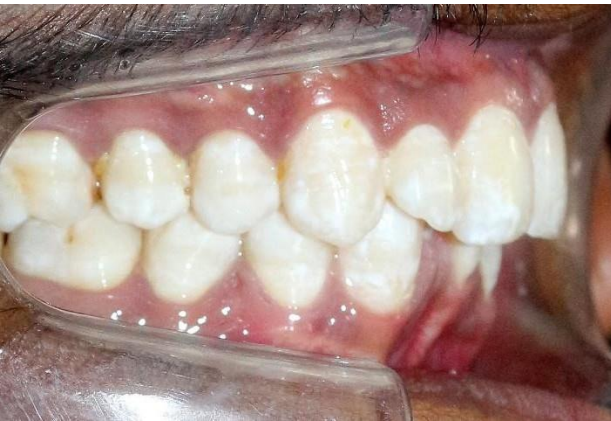**SHASHIKANTH
23/M**



**PRE TREATMENT
PHOTOS**

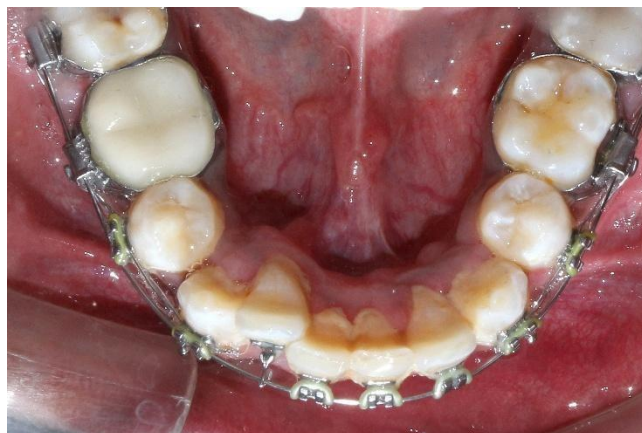
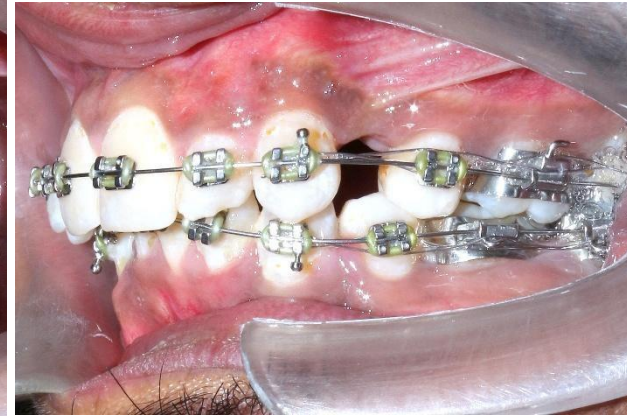
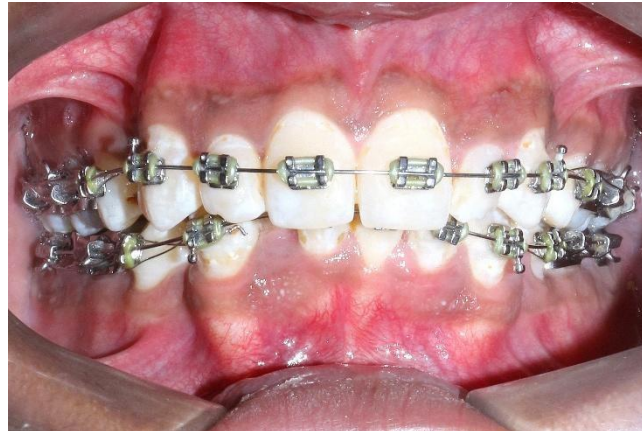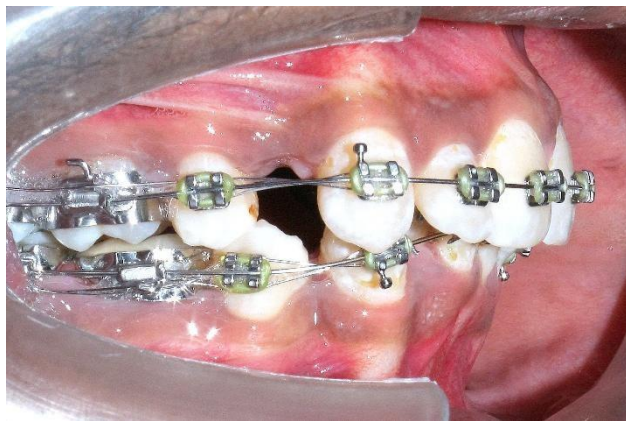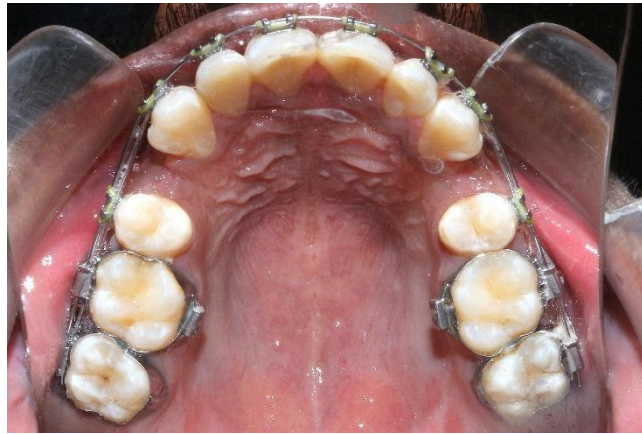SHASHIKANTH



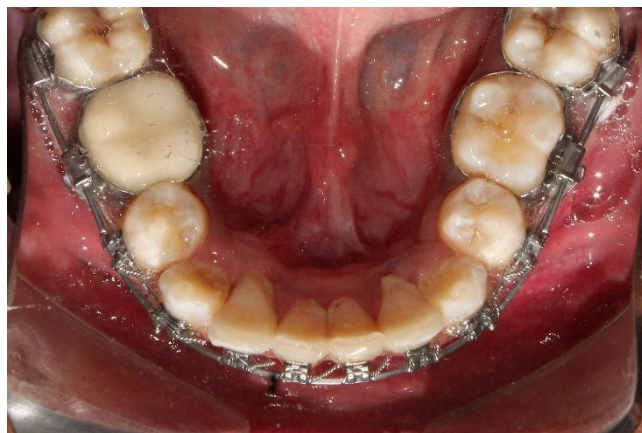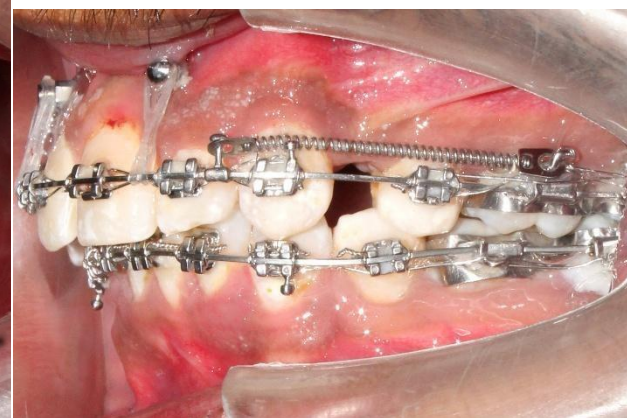
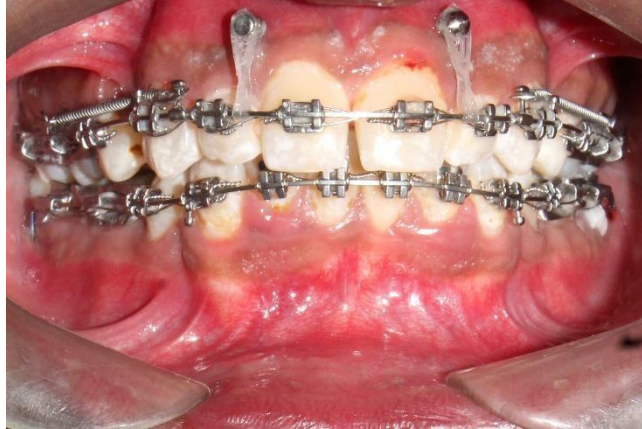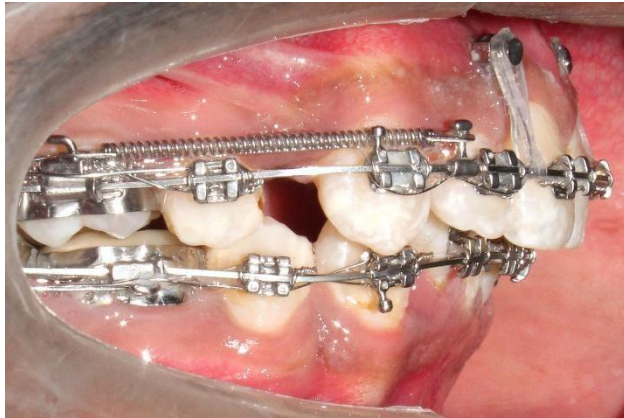
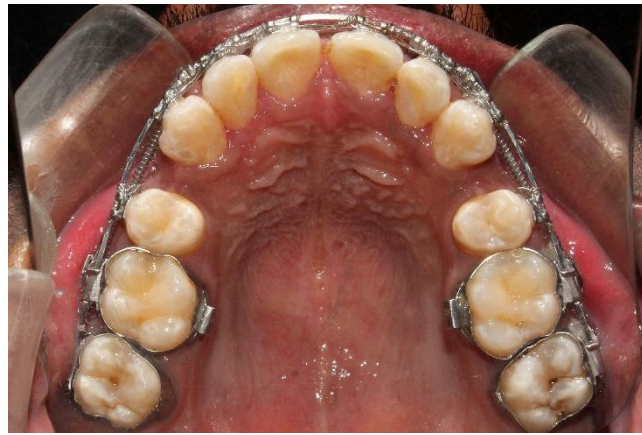**ALL 4'S EXTRACTION
STRAPUP
PHOTOS**

SHASHIKANTH



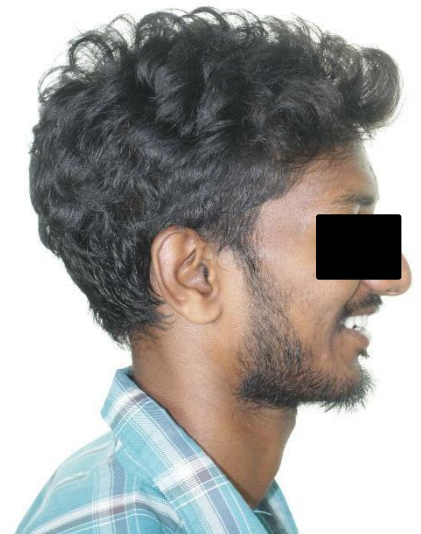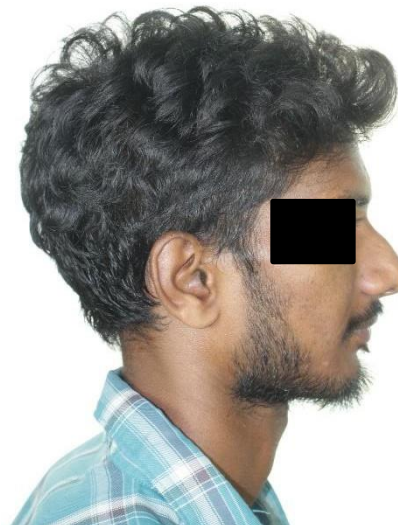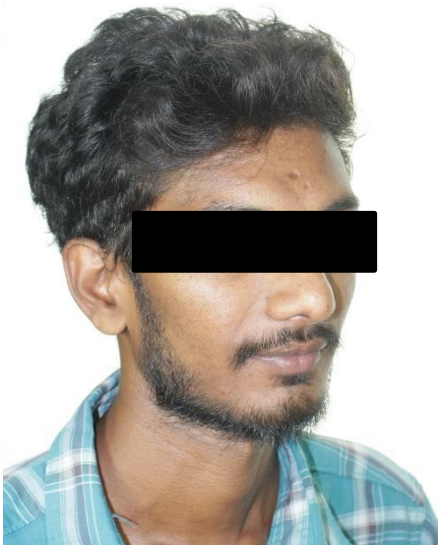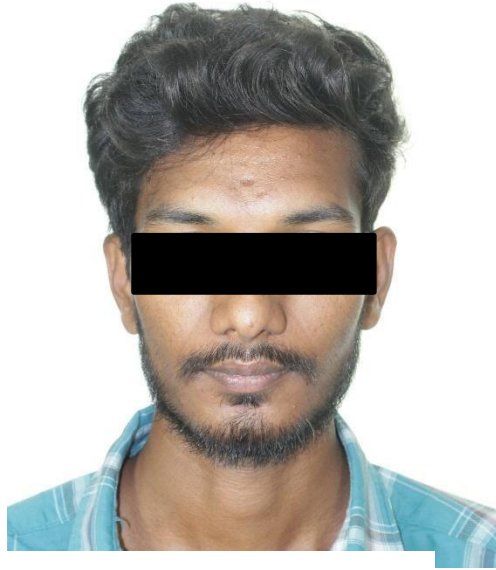**SPACE CLOSURE
PHOTOS**

SHASHIKANTH



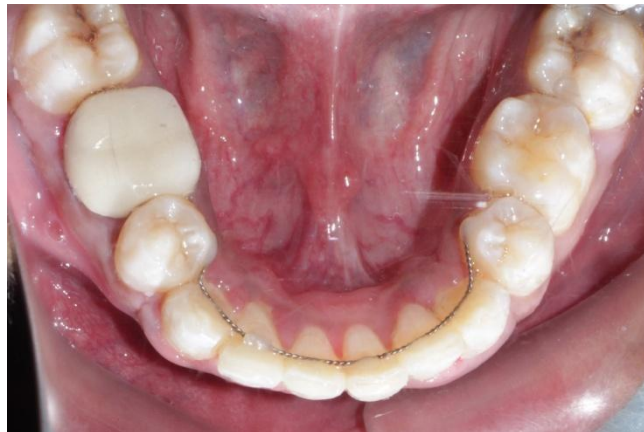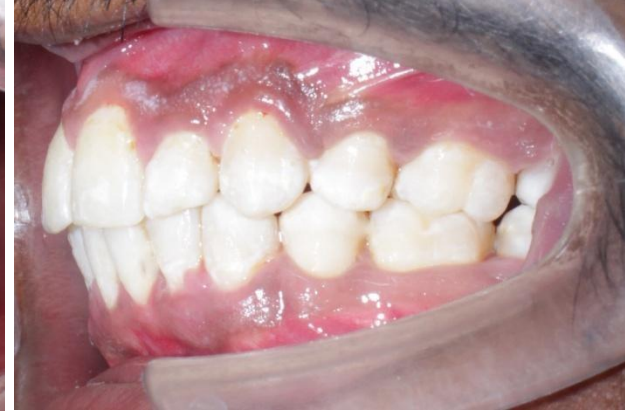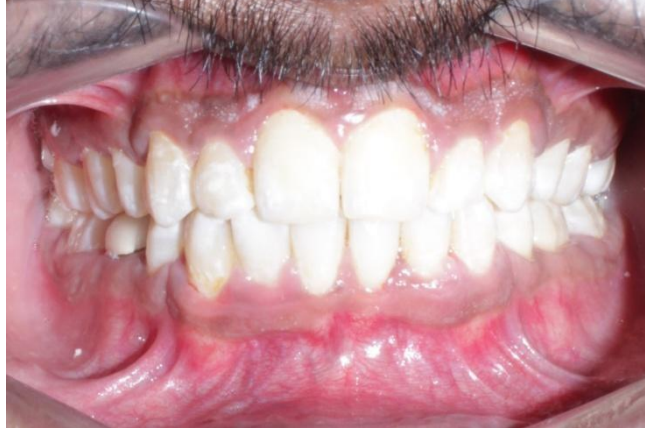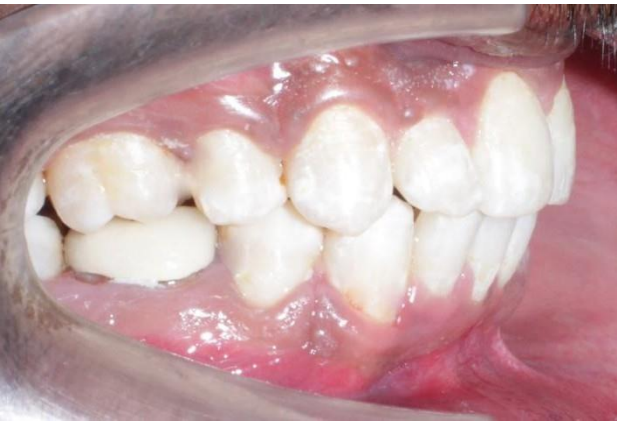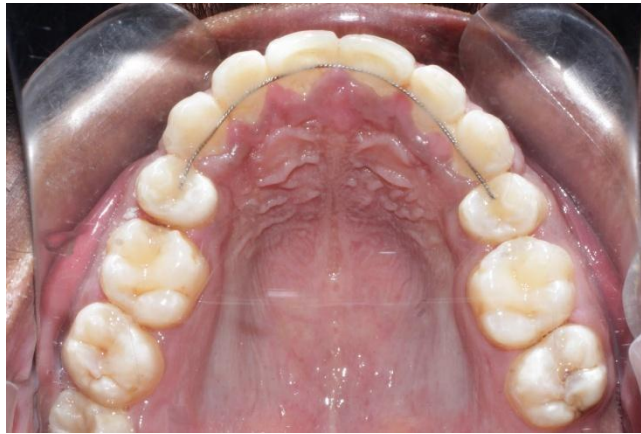**POST DENBOND
PHOTOS**

shashikanth



**POST DENBOND
PHOTOS**

shashikanth



CASE IV:

NAME: SIRI MAHALAKSHMI ; AGE: 23YEARS/FEMALE; OPNO:

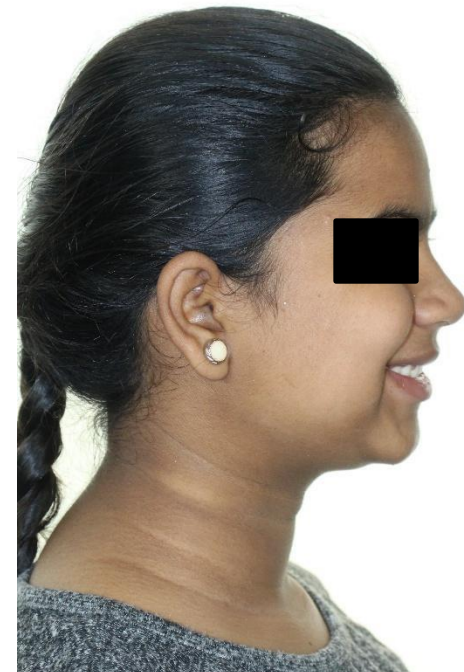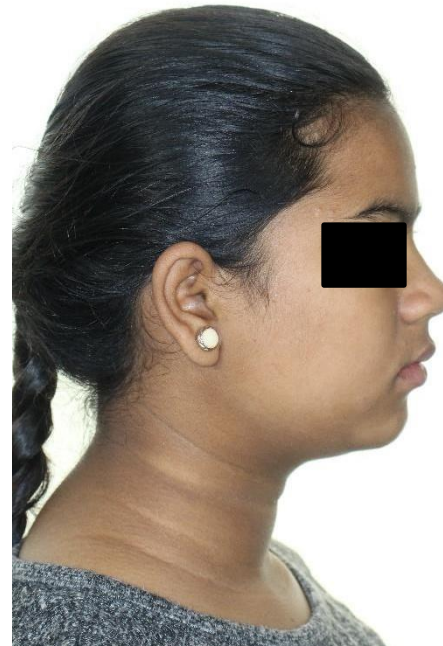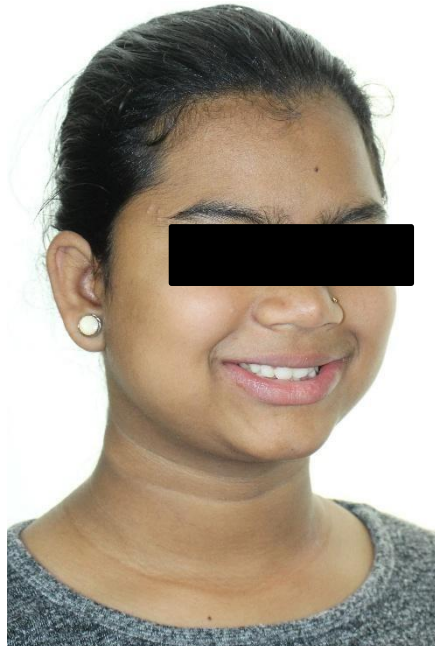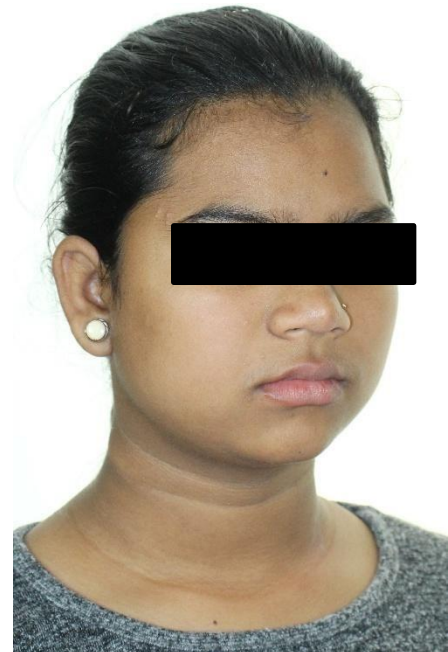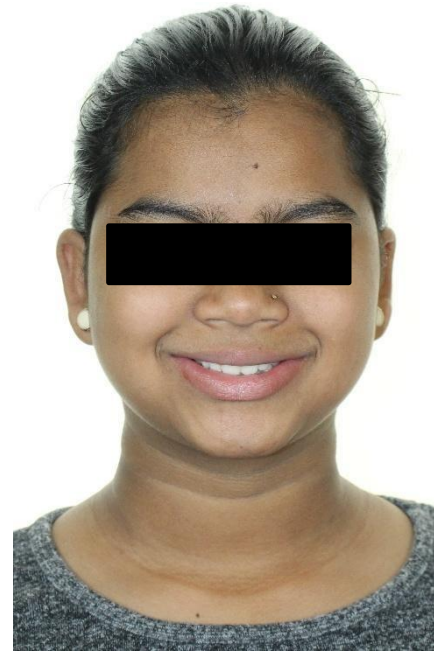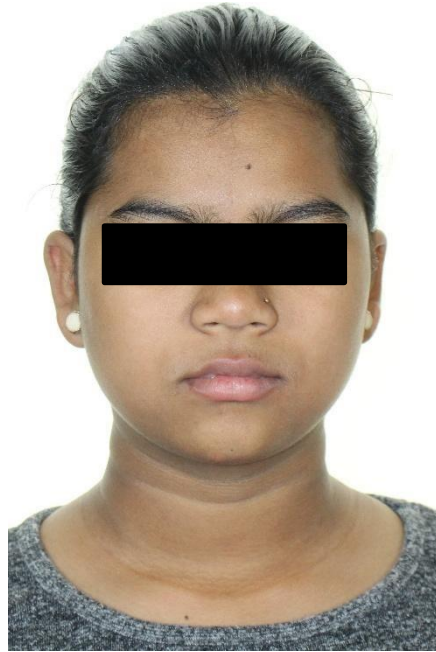202107050010

**DIAGNOSIS: ANGLES CLASS I MALOCLLUSION WITH BILATERAL
IMPACTED CANINES**

TREATMENT PLAN : NON EXTRACTION TREATMENT PLAN

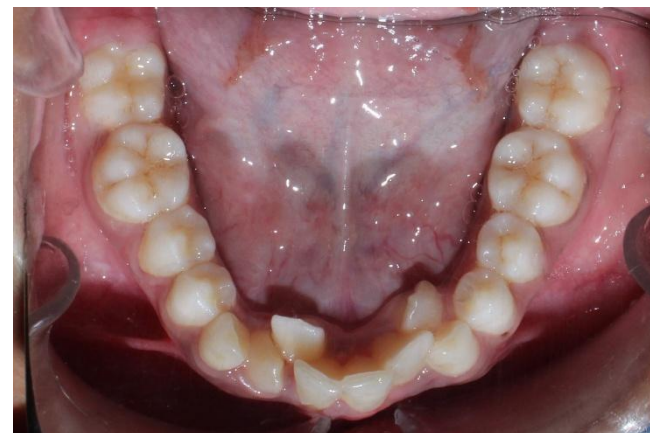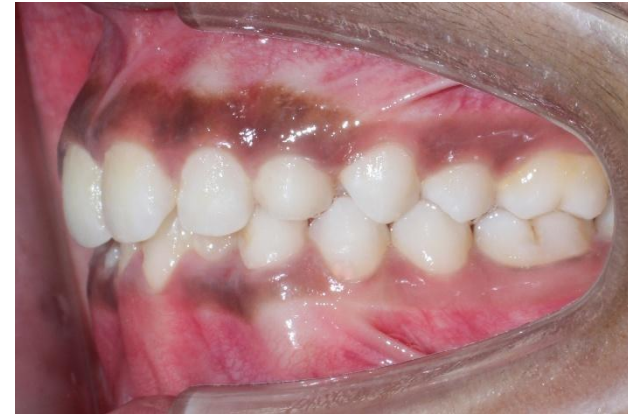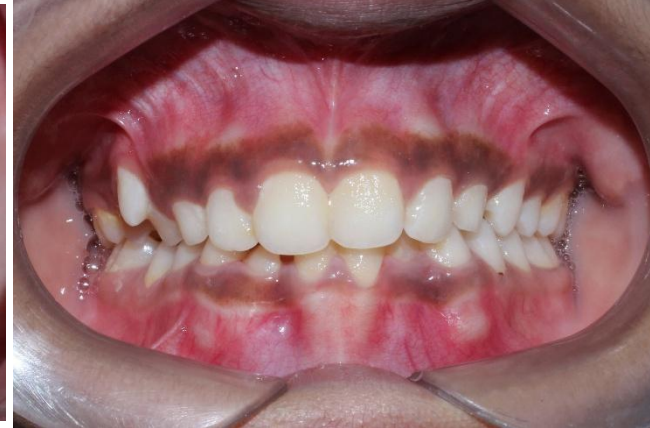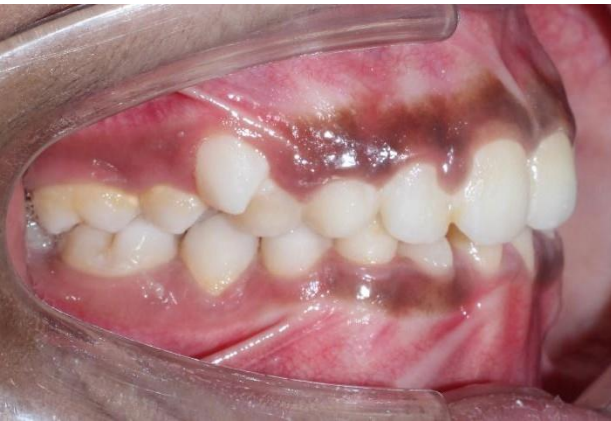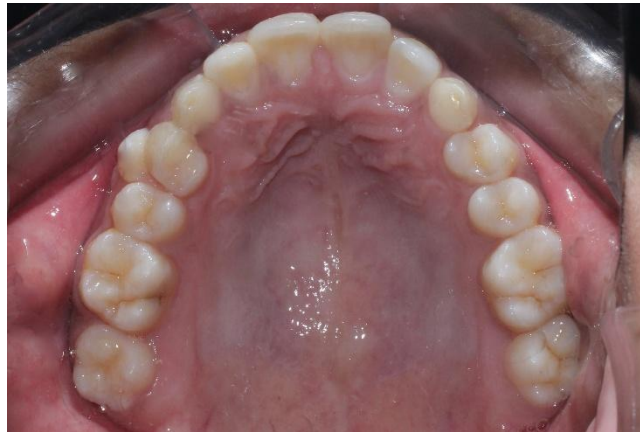**PRE TREATMENT
PHOTOS**

siri mahalakshmi



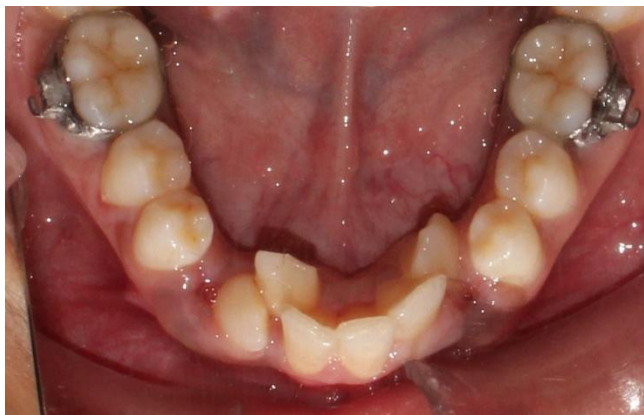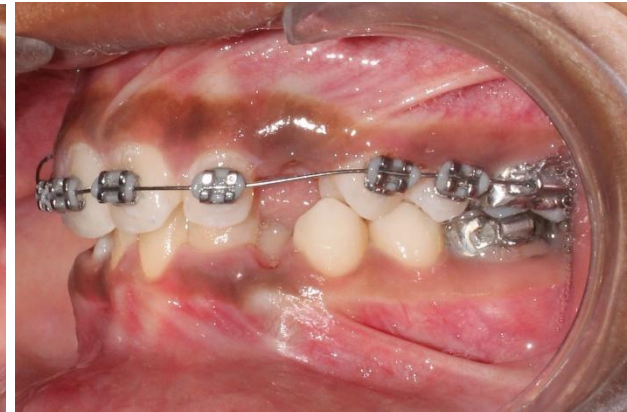
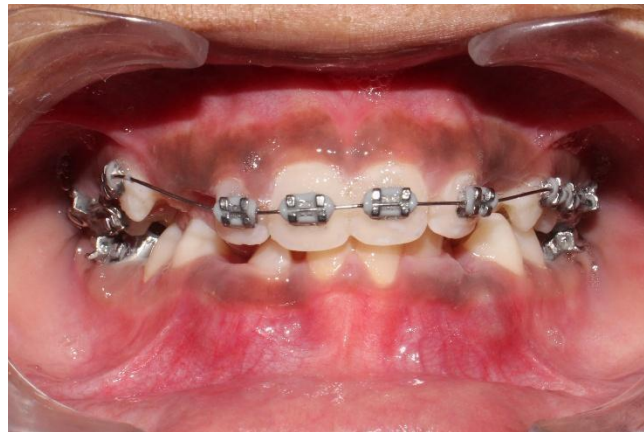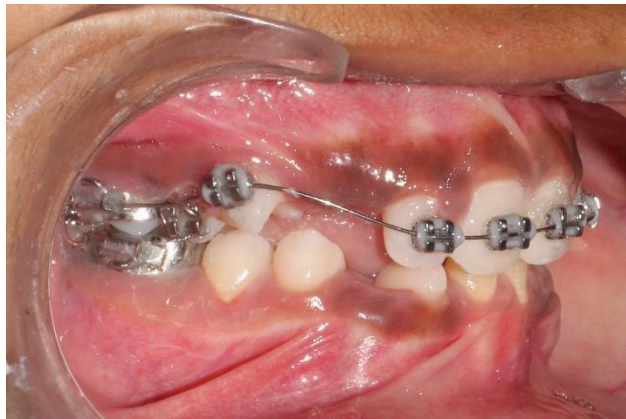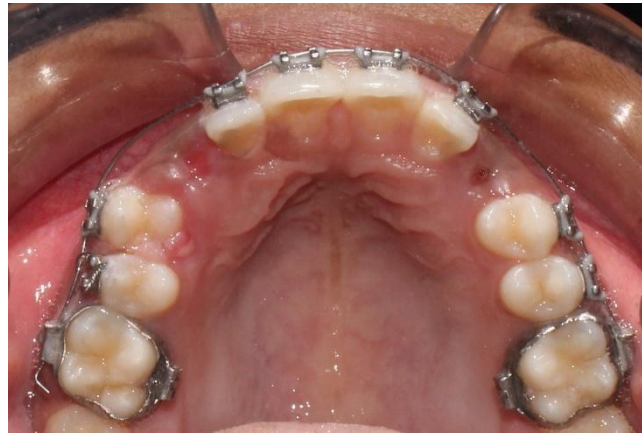**PRE TREATMENT
PHOTOS**

siri mahalakshmi



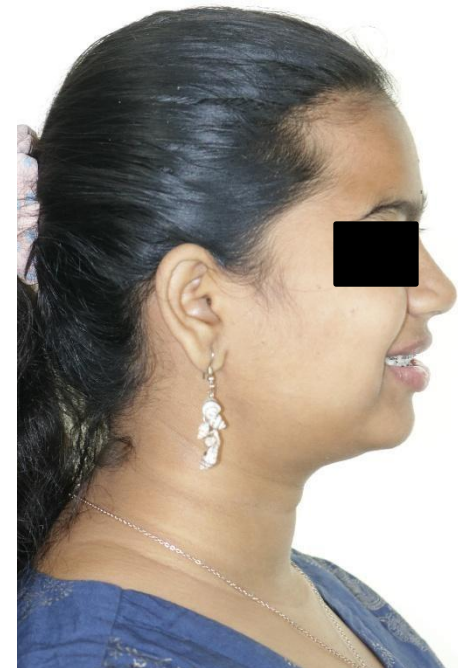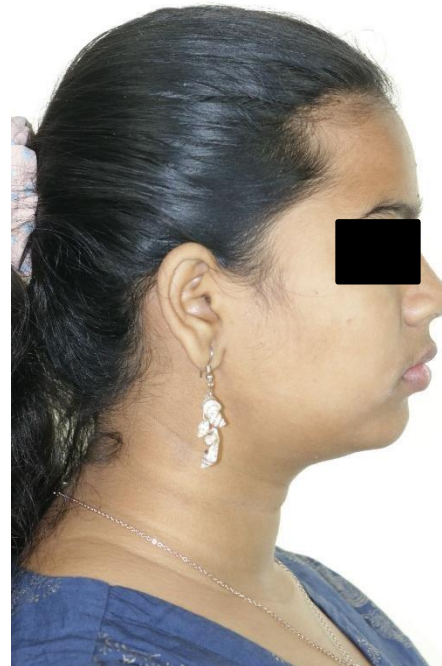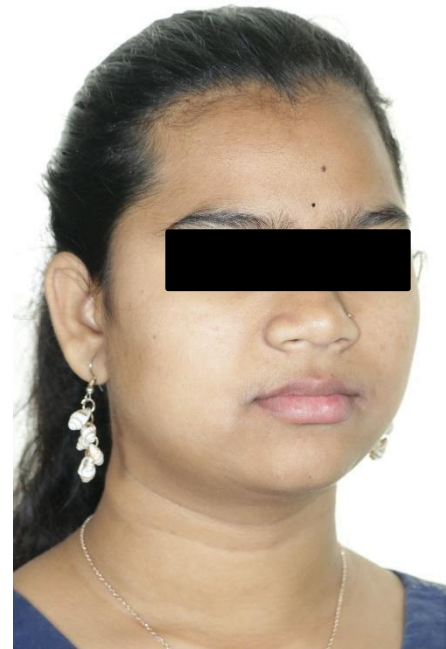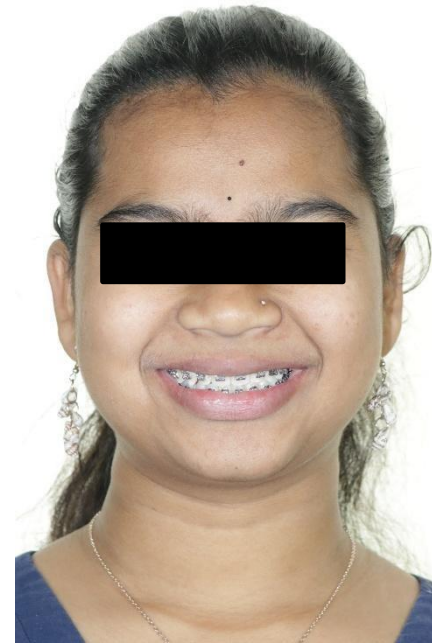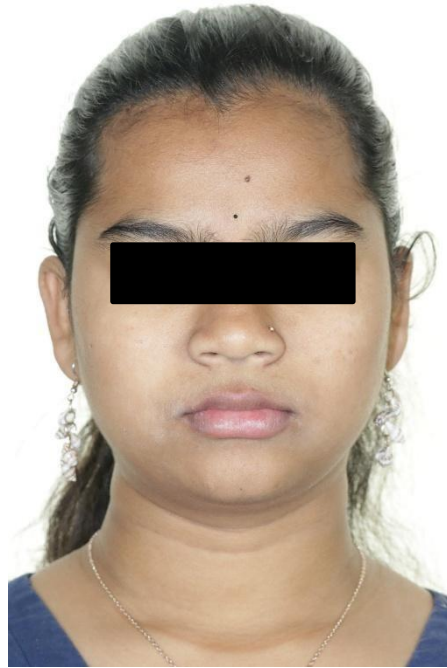**IMPACTED CANINES
STRAPUP
PHOTOS**

SIRI MAHALAKSHMI



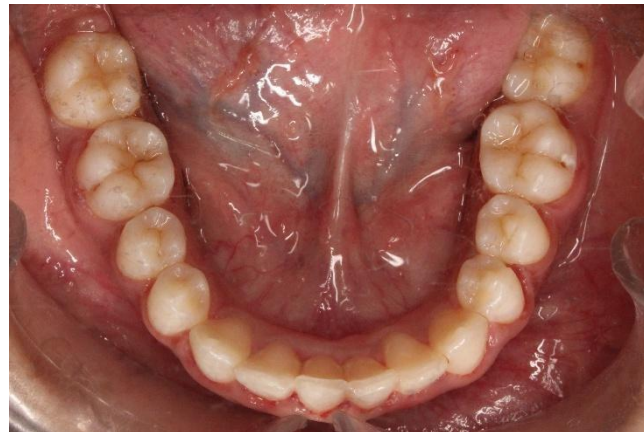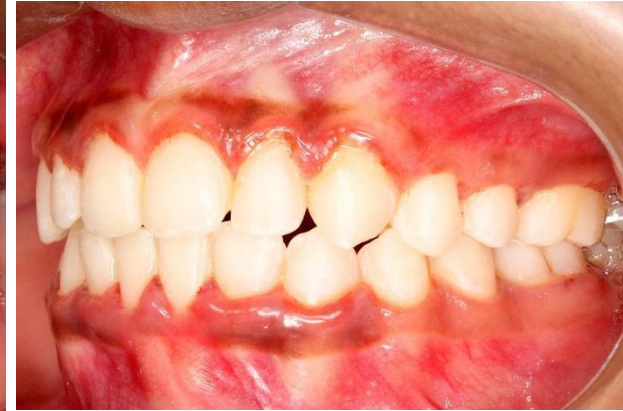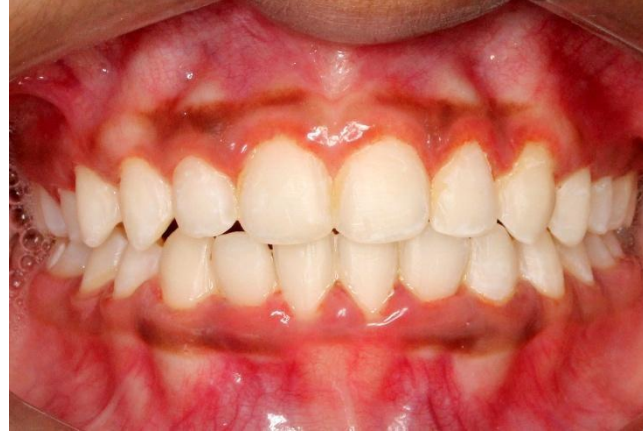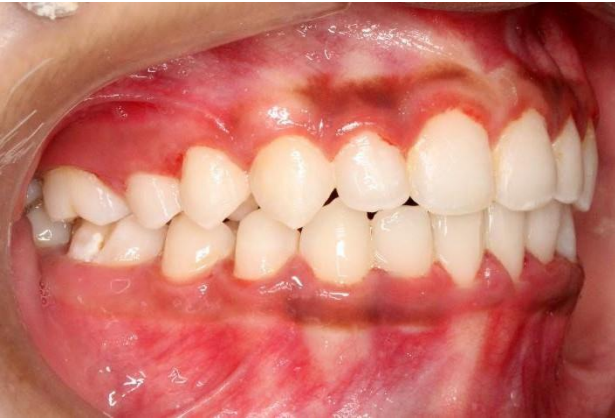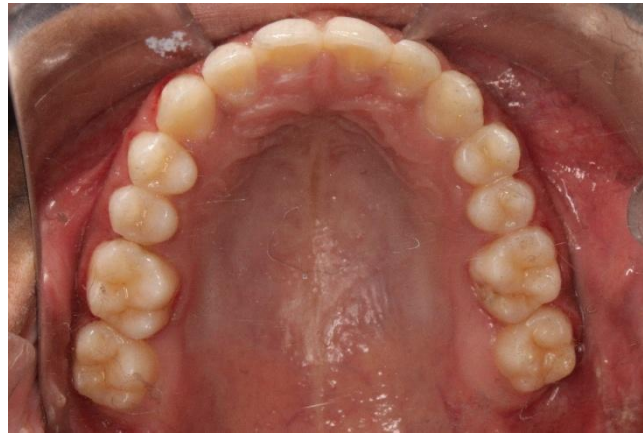
**POST DENBOND
PHOTOS**

SIRI MAHALAKHSMI



**POST DENBOND
PHOTOS**

SIRI MAHLAKSHMI



CASE V:

NAME: TANVEER BANU; AGE: 21YEARS/FEMALE; OPNO: 202409090002

**DIAGNOSIS: ANGLES CLASS II DIVISION 1 MALOCLLUSION WITH
RETROGNATHIC MANDIBLE**

**TREATMENT PLAN : NON EXTRACTION TREATMENT PLAN + BSSO
ADVANCEMENT**

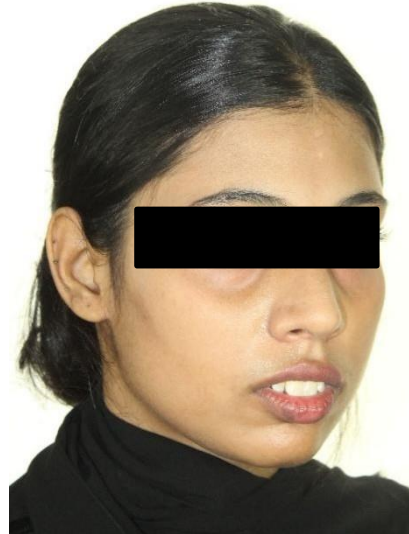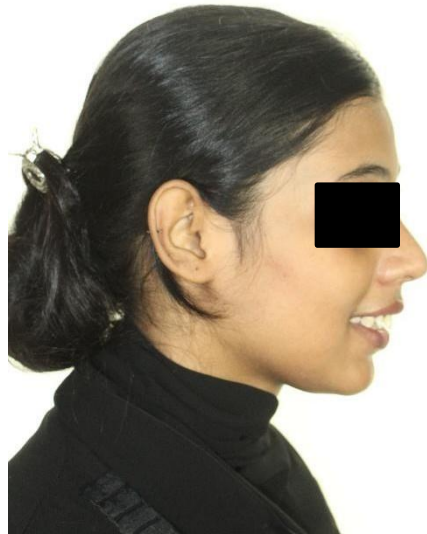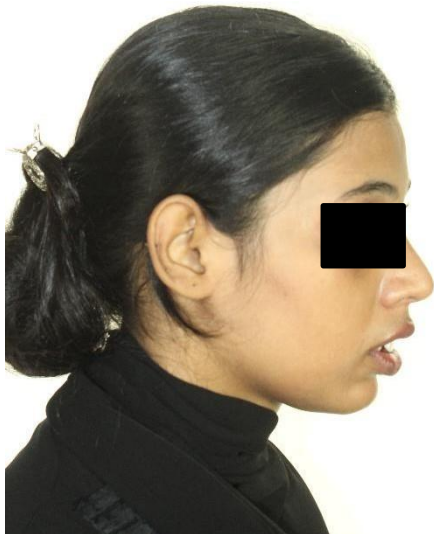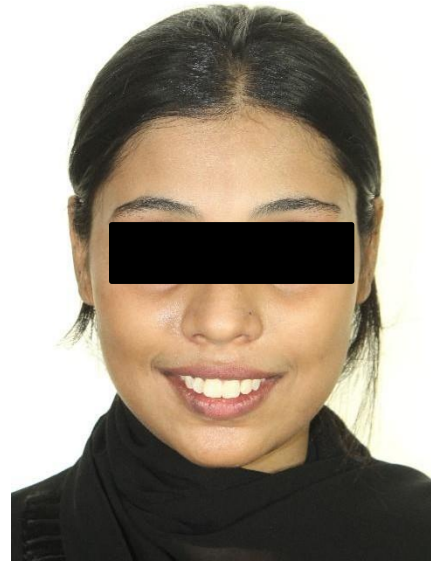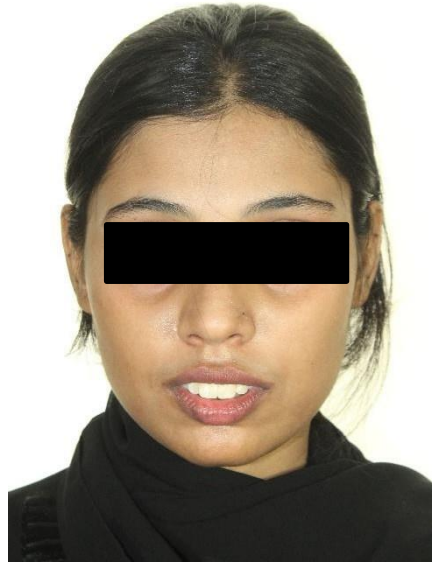EXTRA ORAL

**PRE TREATMENT
PHOTOS**

NAME : TANVEER BANU

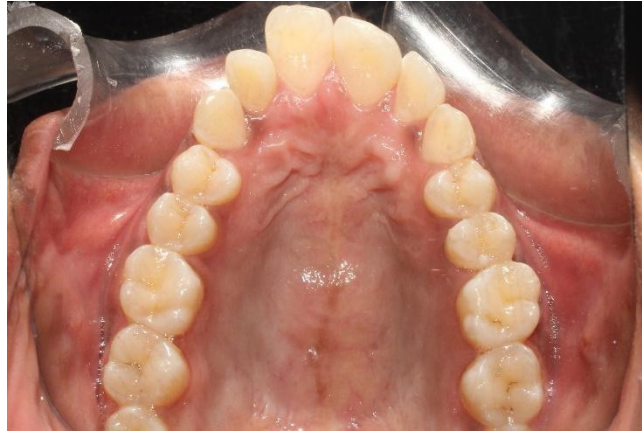AGE / SEX: 21 / F

OP NO: : 202409090002



INTRA ORAL

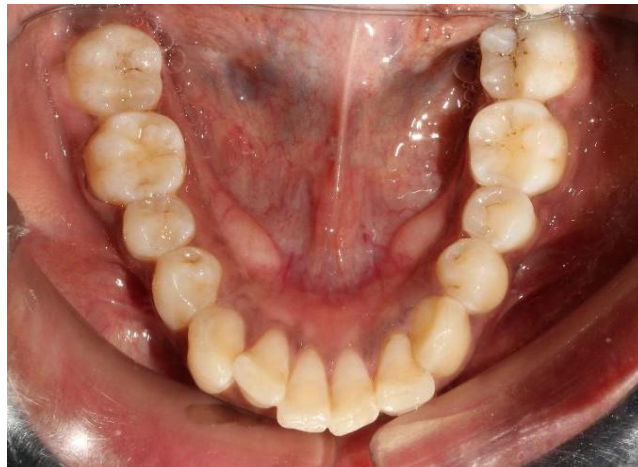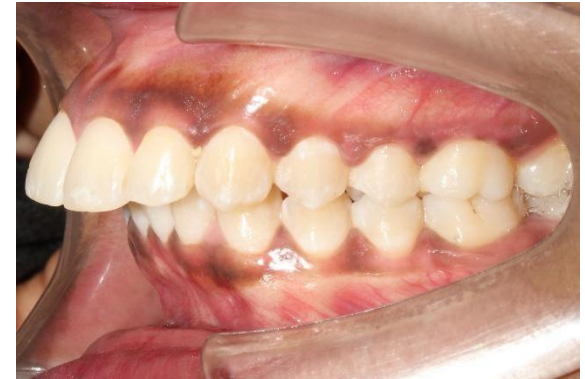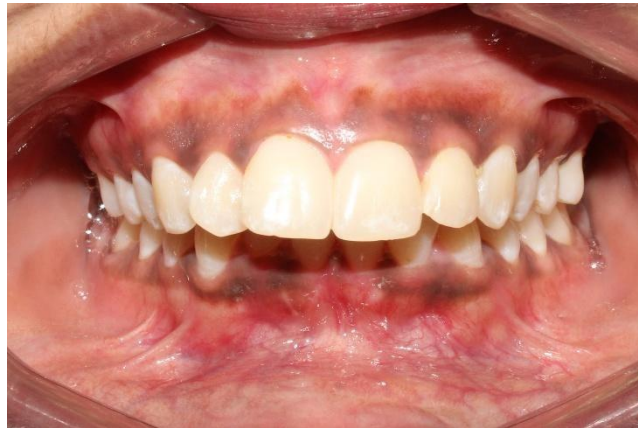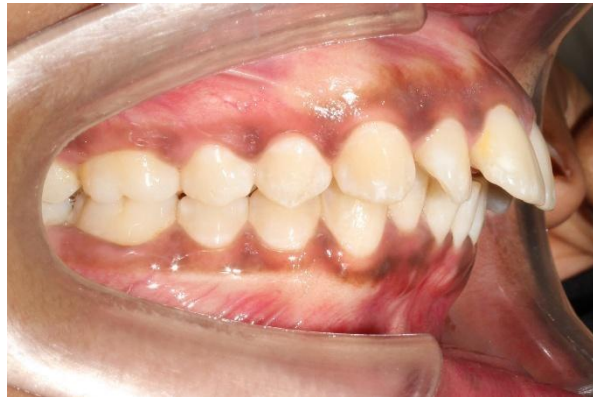**PRE TREATMENT
PHOTOS**



NAME : TANVEER BANU

AGE / SEX: 21 / F

OP NO: : : 202409090002



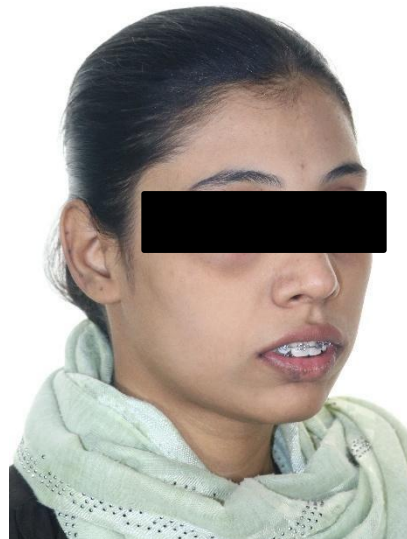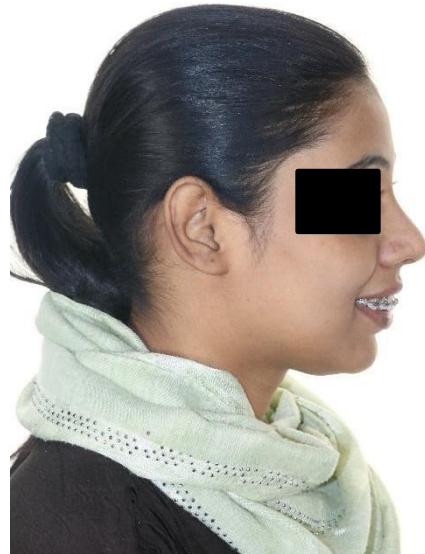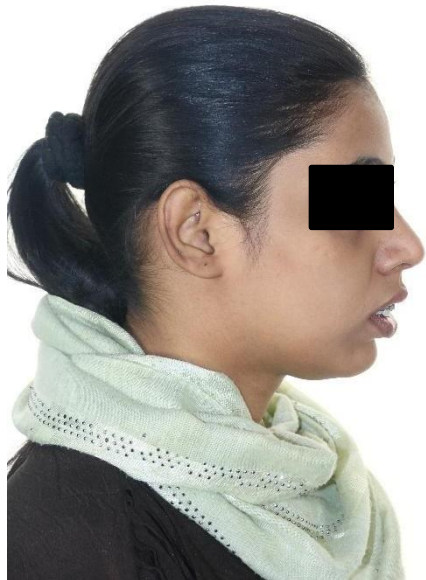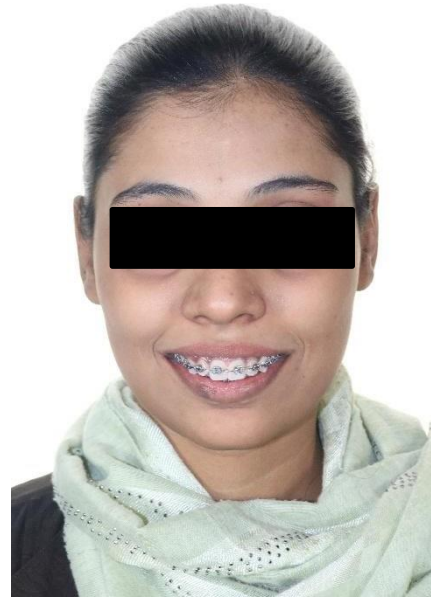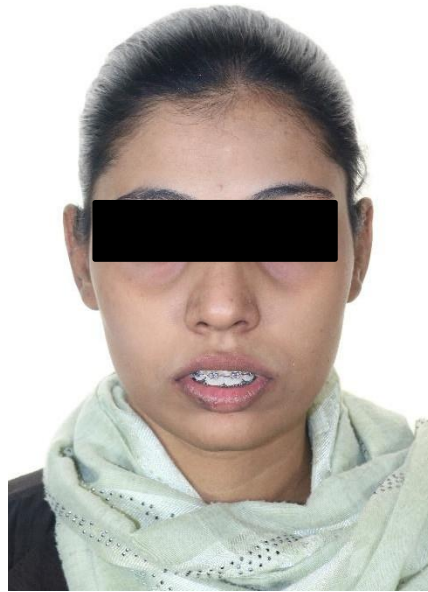INTRA ORAL

**PRE SURGICALS
PHOTOS**

NAME : TANVEER BANU

AGE / SEX: 21 / F

OP NO: : 202409090002



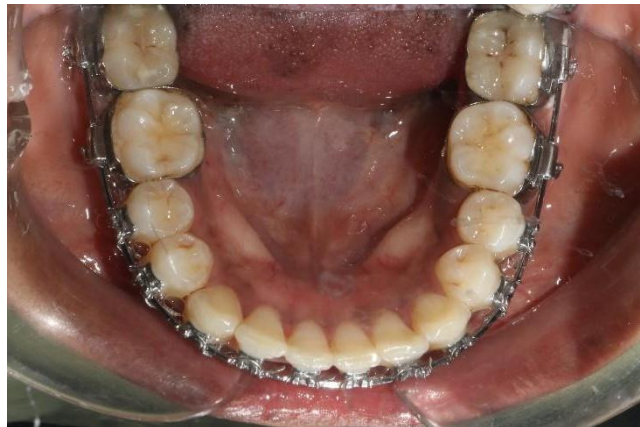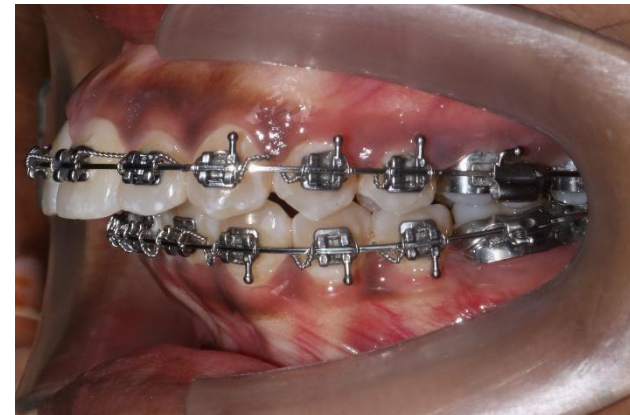
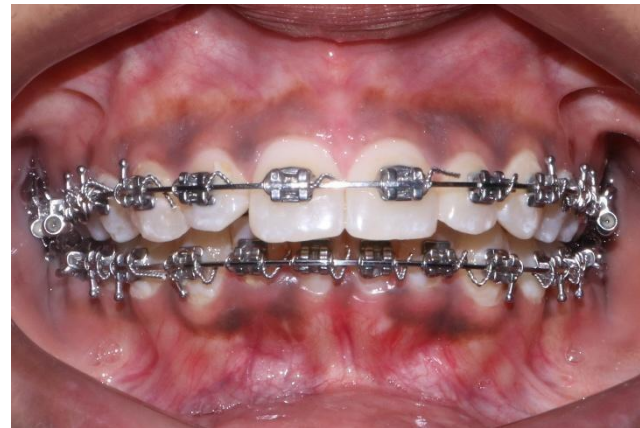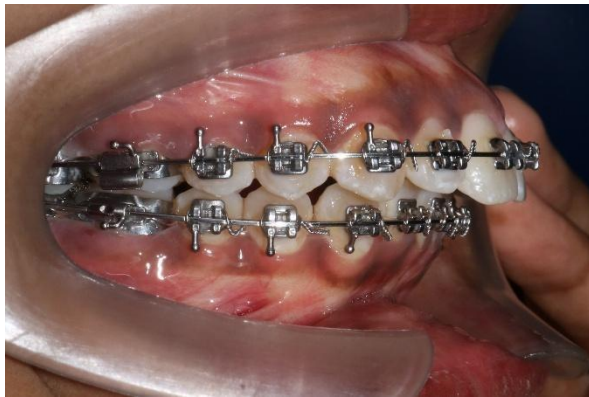
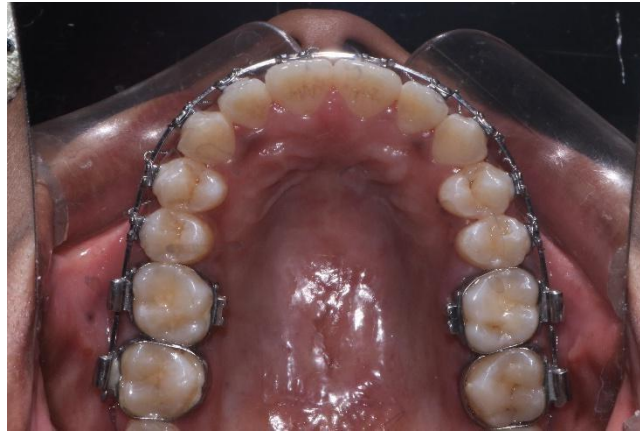INTRA ORAL

**PRE SURGICALS
PHOTOS**

NAME : TANVEER BANU

AGE / SEX: 21 / F

OP NO: : 202409090002

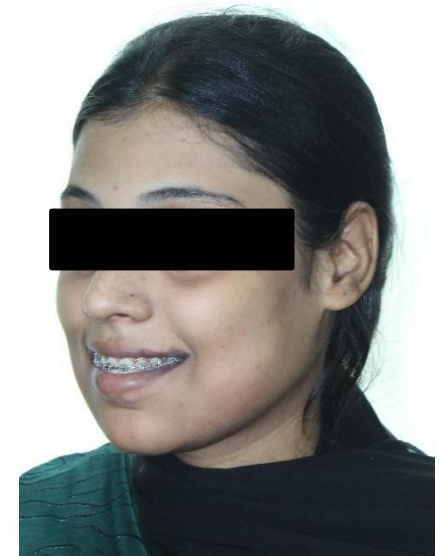
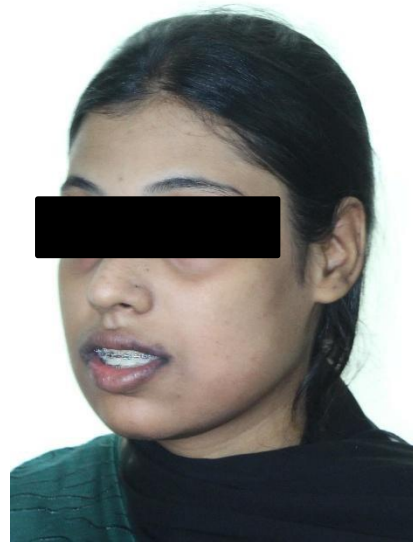
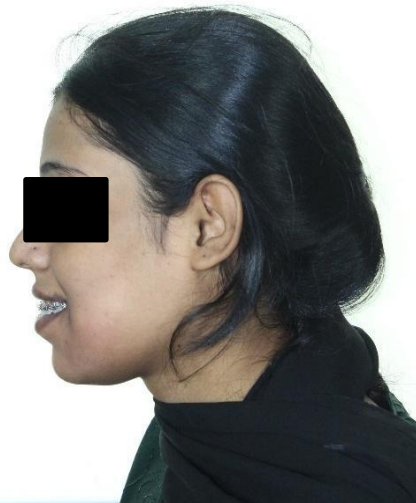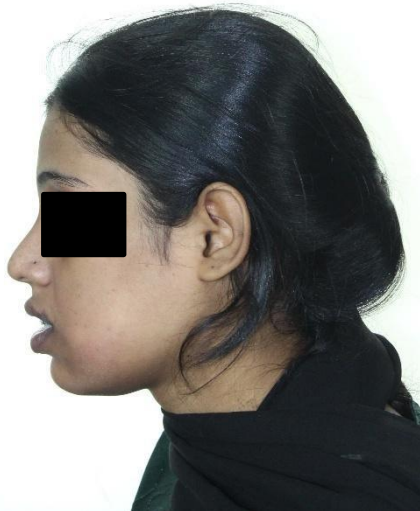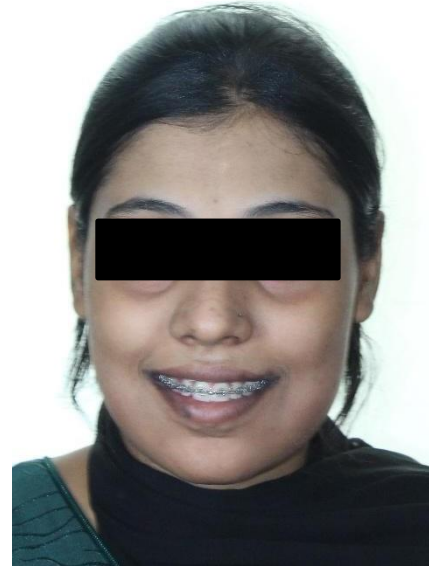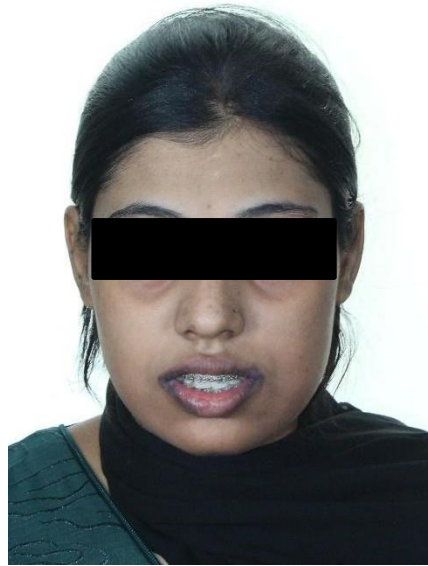EXTRA ORAL
BSSO
ADVANCEMENT
POST SURGICAL
PHOTOS

NAME : TANVEER BANU

AGE / SEX: 21 / F

OP NO: : 202409090002



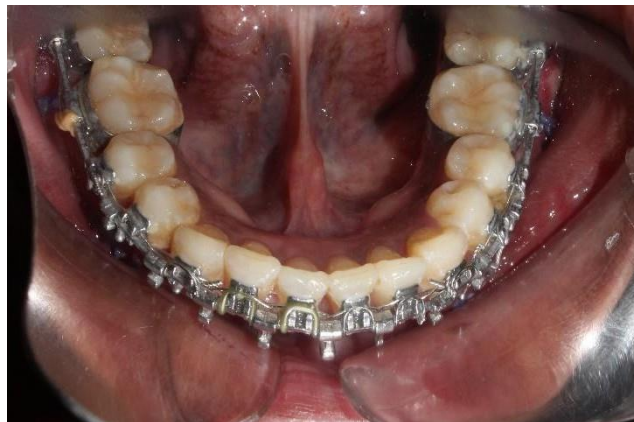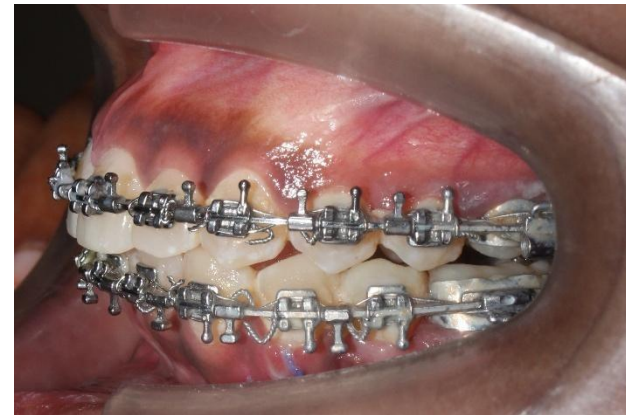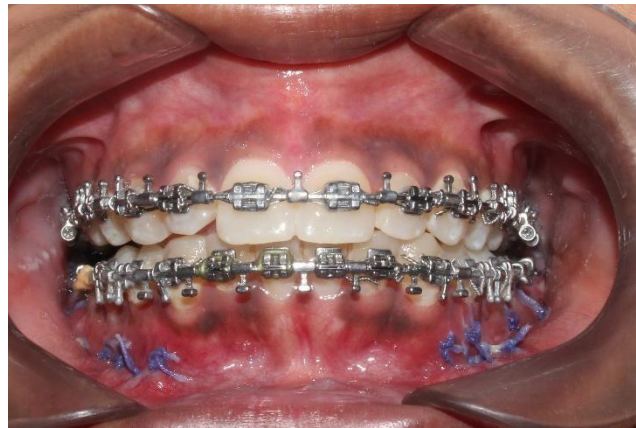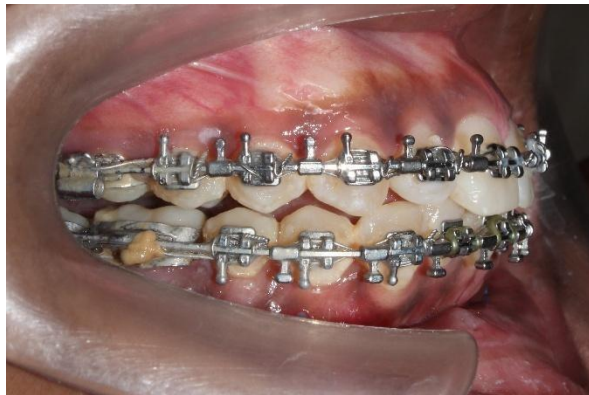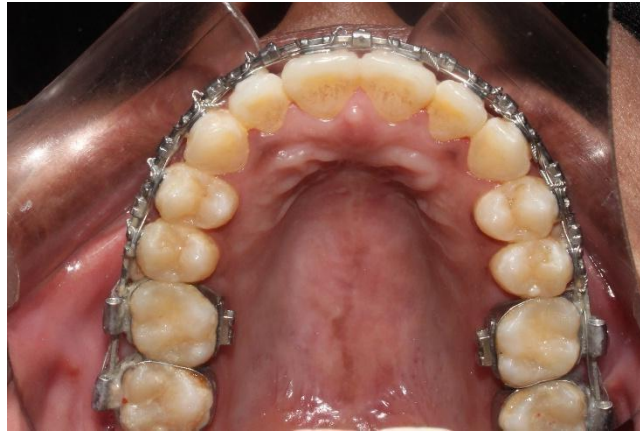INTRA ORAL

**POST SURGICALS
PHOTOS**

NAME : TANVEER BANU

AGE / SEX: 21 / F

OP NO: : : 202409090002



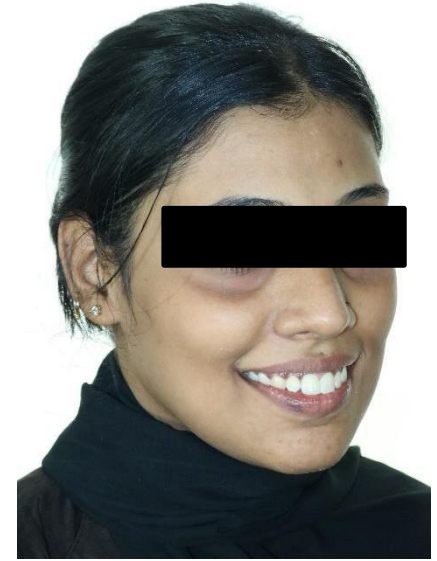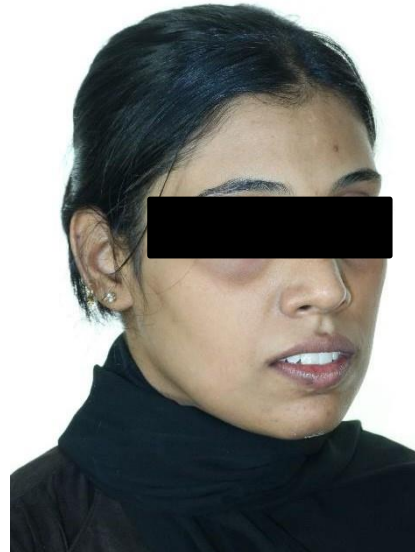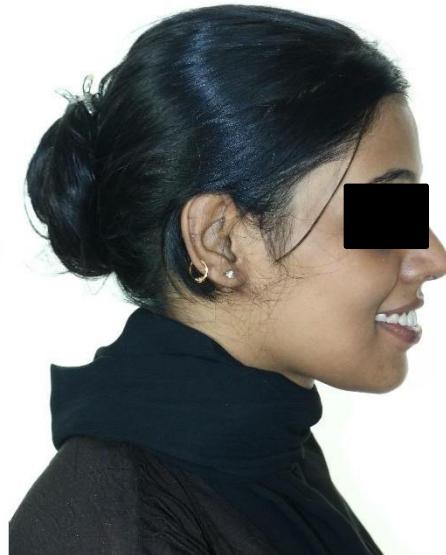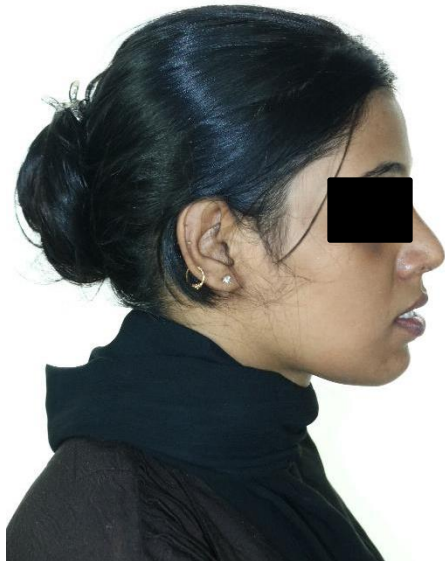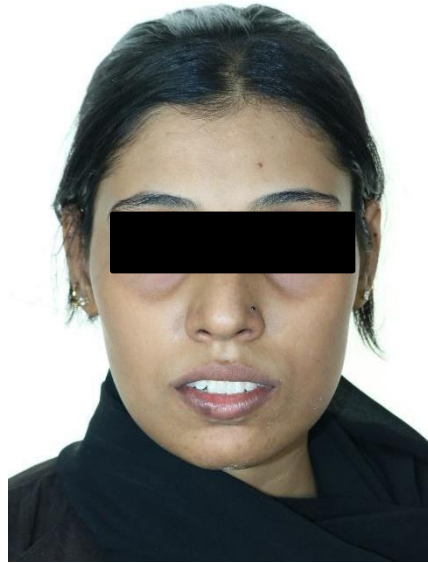EXTRA ORAL

DEBONDED PHOTOS

NAME : TANVEER BANU

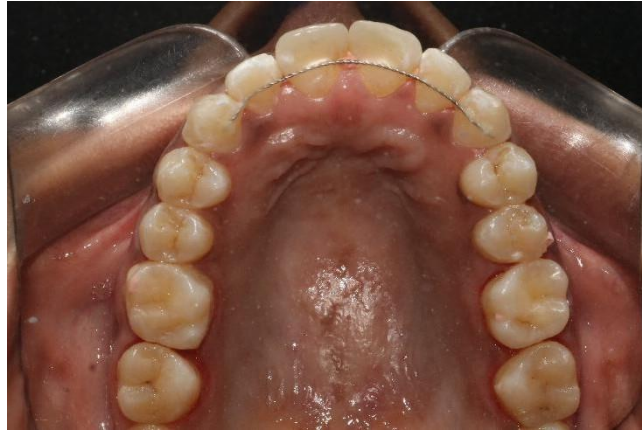AGE / SEX: 21 / F

OP NO: : 202409090002



INTRA ORAL

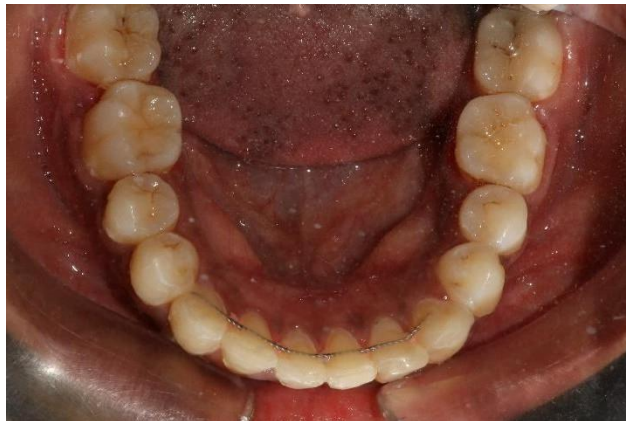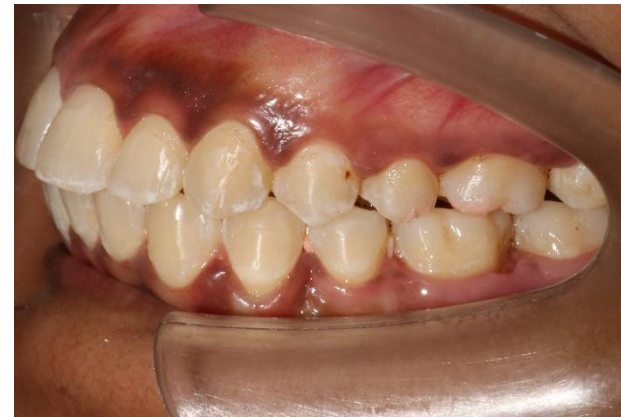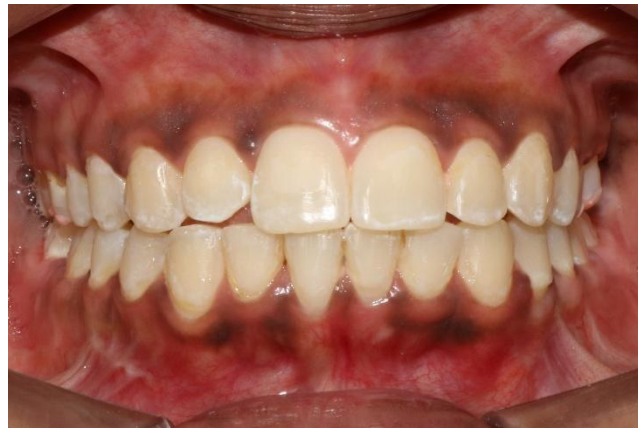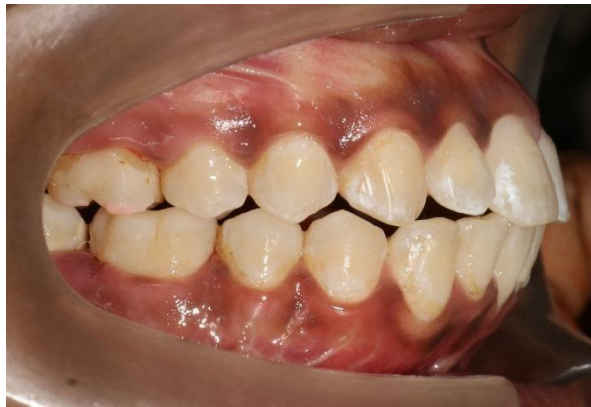DEBONDED PHOTOS



NAME : TANVEER BANU

AGE / SEX: 21 / F

OP NO: : : 202409090002

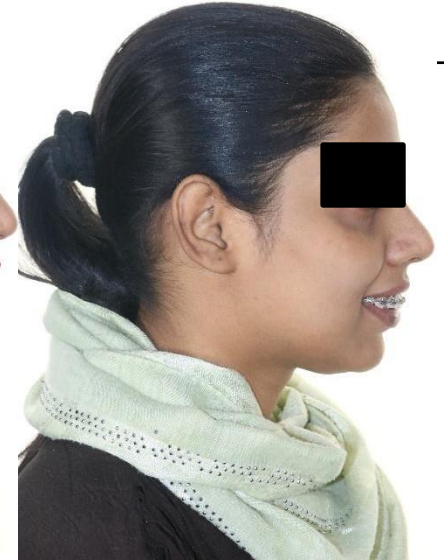
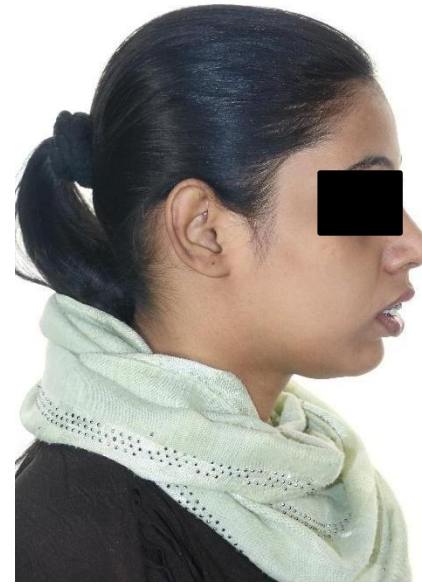
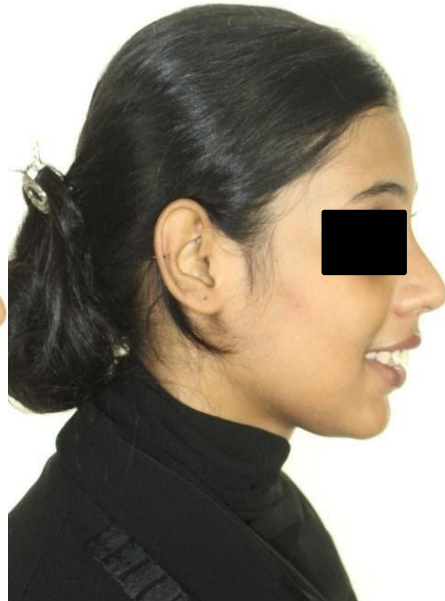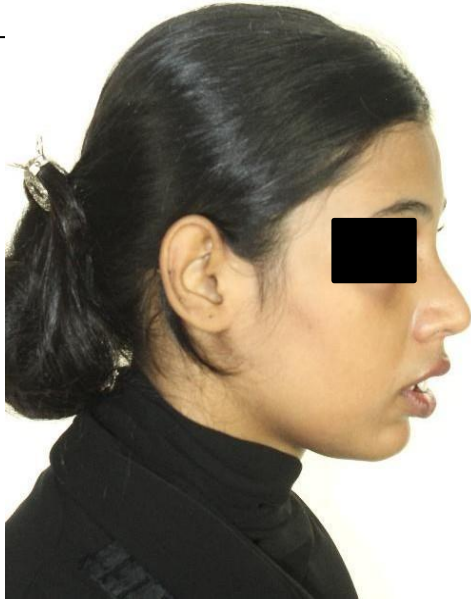EXTRA ORAL

PROFILE

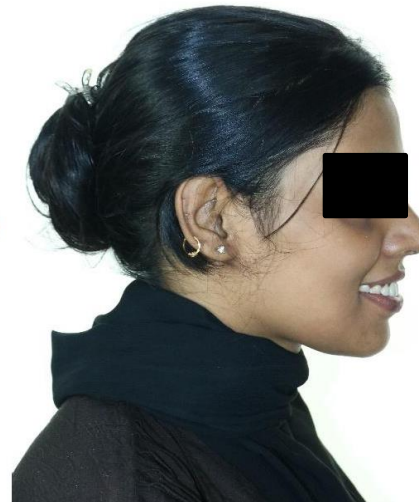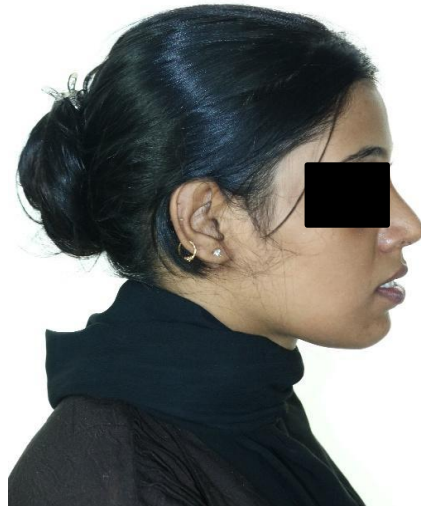NAME : TANVEER BANU

AGE / SEX: 21 / F



**PRE-
TREATMENT**

PRE-SURGICAL



POST-SURGICAL DEBOND

CASE VI:

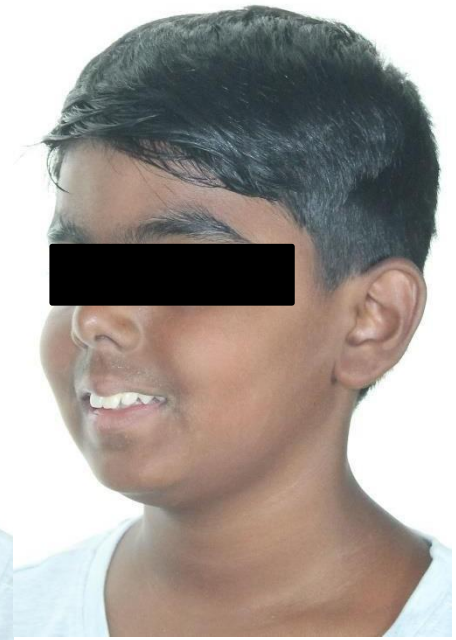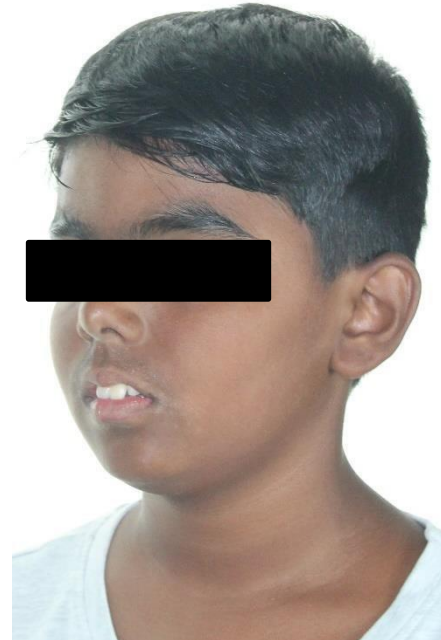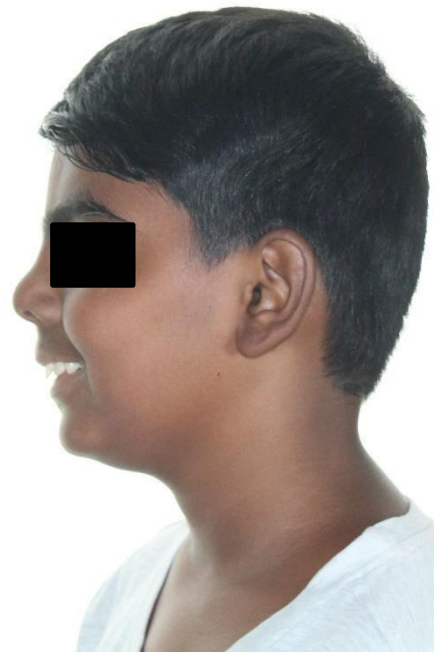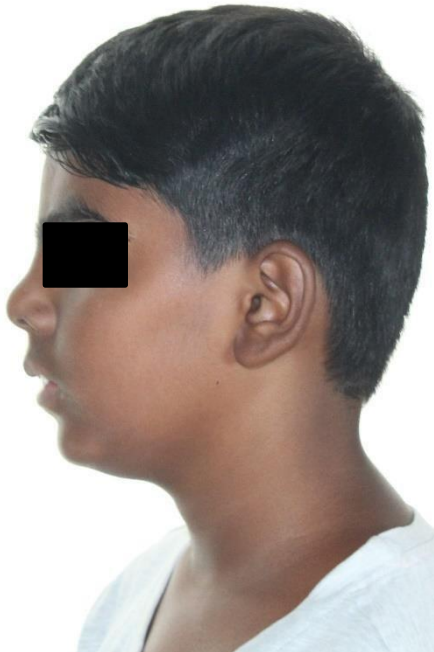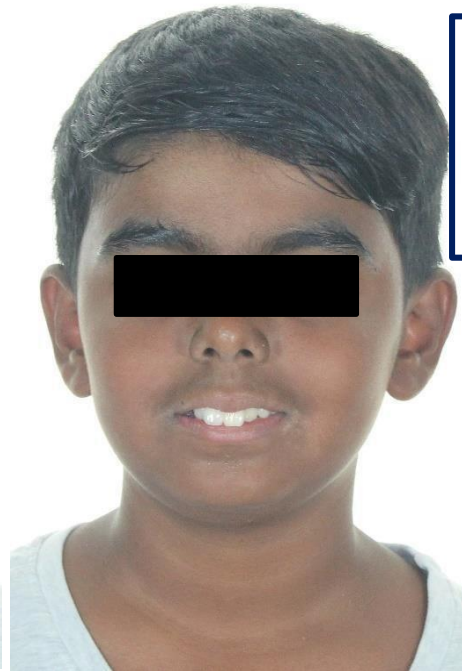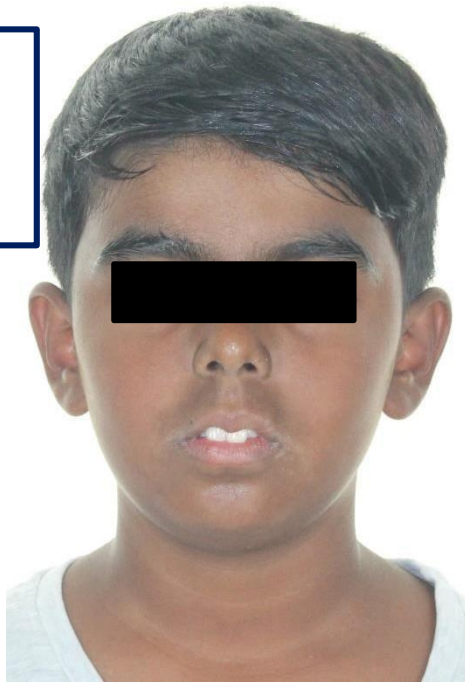NAME: Thaman Reddy ; AGE: 11YEARS/ MALE; OPNO: 202109220082

**DIAGNOSIS: ANGLES CLASS II DIVISION 1 WITH RETROGNATHIC
MAXILLA**

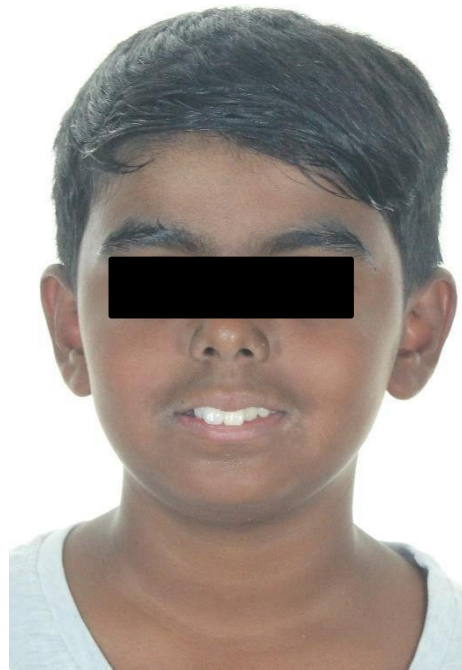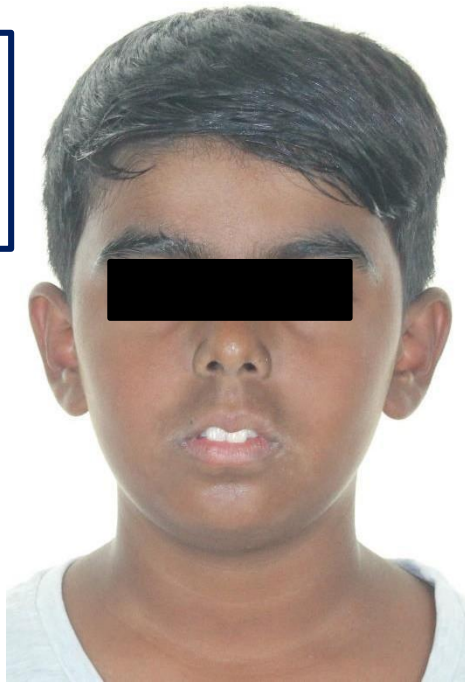**TREATMENT PLAN : TWINBLOCK WITH FIXED
MECHANOTHERAPHY**

EXTRA ORAL
PRE TREATMENT
PHOTOS

NAME: Thaman Reddy
AGE: 11 Years/M
OP No: 202109220082



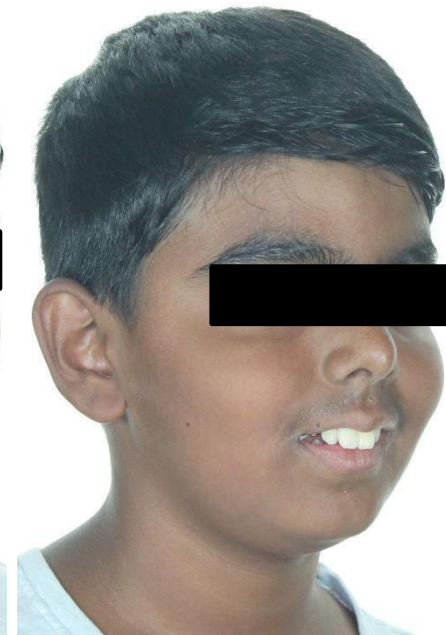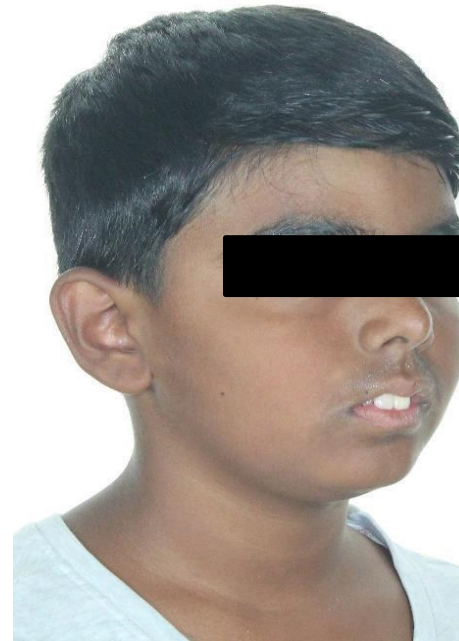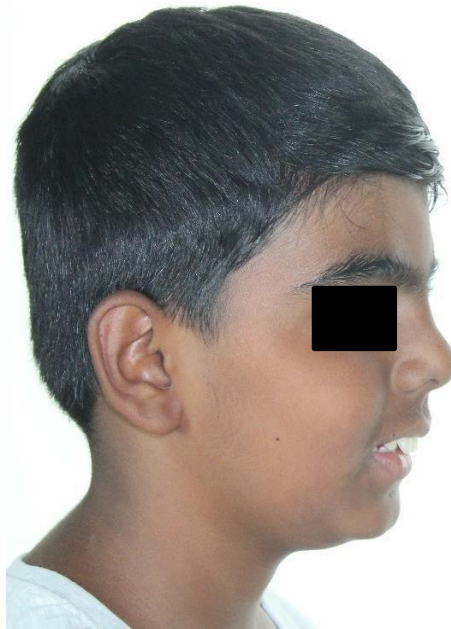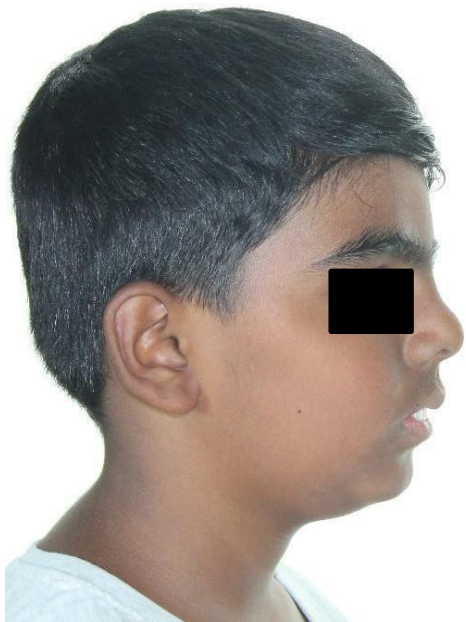EXTRA ORAL
PRE TREATMENT
PHOTOS



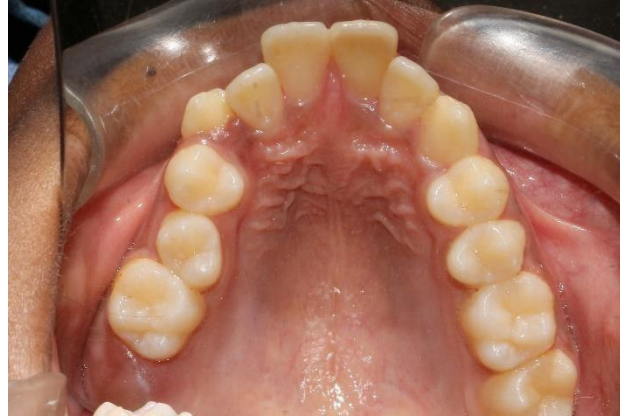NAME: Thaman Reddy

AGE: 11 Years/M

OP No: 202109220082



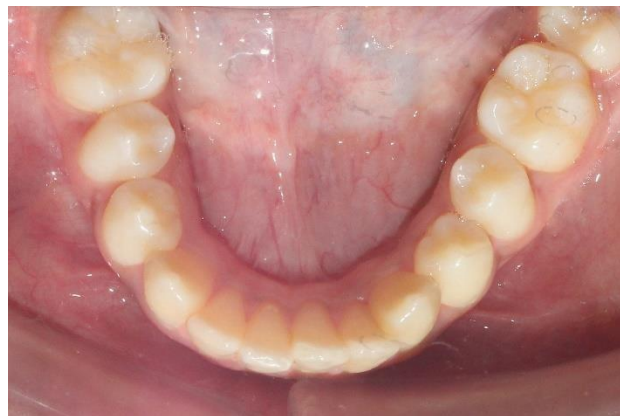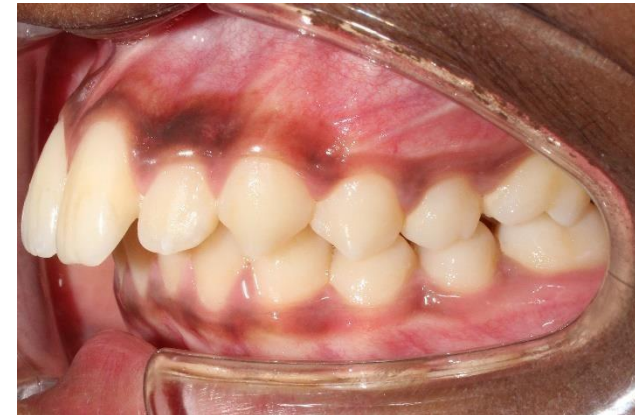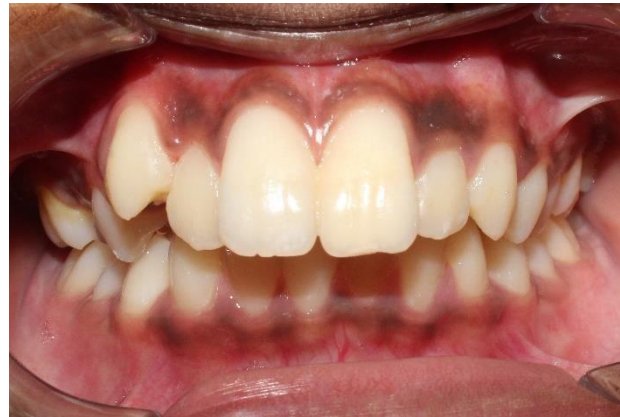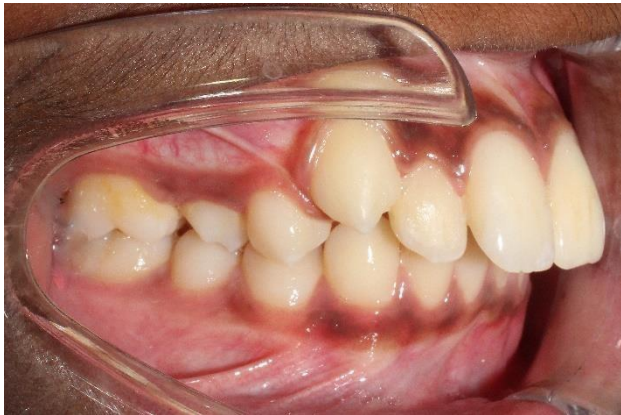INTRA ORAL
PRE TREATMENT
PHOTOS



NAME: Thaman Reddy

AGE: 11 Years/M

OP No: 202109220082



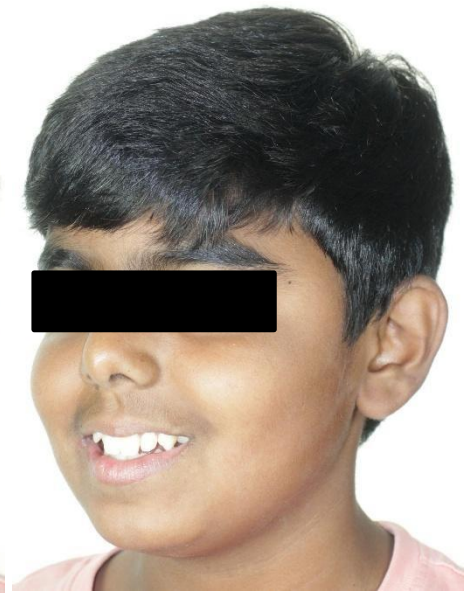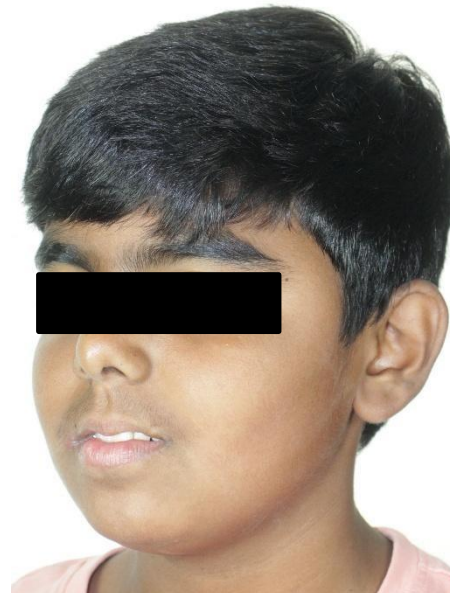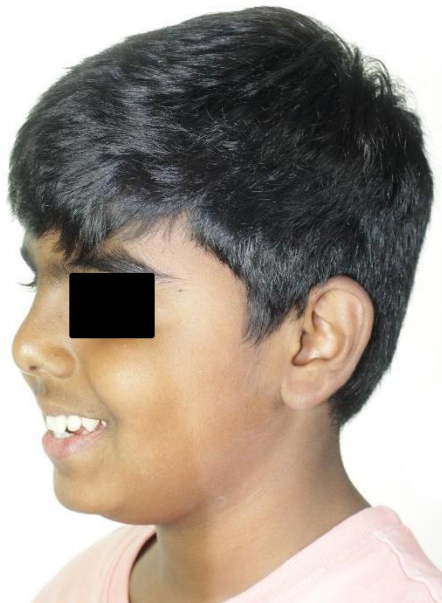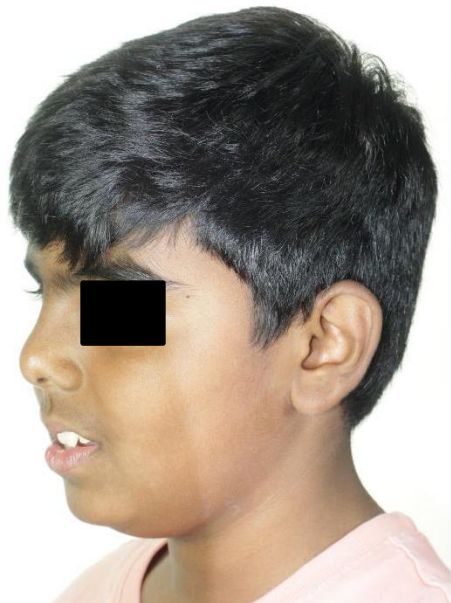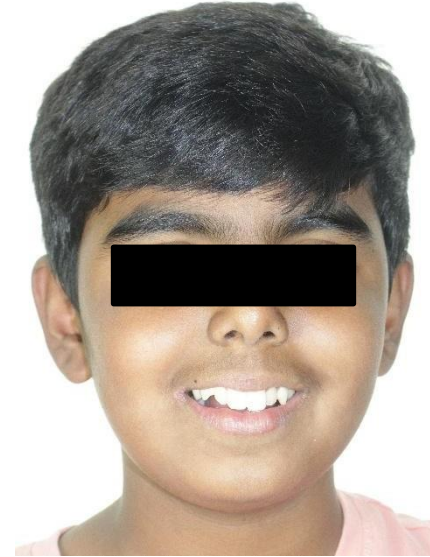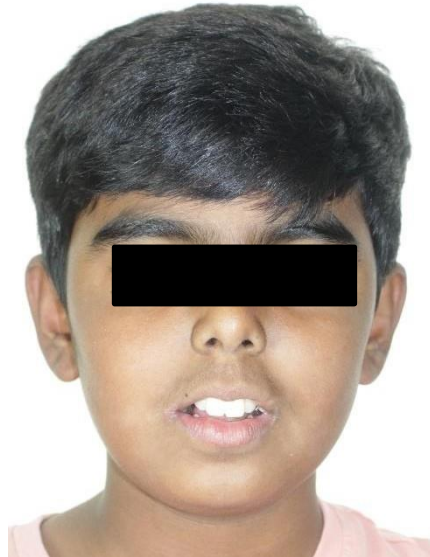EXTRA ORAL

**POST TWINBLOCK
PHOTOS**

NAME: Thaman Reddy

AGE: 12 Years/M

OP No: 202109220082



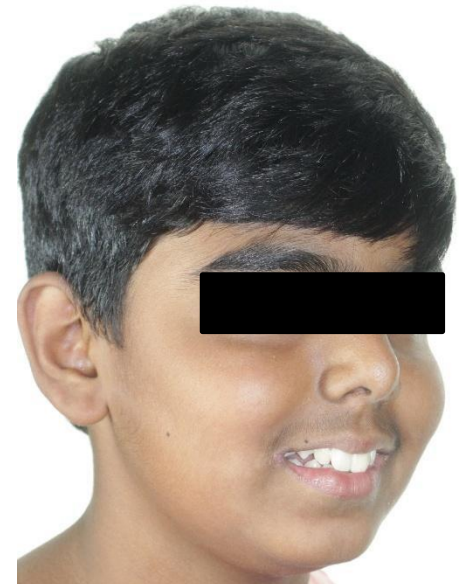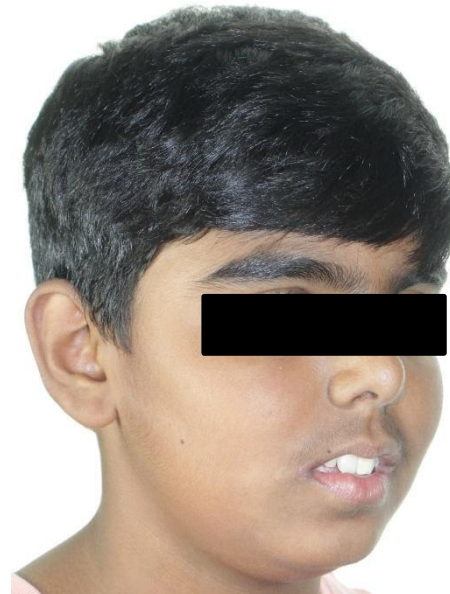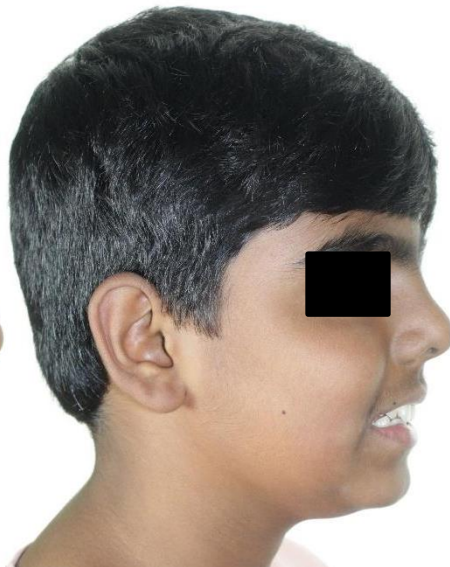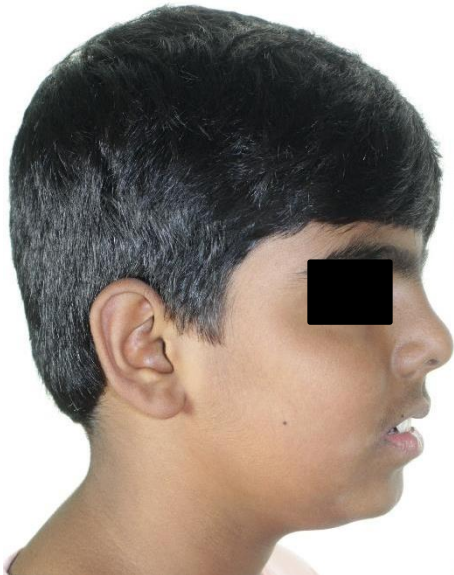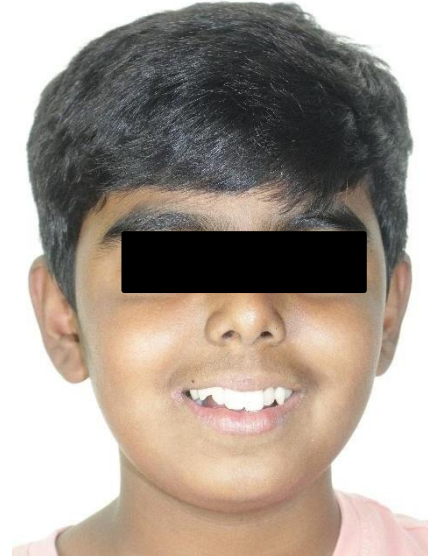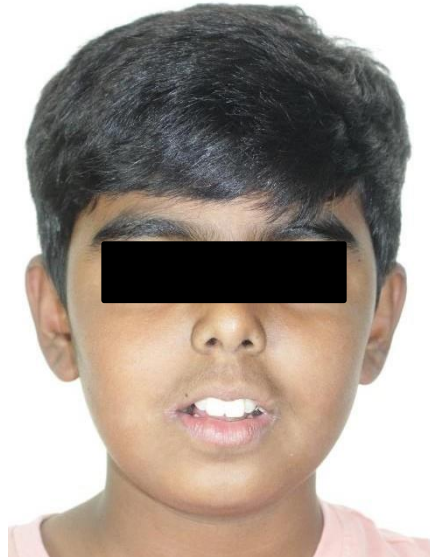EXTRA ORAL

**POST TWINBLOCK
PHOTOS**

NAME: Thaman Reddy

AGE: 12 Years/M

OP No: 202109220082



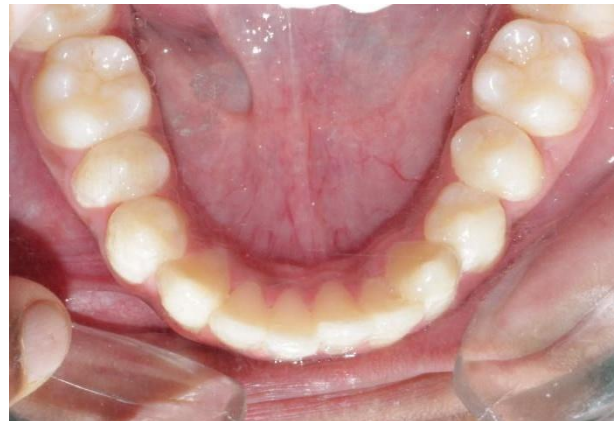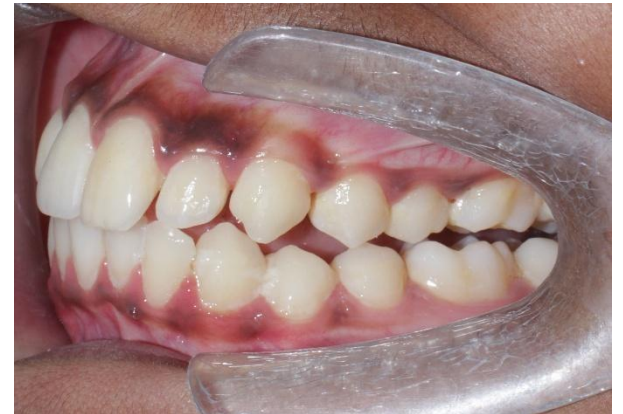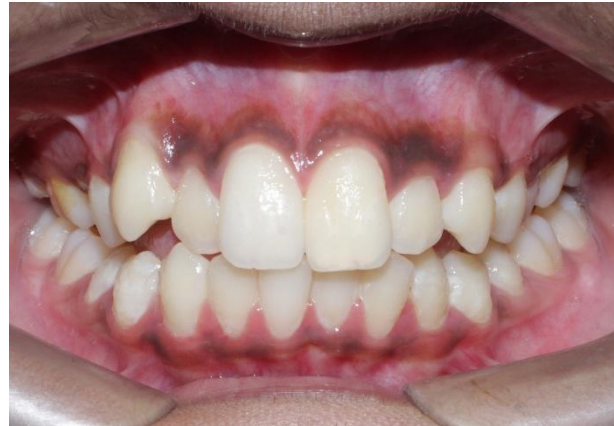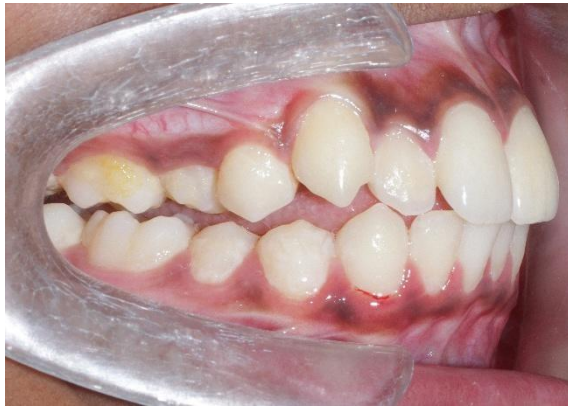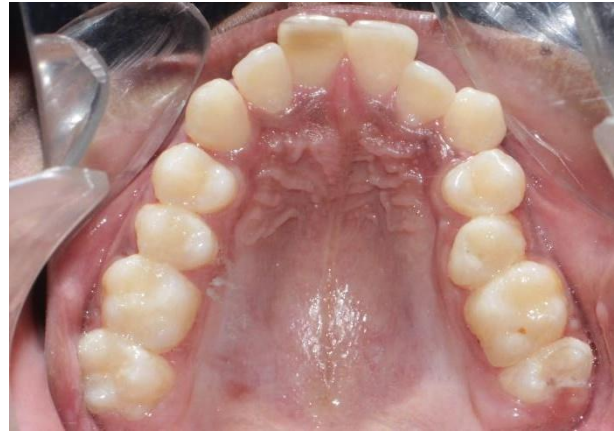INTRA ORAL

**POST TWINBLOCK
PHOTOS**

NAME: Thaman Reddy

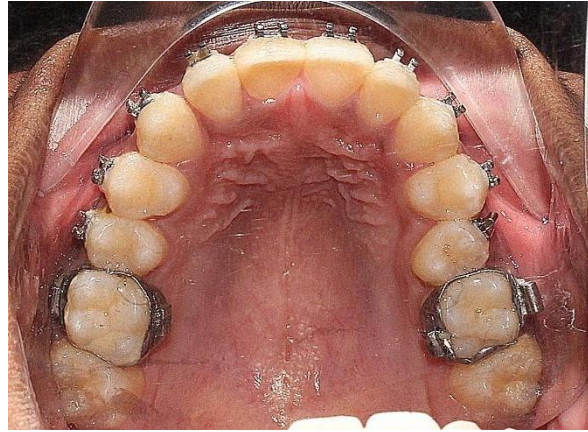AGE: 12 Years/M

OP No: 202109220082



EXTRA ORAL

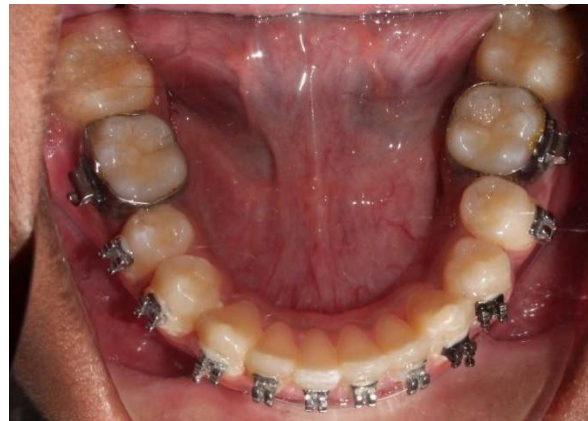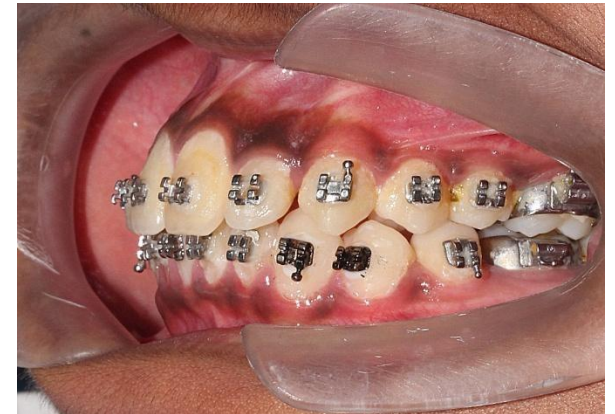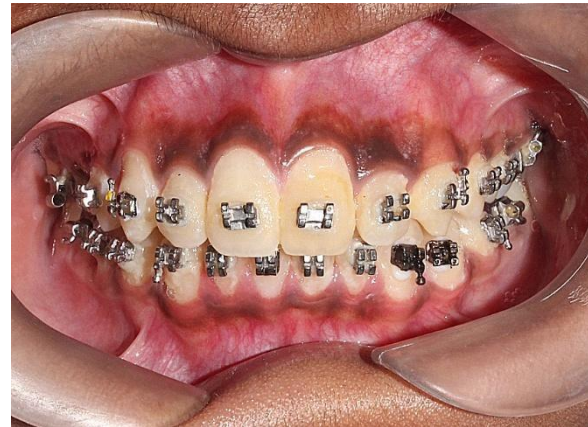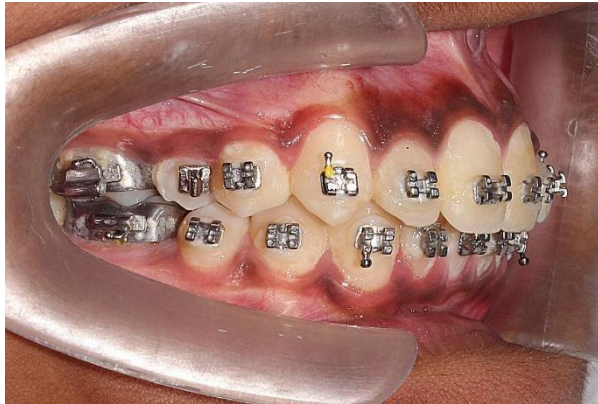STRAPUP PHOTOS



NAME: Thaman Reddy

AGE: 12 Years/M

OP No: 202109220082



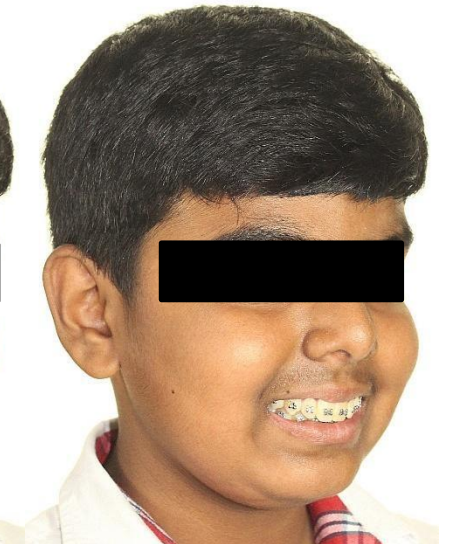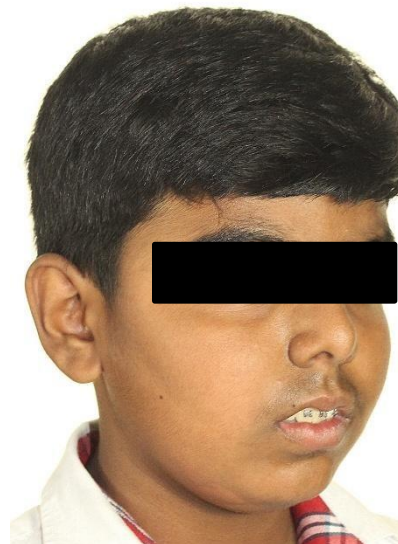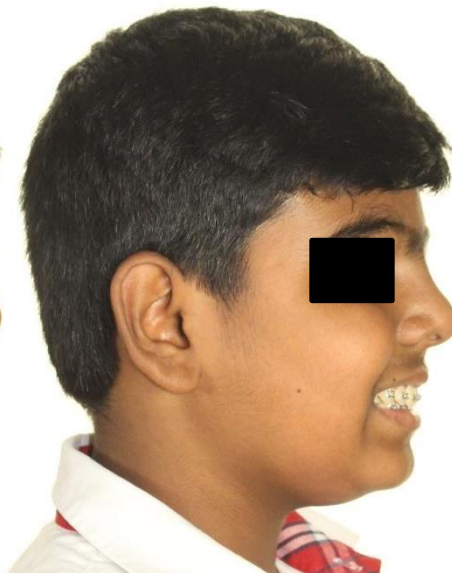
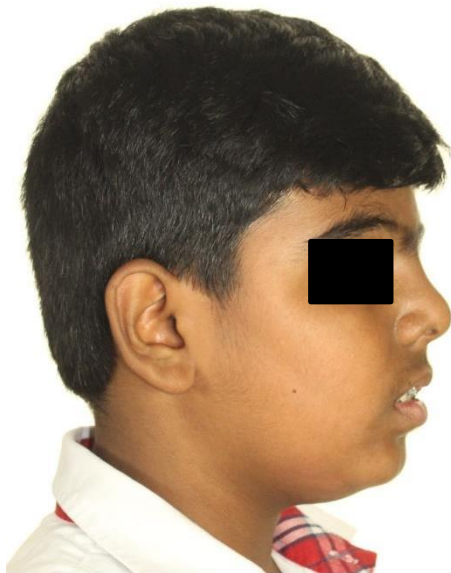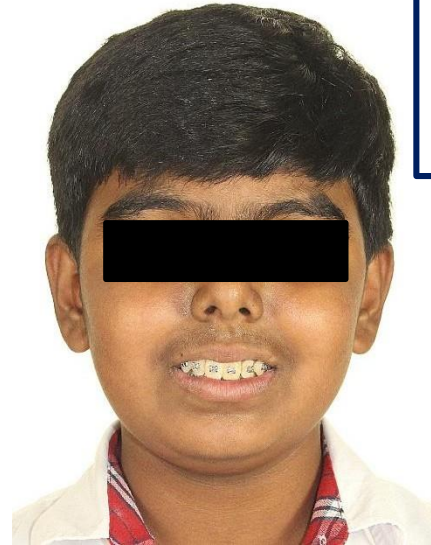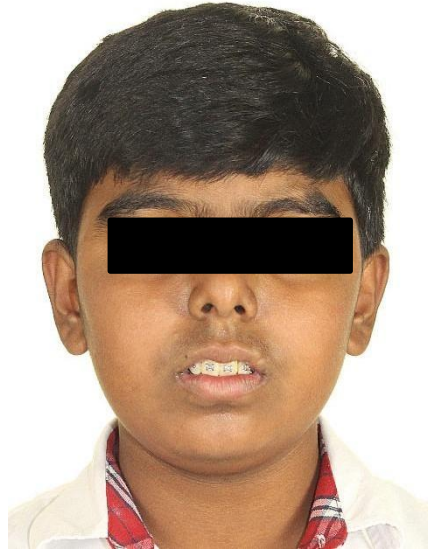EXTRA ORAL

STRAPUP PHOTOS

NAME: Thaman Reddy

AGE: 12 Years/M

OP No: 202109220082



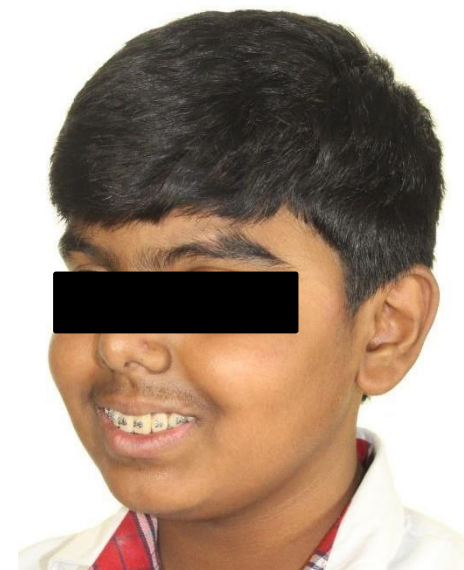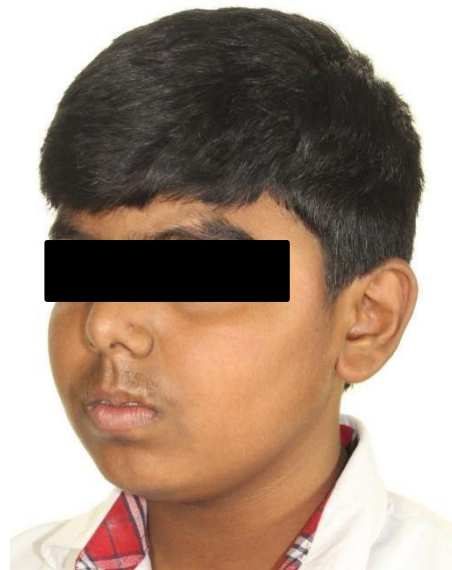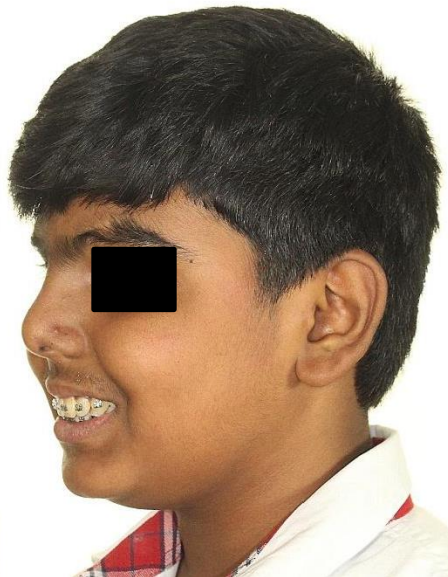
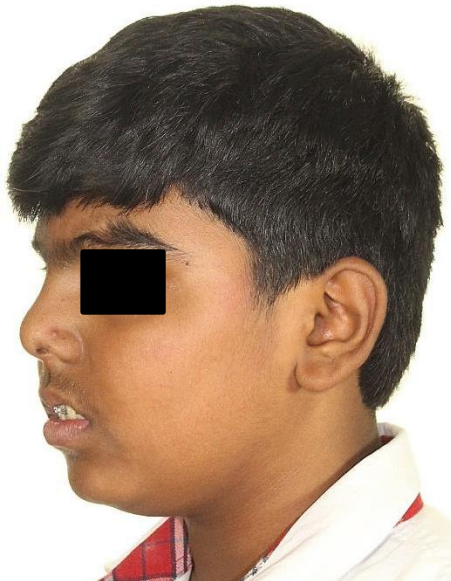
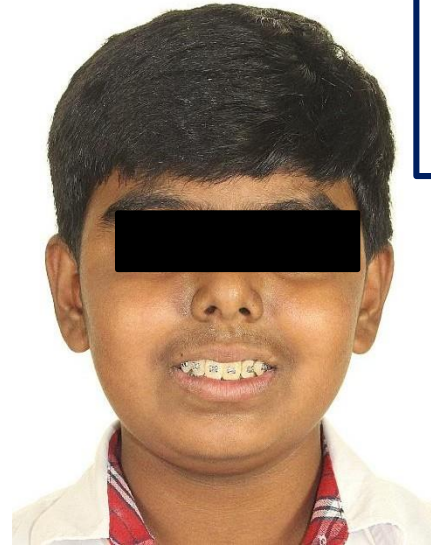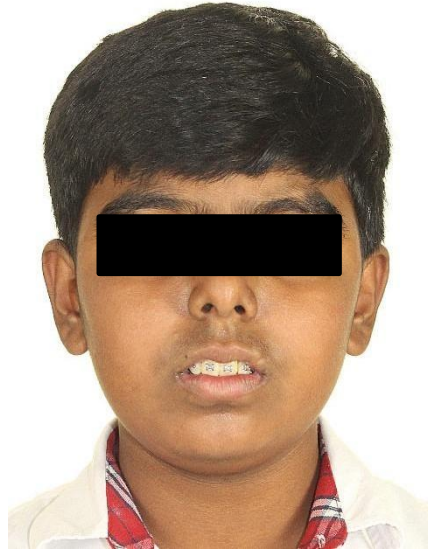EXTRA ORAL

STRAPUP PHOTOS

NAME: Thaman Reddy

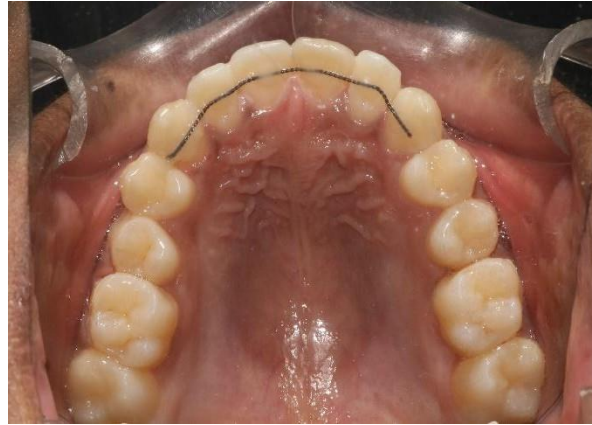
AGE: 12 Years/M

OP No: 202109220082



INTRA ORAL

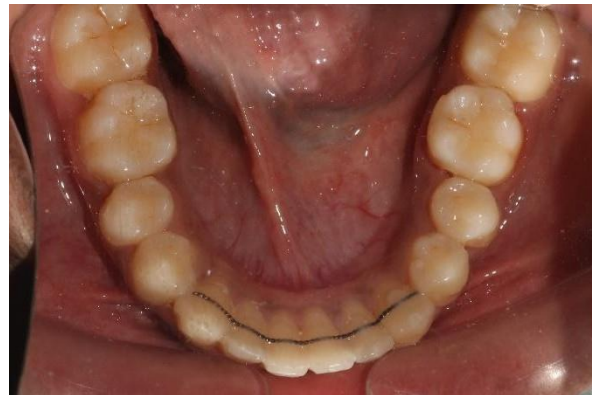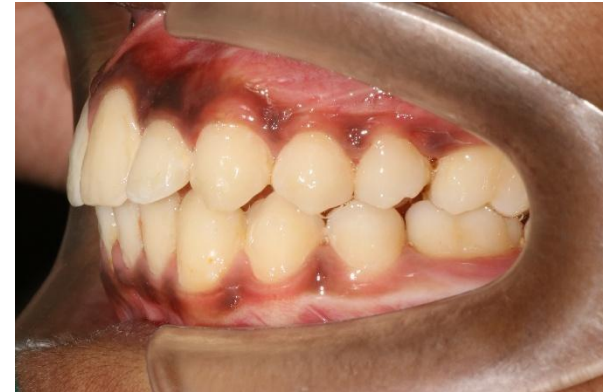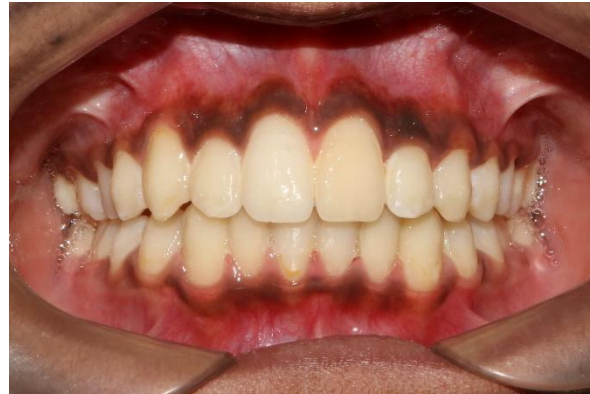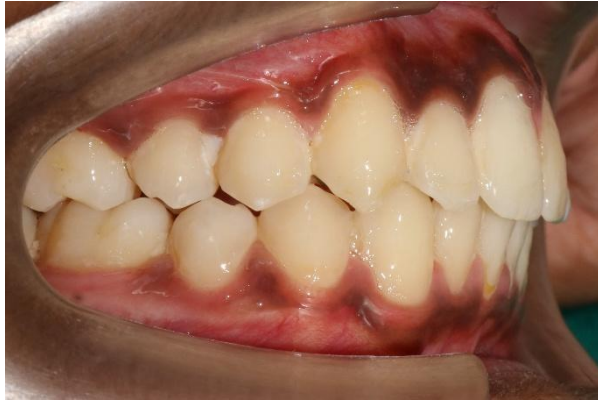DEBONDED PHOTOS



NAME: Thaman Reddy

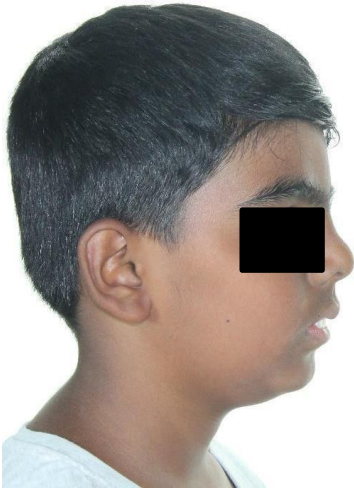AGE: 12 Years/M

OP No: 202109220082

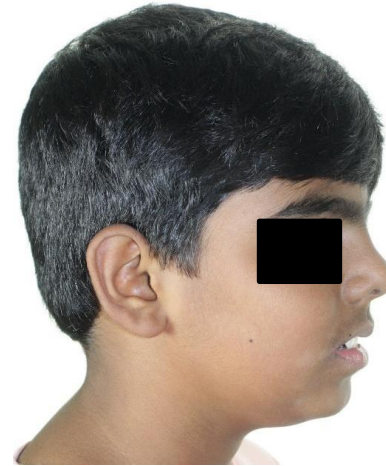
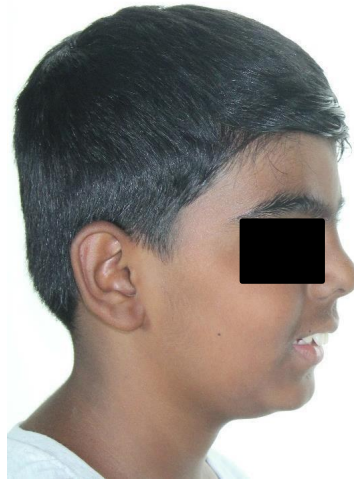
EXTRA ORAL
PROFILE
PHOTOS

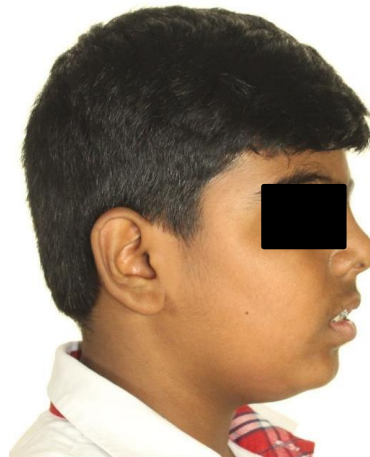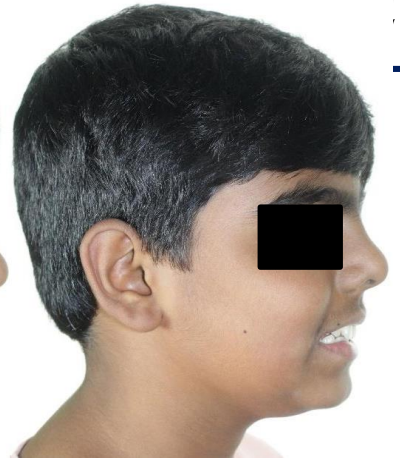NAME: Thaman Reddy
AGE: 11 Years/M



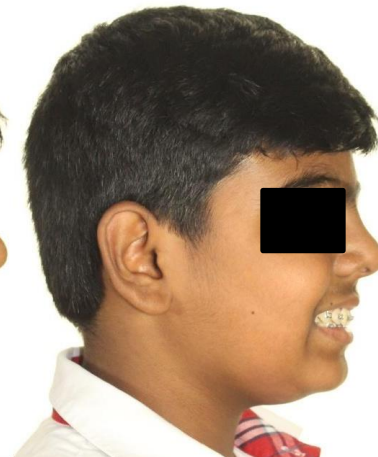
PRE-TWIN BLOCK



POST-TWIN BLOCK



STRAP-UP



CASE VII:

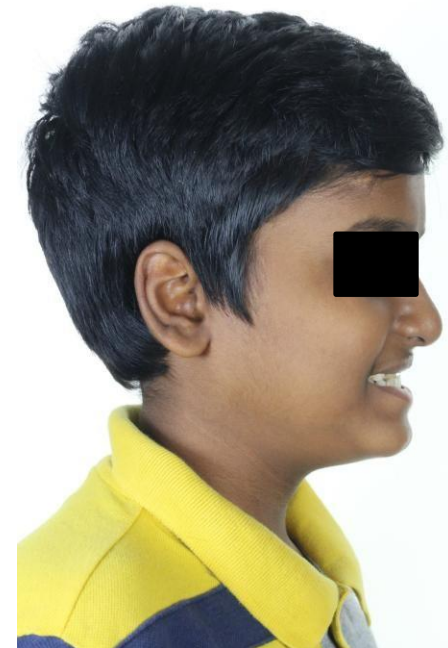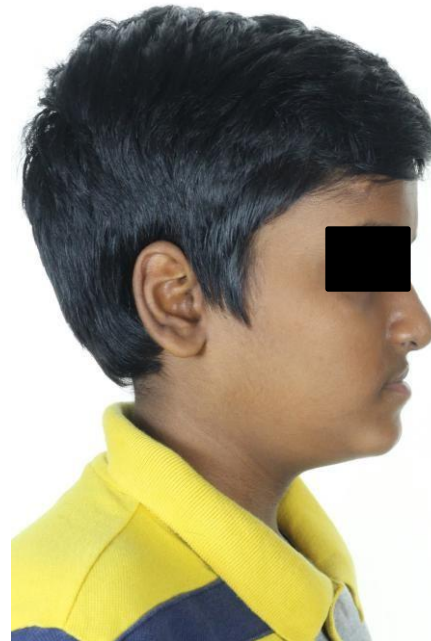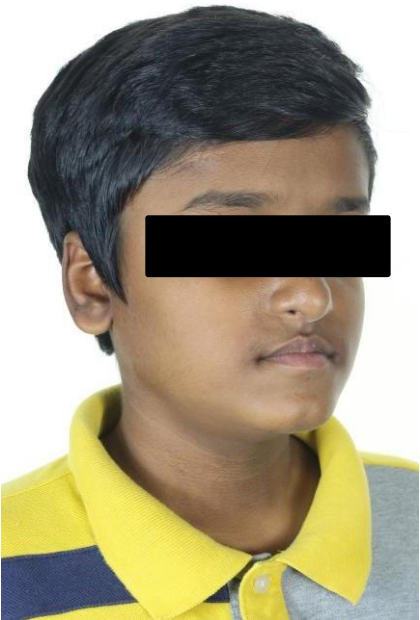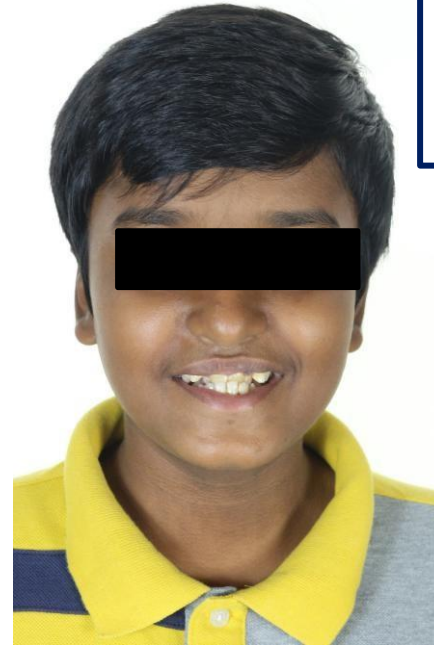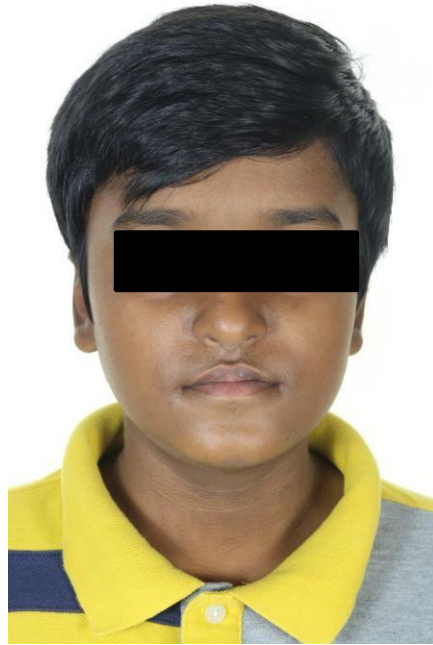NAME: Sreevatsa ; AGE: 14YEARS/ MALE; OPNO: 202112270042

**DIAGNOSIS: ANGLES CLASS I MALOCCLUSION WITH ANTERIOR
CROSSBITE**

**TREATMENT PLAN : SAGGITAL BONDED RME + UPPER 4'S
EXTRACTION**

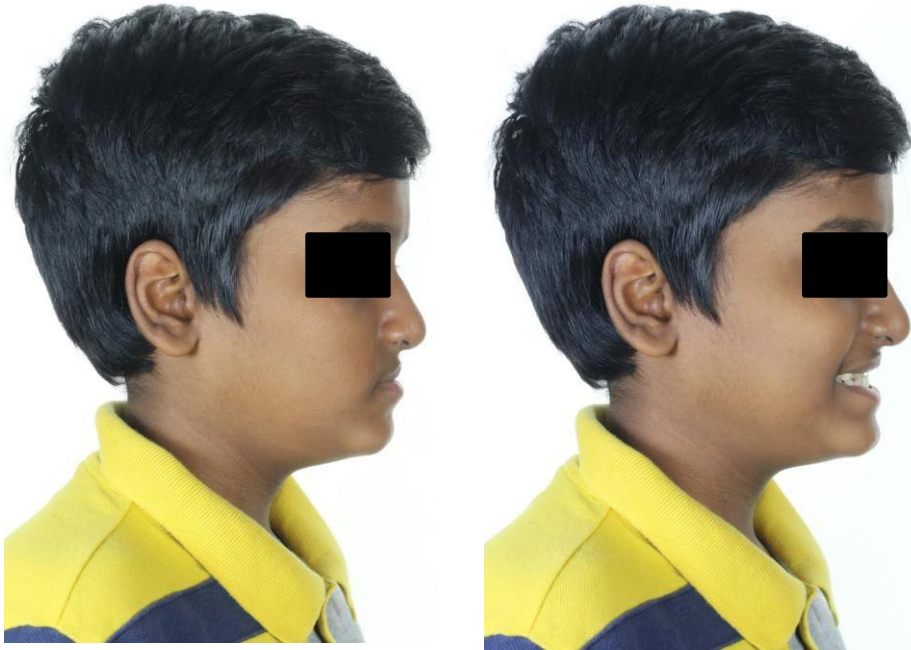**PRE TREATMENT
PHOTOS**

NAME: Sreevatsa
AGE: 14 Years/M
OP No: 202112270042

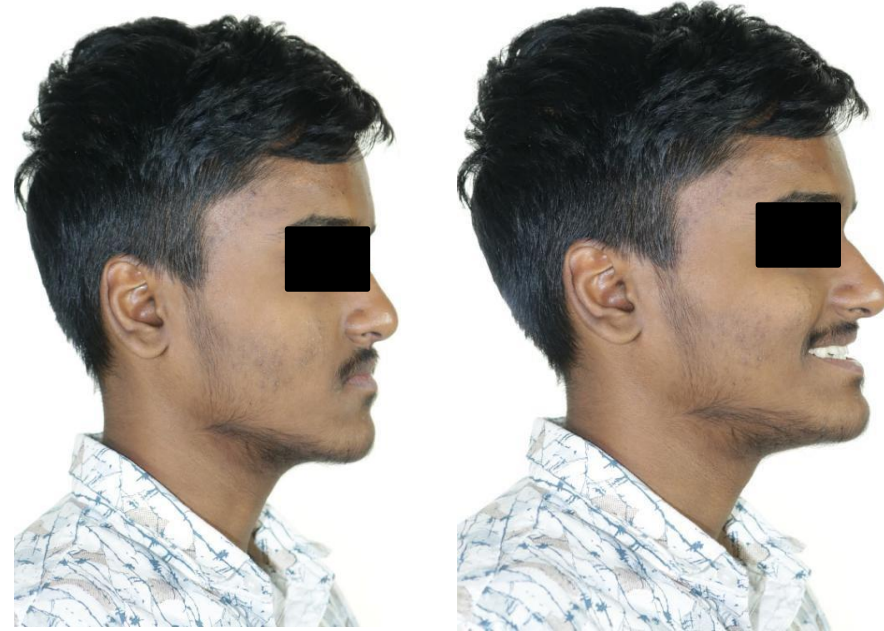

**PROFILE
PHOTOS**

NAME: Sreevatsa
AGE: 14 Years/M
OP No: 202112270042



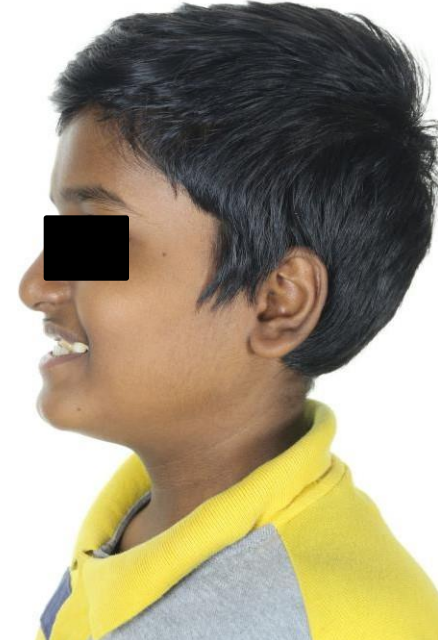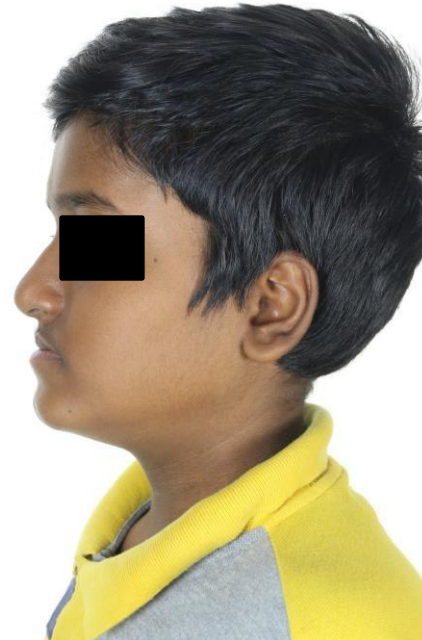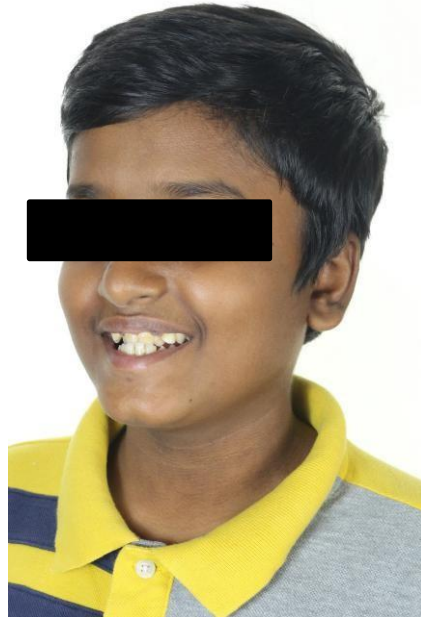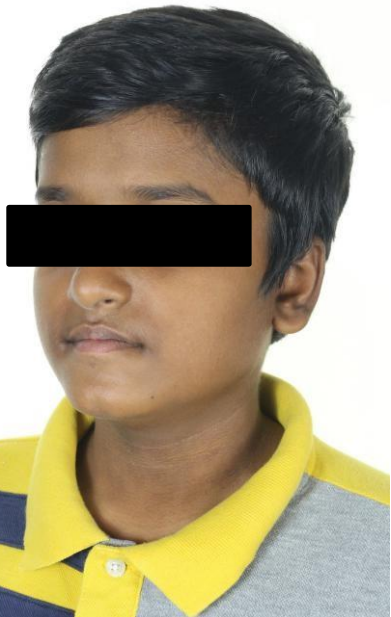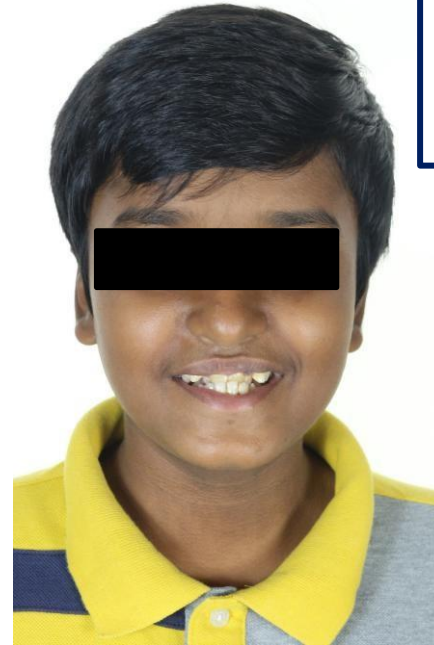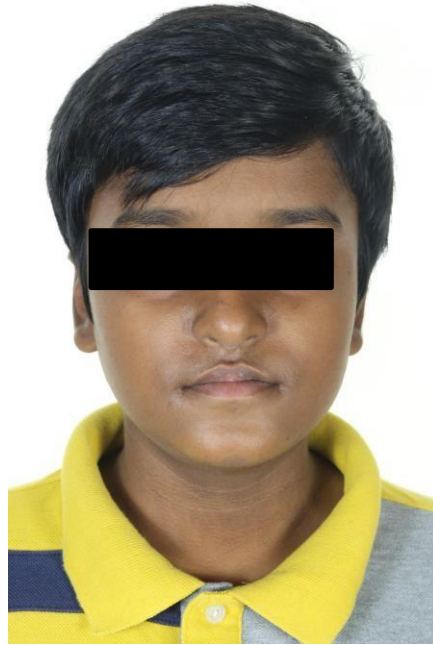PRE-TREATMENT



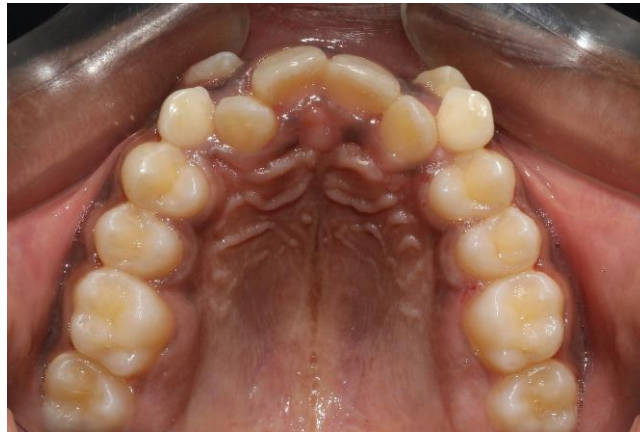POST-TREATMENT

**PRE TREATMENT
PHOTOS**

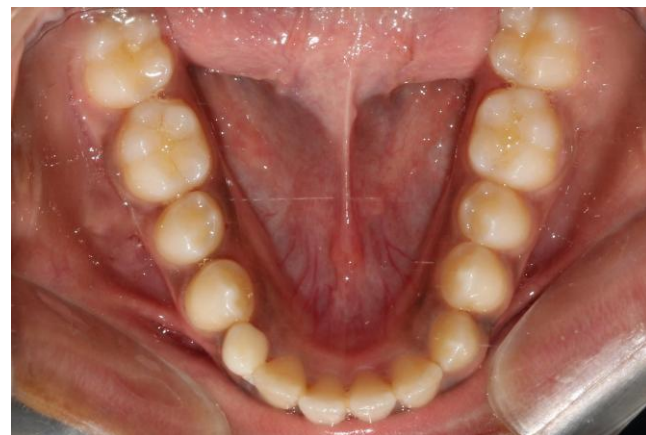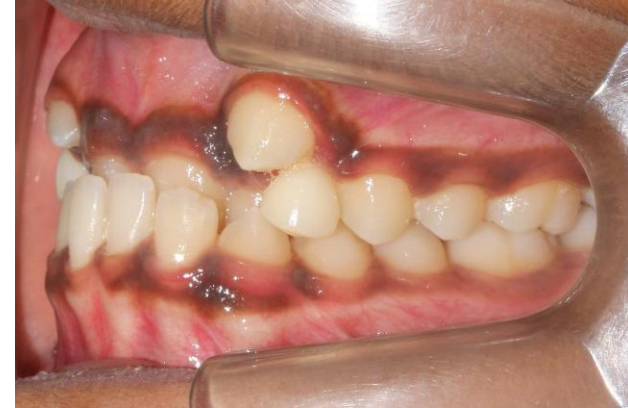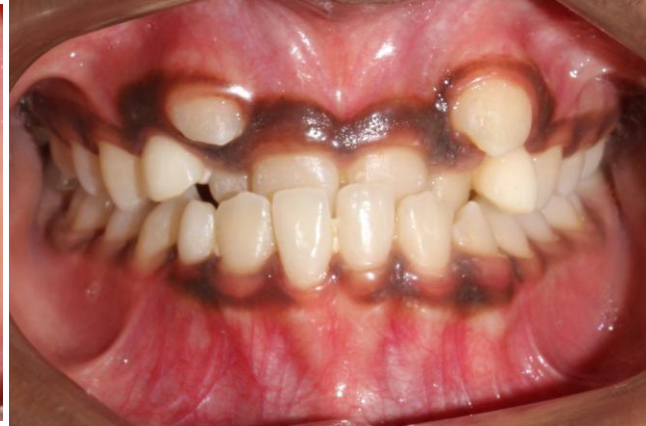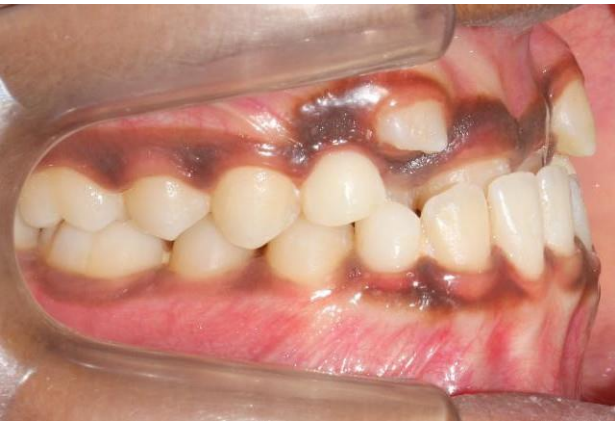NAME: Sreevatsa
AGE: 14 Years/M
OP No: 202112270042



**PRE TREATMENT
PHOTOS**

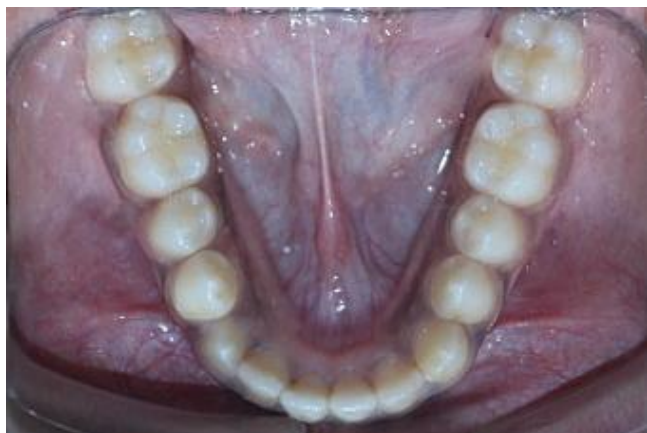
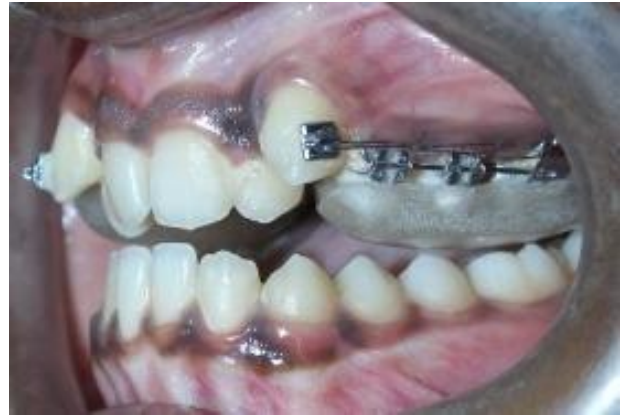
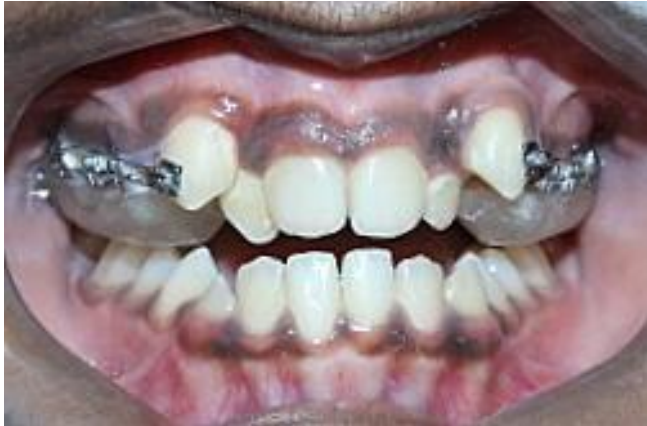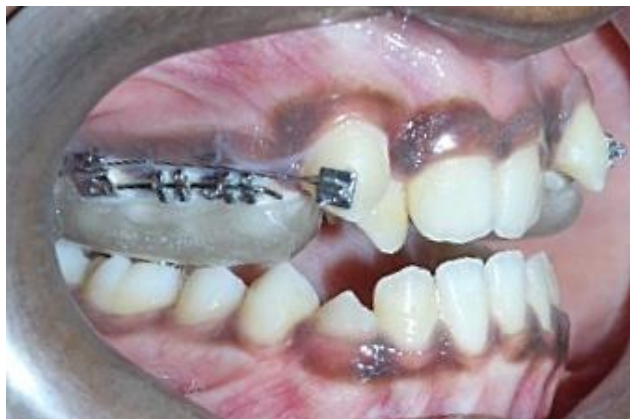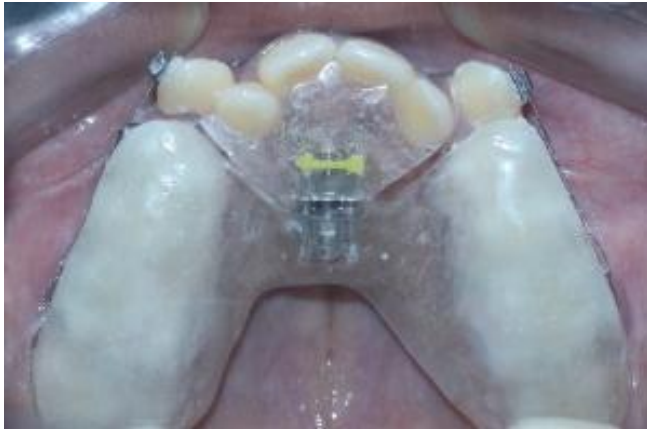NAME: Sreevatsa
AGE: 14 Years/M
OP No: 202112270042



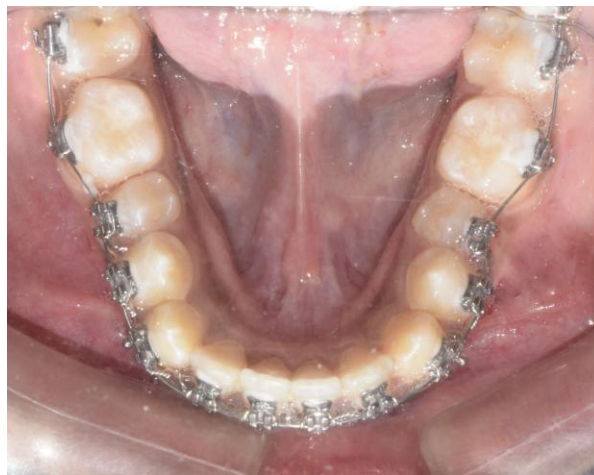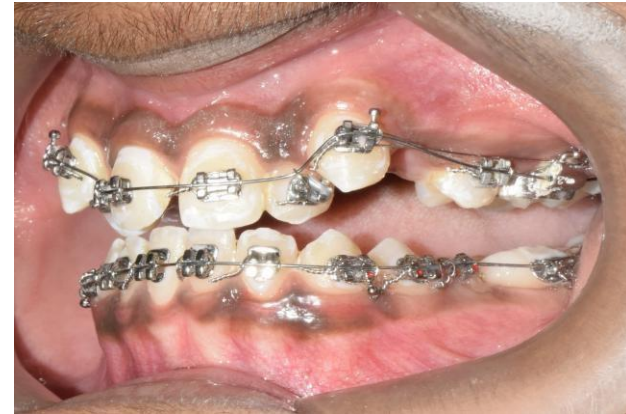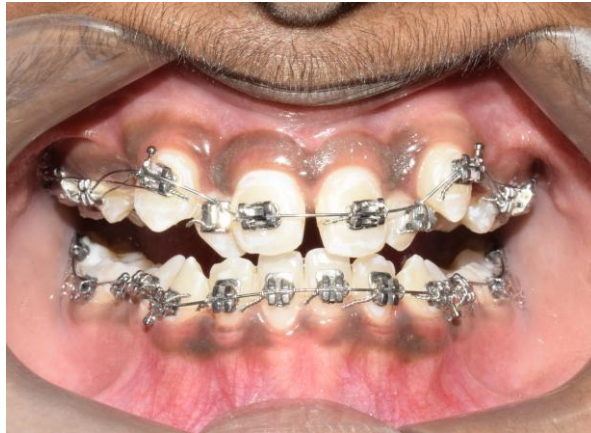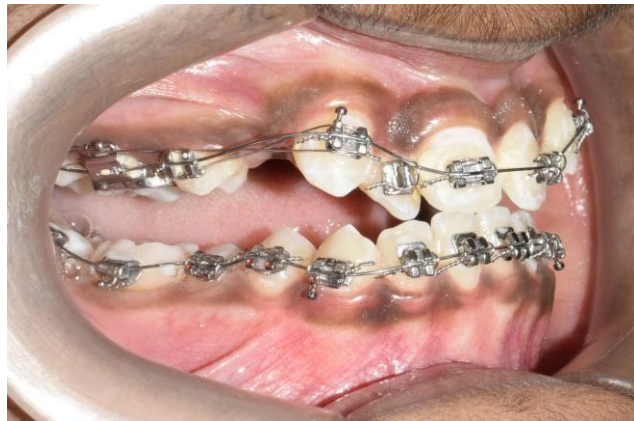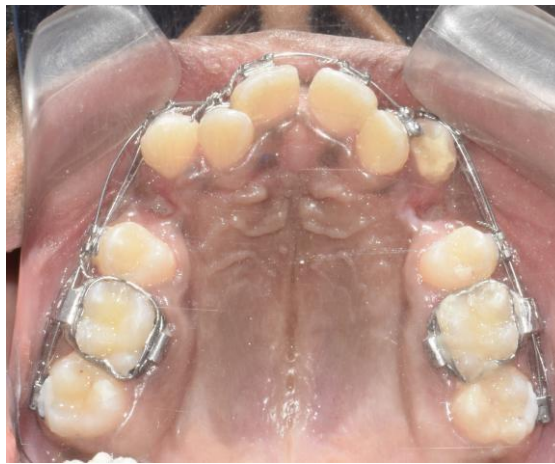
**BONDED RME
PHOTOS**

NAME: Sreevatsa
AGE: 14 Years/M
OP No: 202112270042



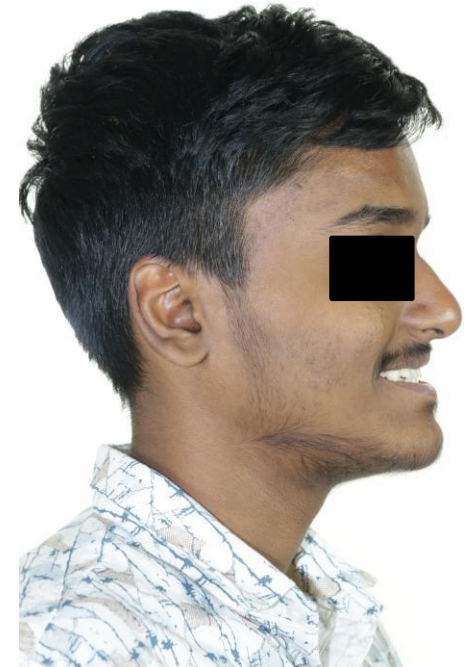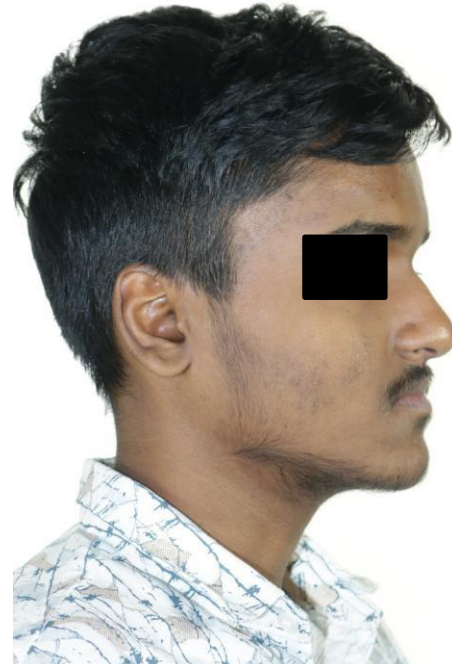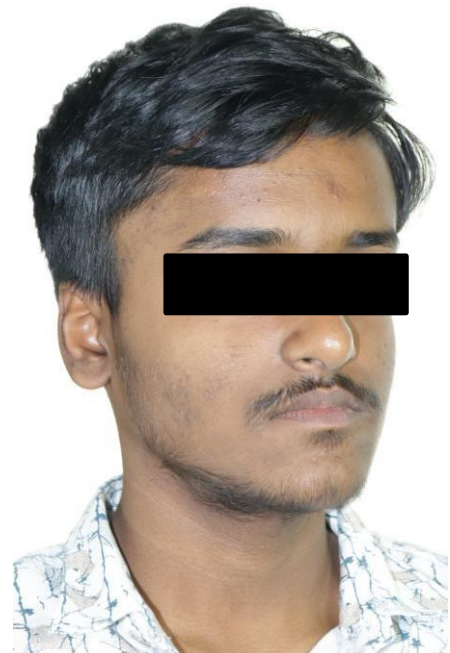**STRAP UP
PHOTOS**

NAME: Sreevatsa
AGE: 14 Years/M
OP No: 202112270042



**POST DENBOND
PHOTOS**

NAME: Sreevatsa
AGE: 14 Years/M
OP No: 202112270042

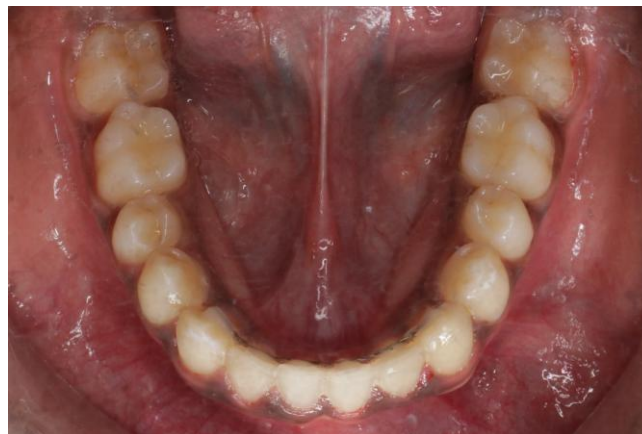
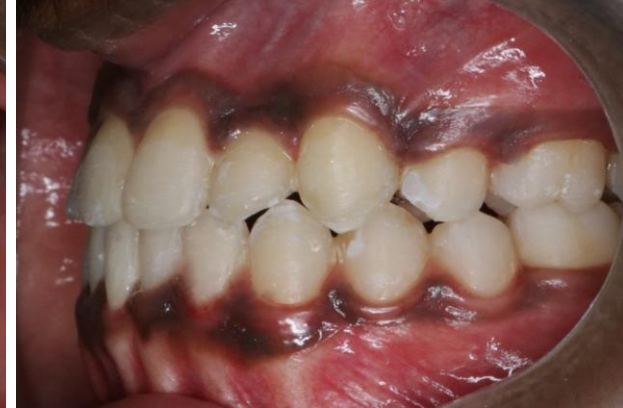
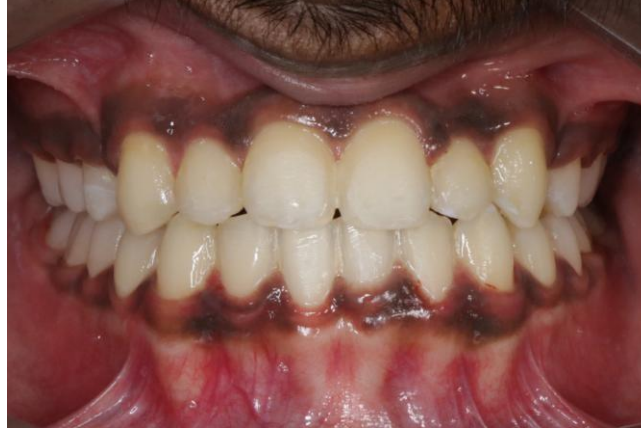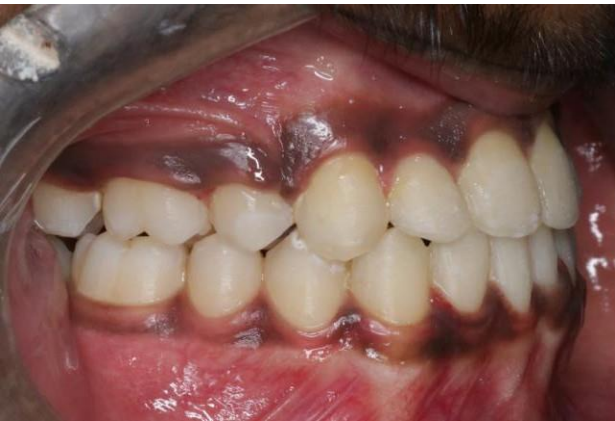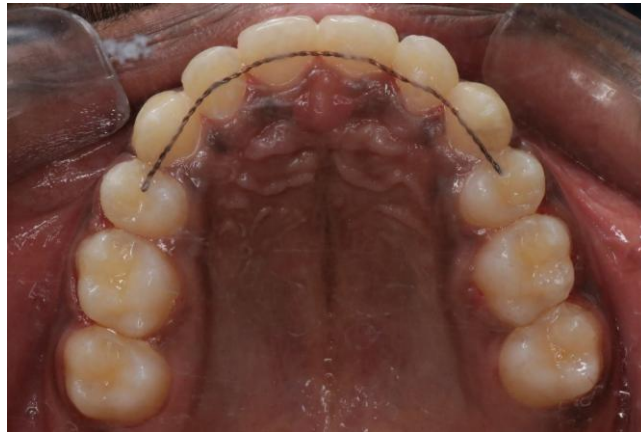**POST DENBOND
PHOTOS**

NAME: Sreevatsa

AGE: 14 Years/M

OP No: 202112270042



CASE VIII:

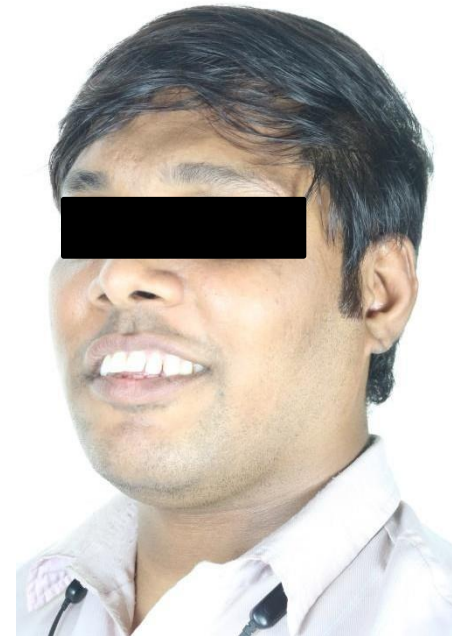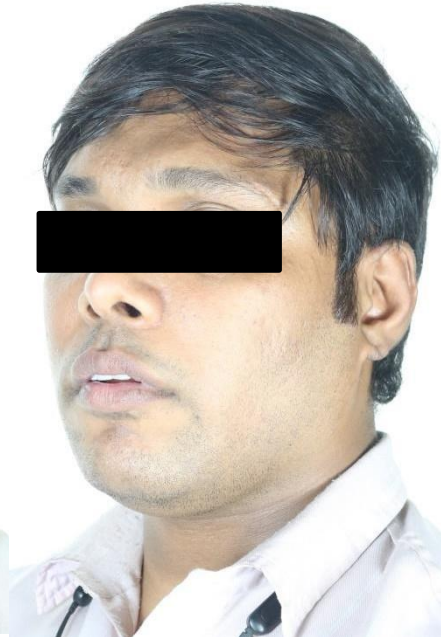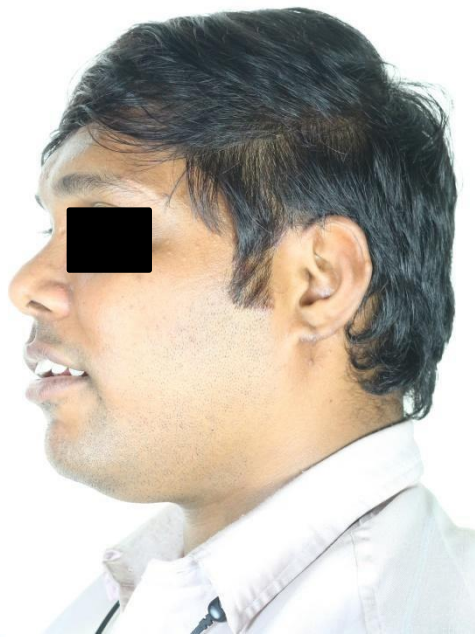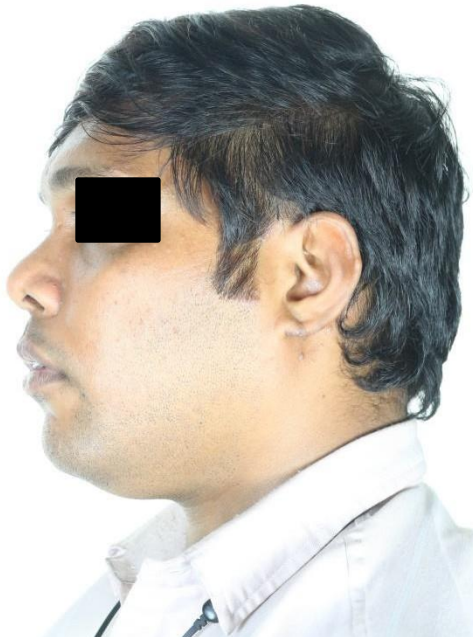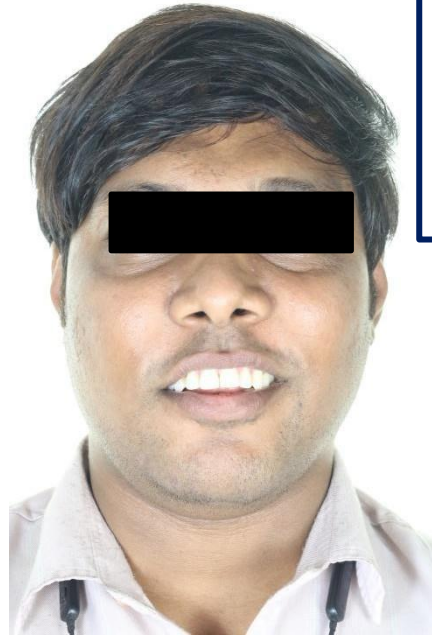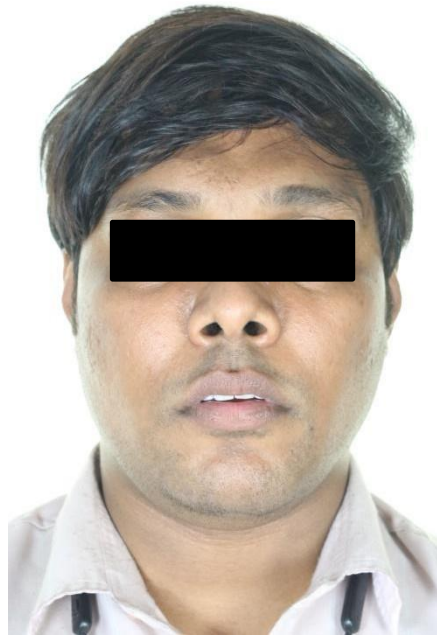NAME: Imranuddin; AGE: 33YEARS/ MALE; OPNO: 202112100045

**DIAGNOSIS: ANGLES CLASS I MALOCCLUSION WITH SPACING AND
AGGRESSIVE PERIODONTITIS**

TREATMENT PLAN :NON EXTRACTION TREATMENT

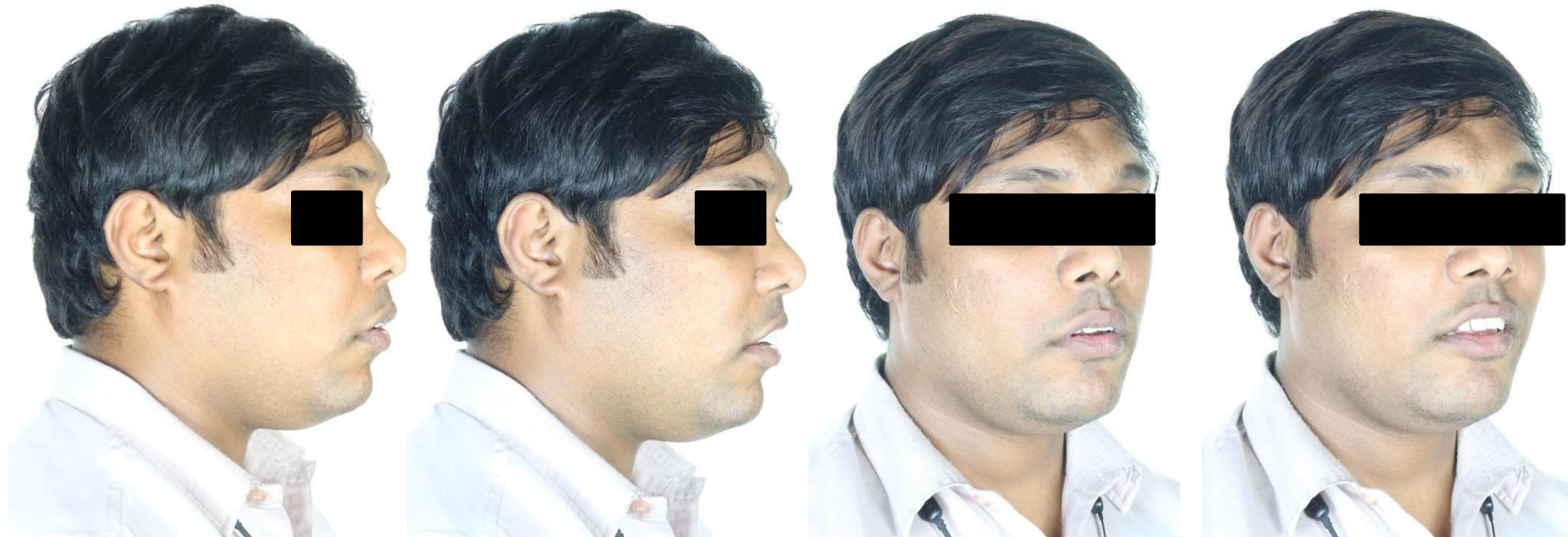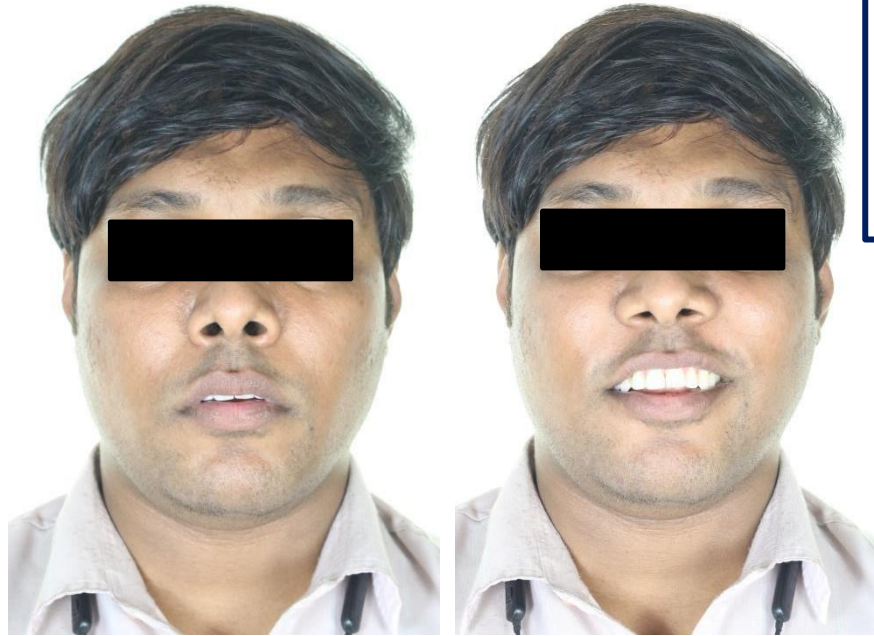EXTRA ORAL
PRE TREATMENT
PHOTOS

NAME: Imranuddin
AGE: 33 Years/M
OP No: 202112100045

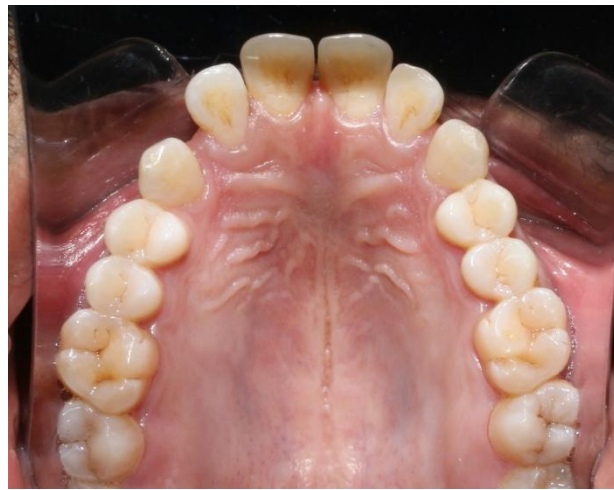

EXTRA ORAL
PRE TREATMENT
PHOTOS

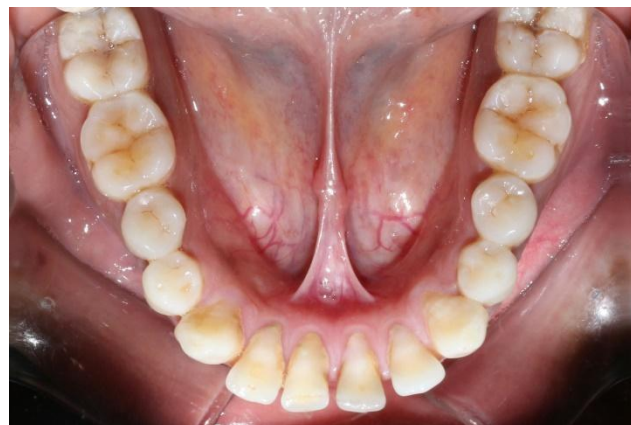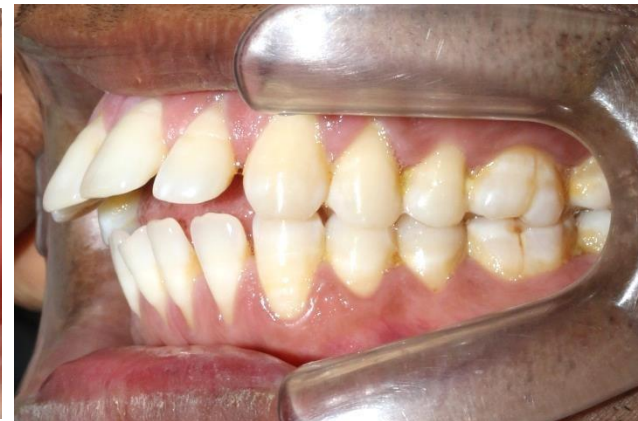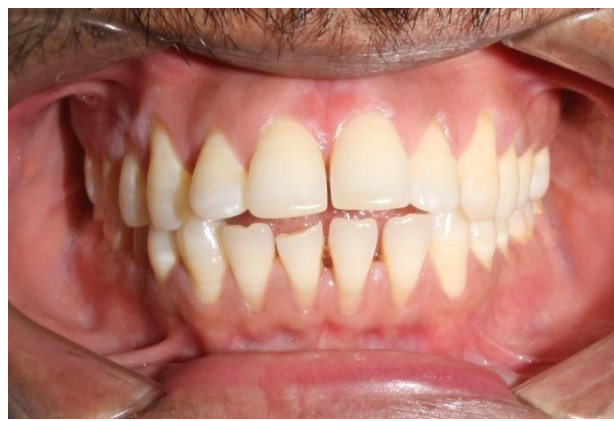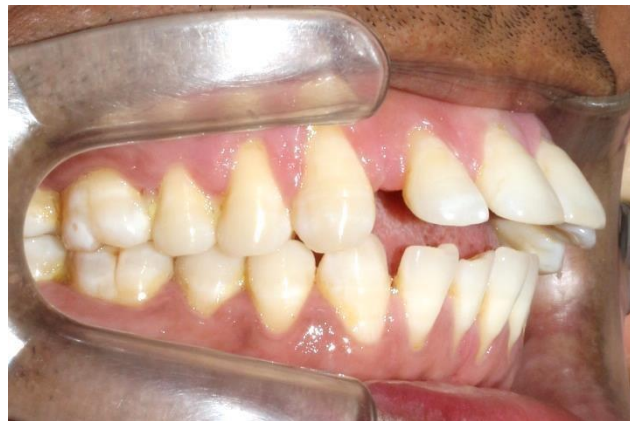NAME: Imranuddin
AGE: 33 Years/M
OP No: 202112100045



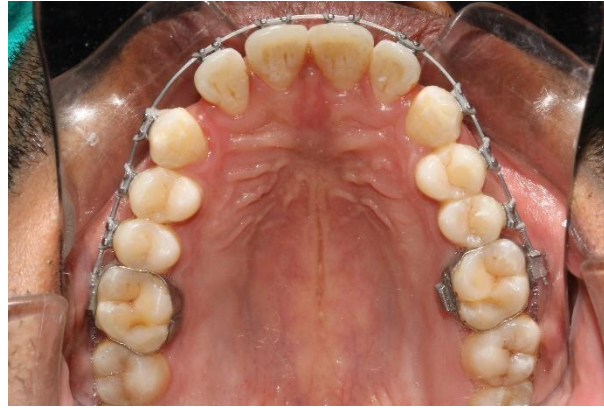INTRA ORAL
PRE TREATMENT
PHOTOS



NAME: Imranuddin
AGE: 33 Years/M
OP No: 202112100045



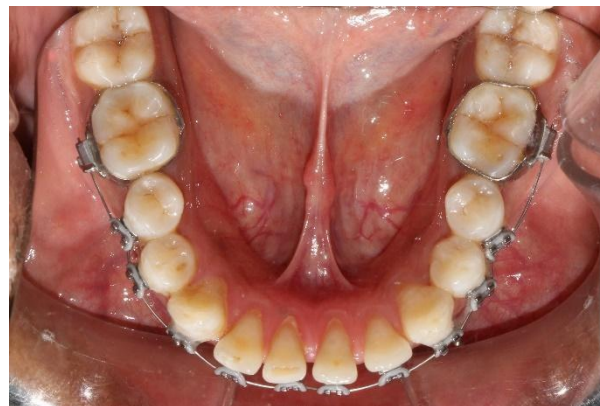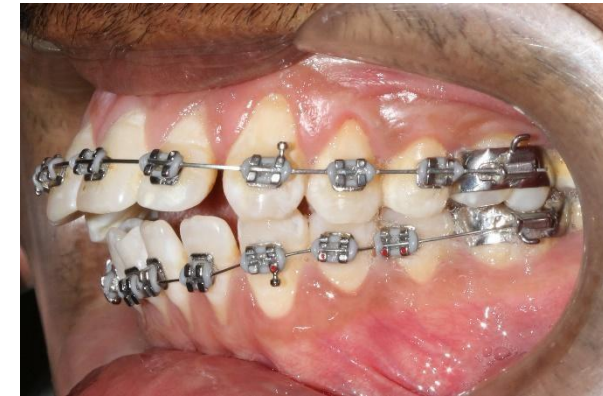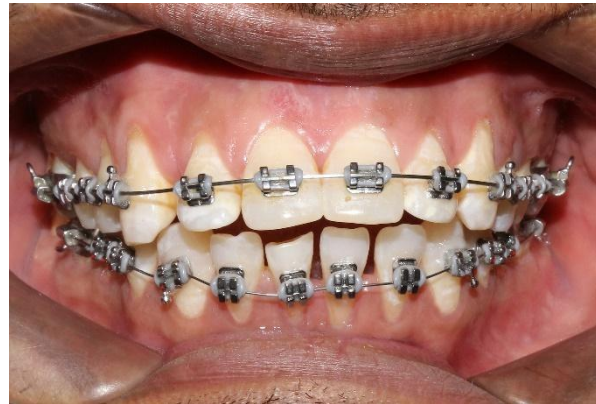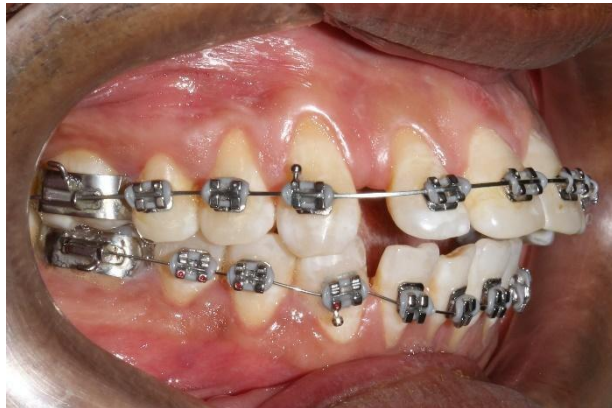STRAP UP



NAME: Imranuddin

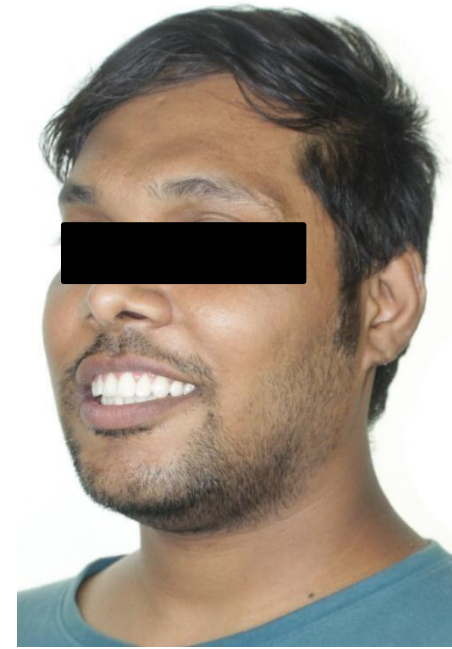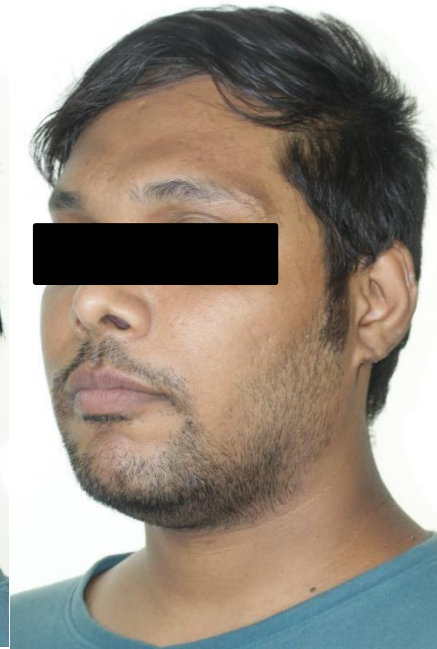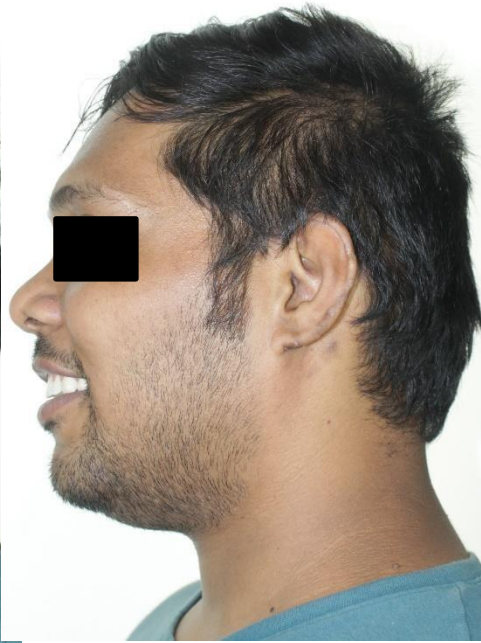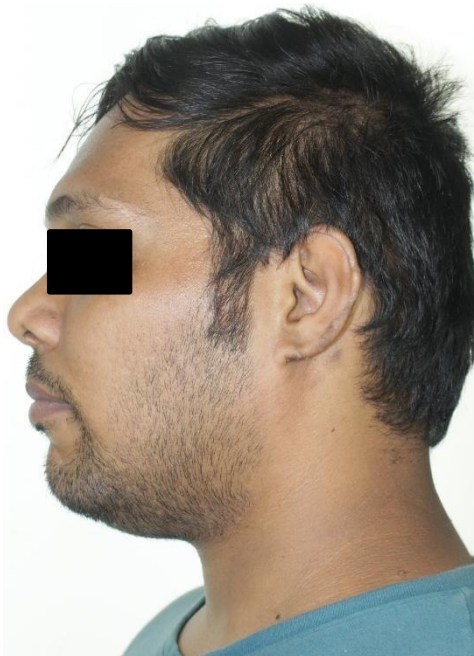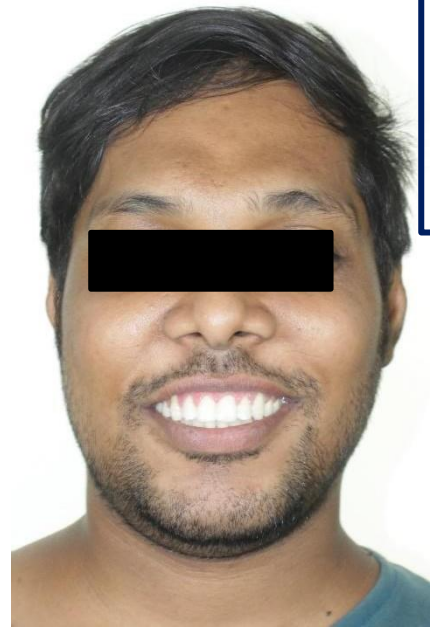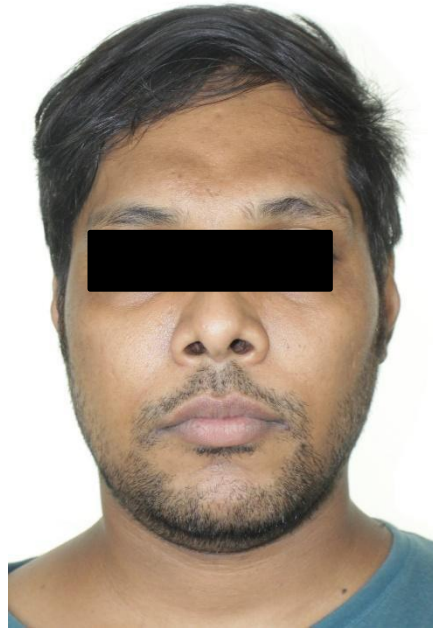AGE: 33 Years/M

OP No: 202112100045



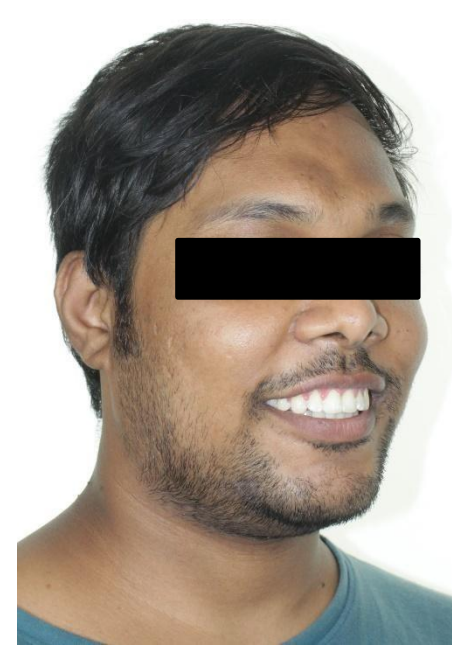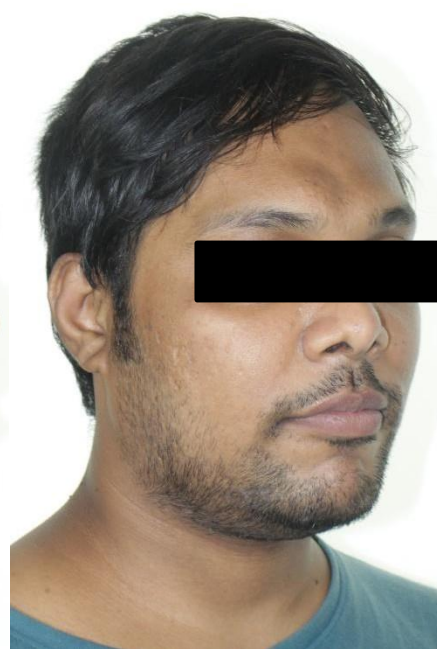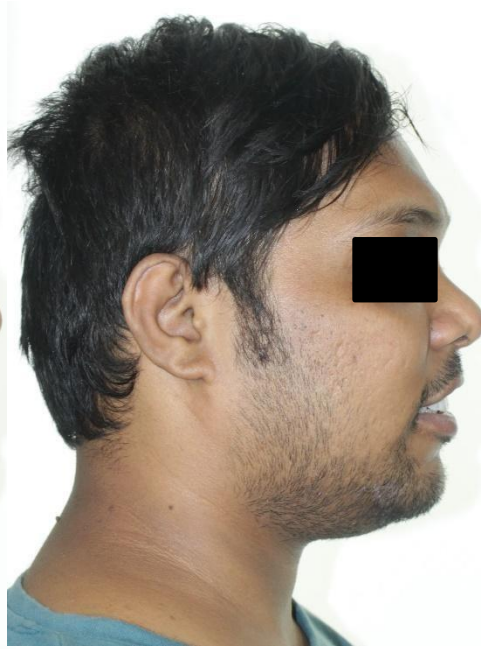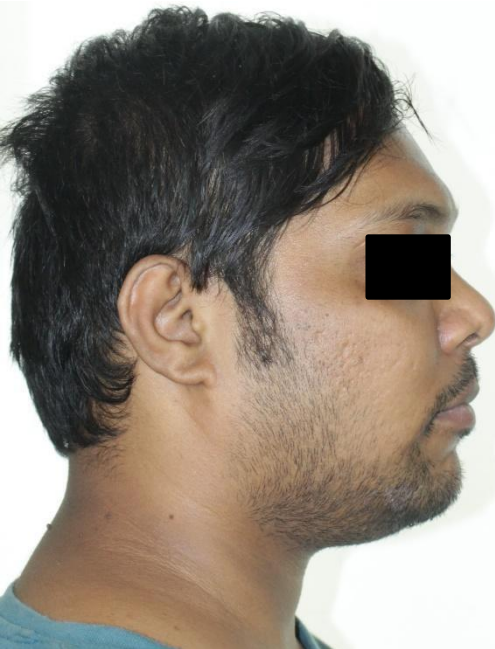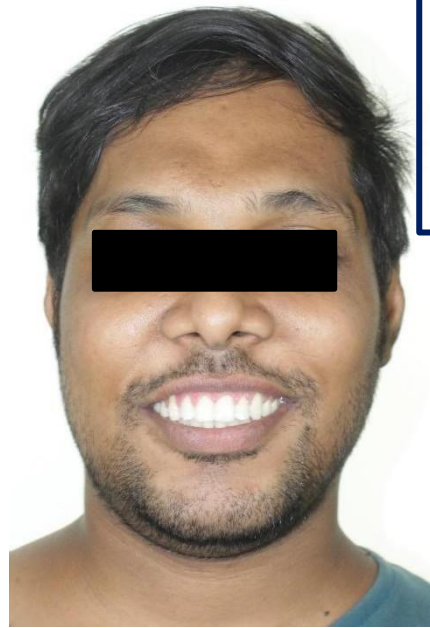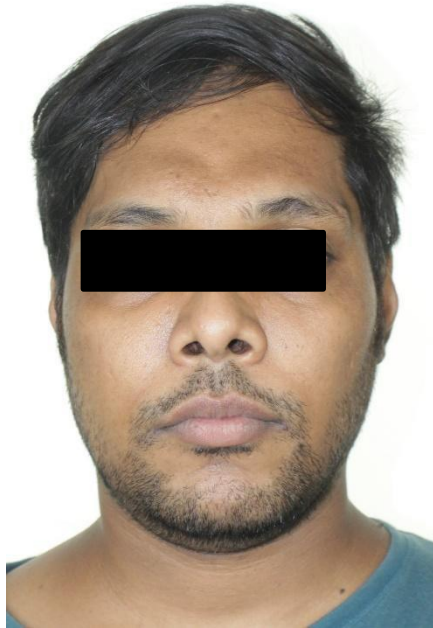EXTRA ORAL
POST DEBOND
PHOTOS

NAME: Imranuddin
AGE: 33 Years/M
OP No: 202112100045

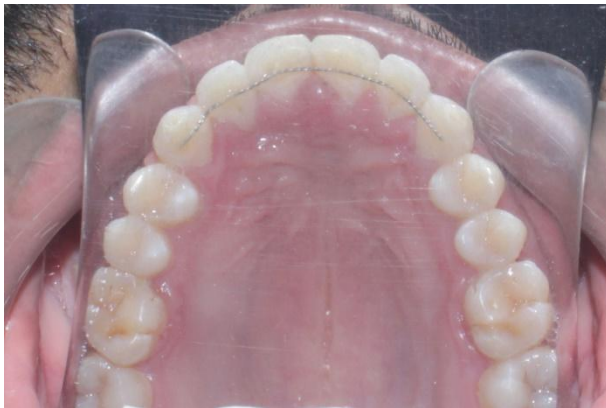

EXTRA ORAL
POST DEBOND
PHOTOS

NAME: Imranuddin
AGE: 33 Years/M
OP No: 202112100045



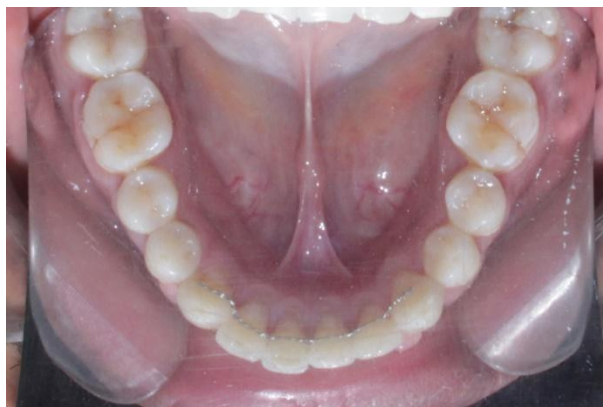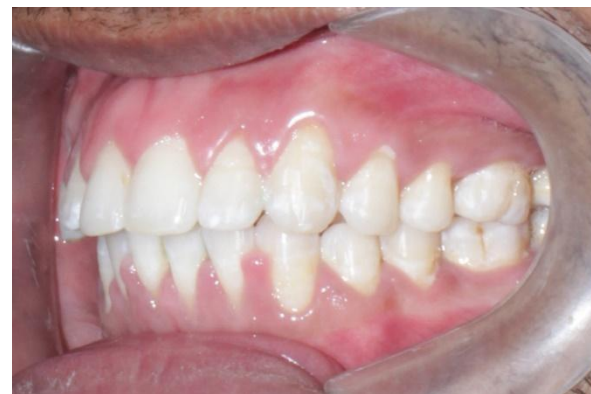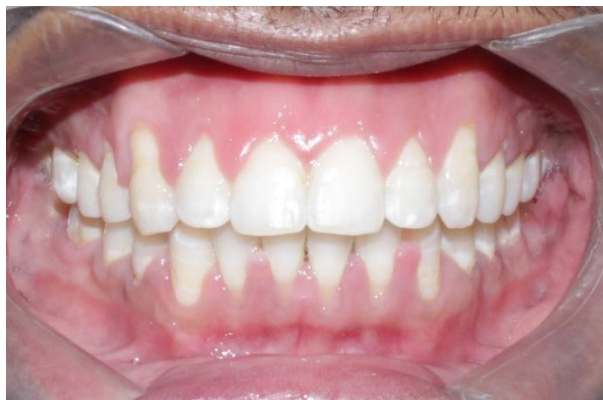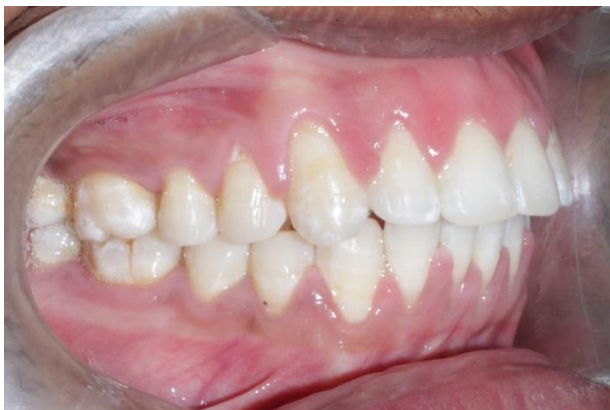**POST
DEBOND**



NAME: Imranuddin

AGE: 33 Years/M

OP No: 202112100045



CASE IX:

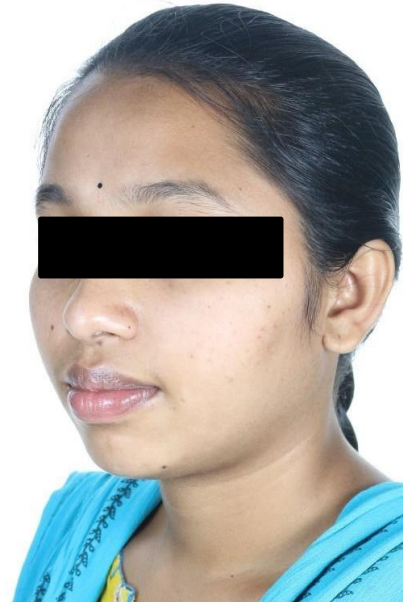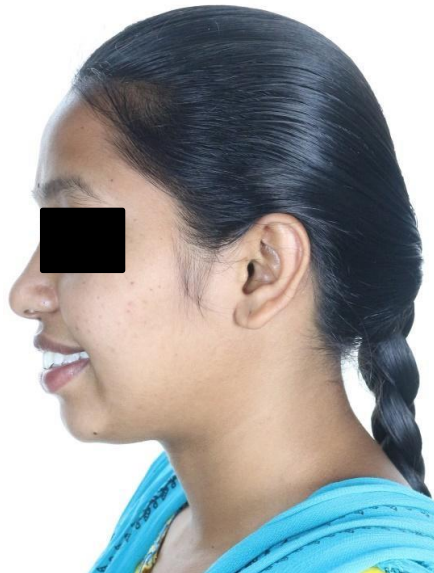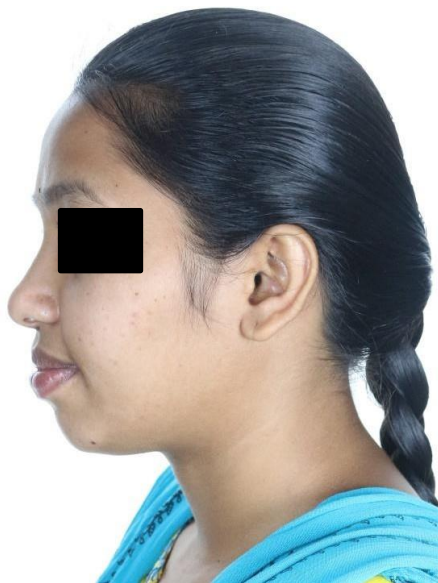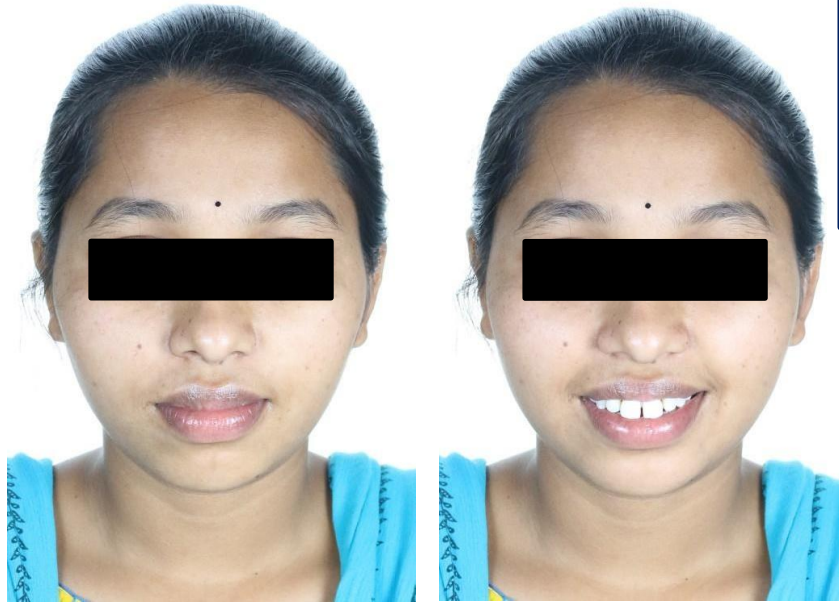NAME; Kavitha; AGE: 20YEARS/ FEMALE; OPNO: 202110120018

**DIAGNOSIS: ANGLES CLASS I MALOCCLUSION WITH BIMAXILLARY
PROTRUSION**

**TREATMENT PLAN : ALL FOUR 1ST PREMOLAR EXTRACTIONS AND
RETRACTION WITH LOOP MECHANICS**

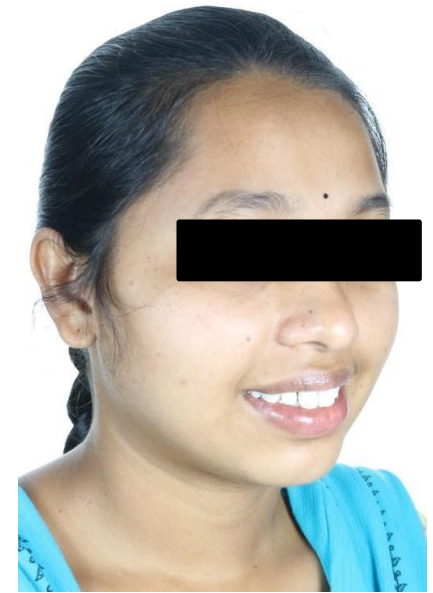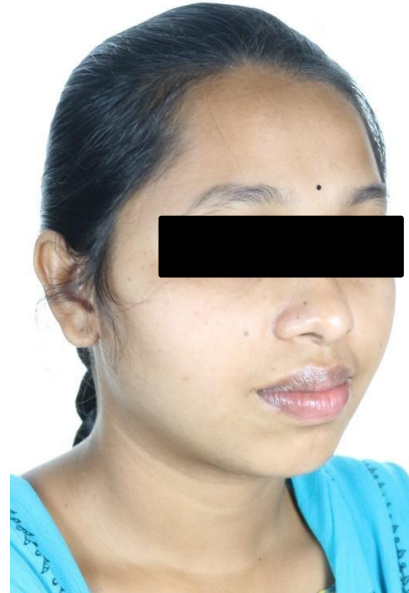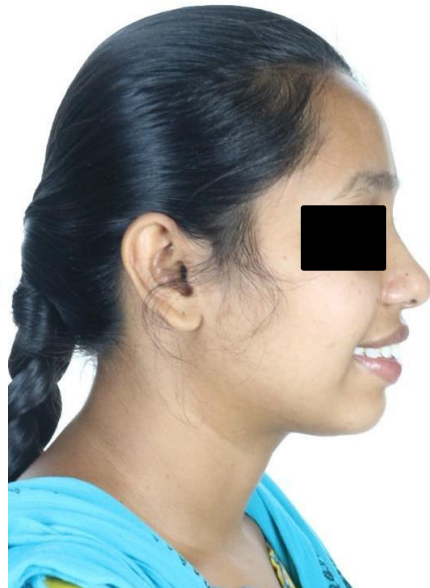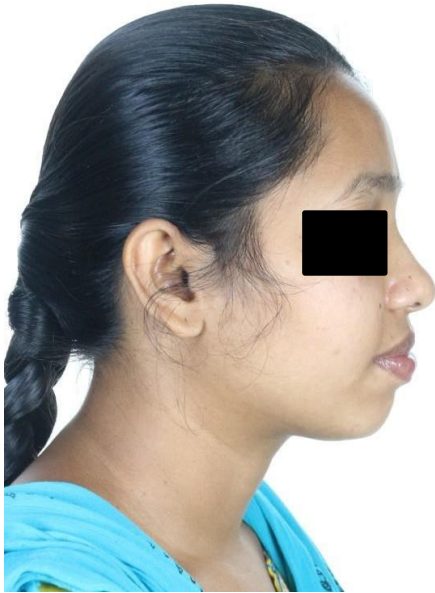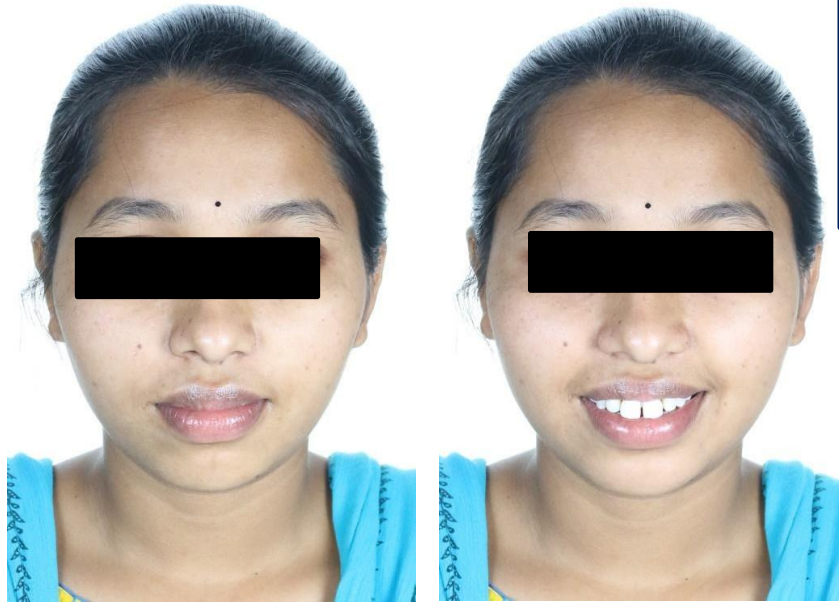EXTRA ORAL
PRE TREATMENT
PHOTOS

NAME: Kavitha
AGE: 20 Years/F
OP No: 202110120018

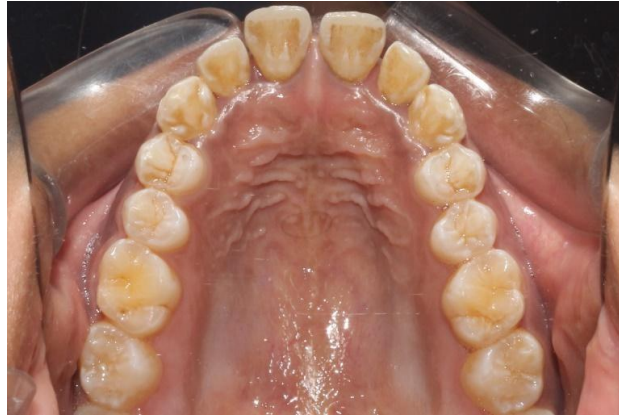

EXTRA ORAL
PRE TREATMENT
PHOTOS

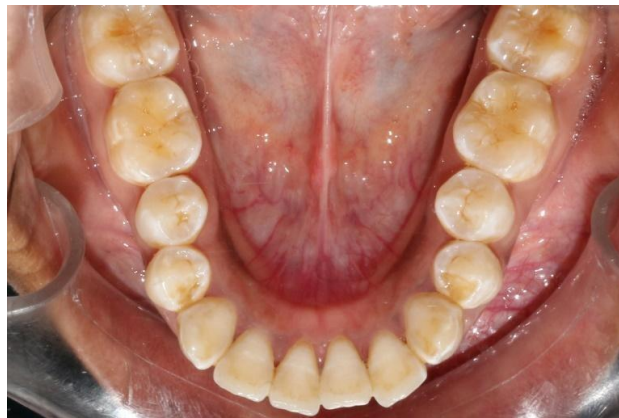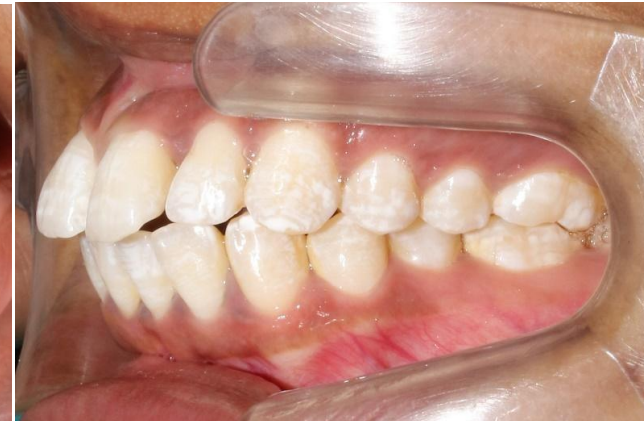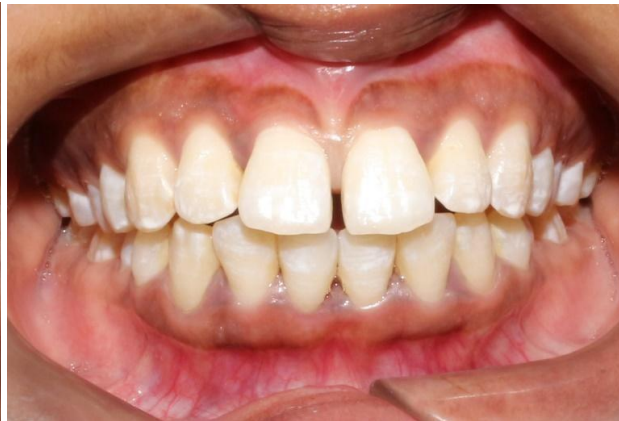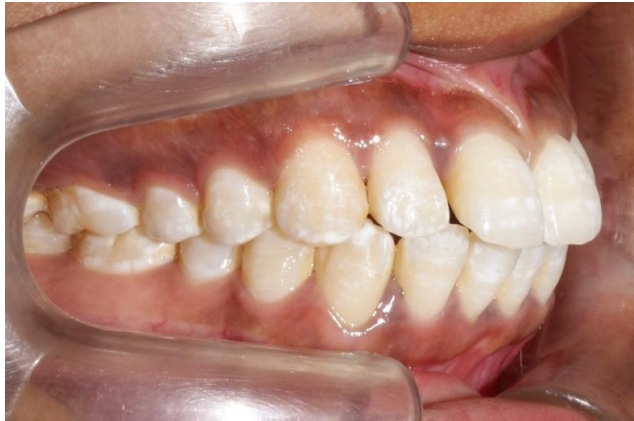NAME: Kavitha
AGE: 20 Years/F
OP No: 202110120018



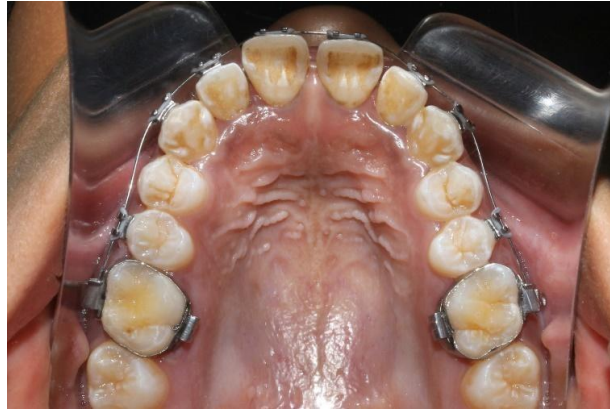INTRA ORAL
PRE TREATMENT
PHOTOS



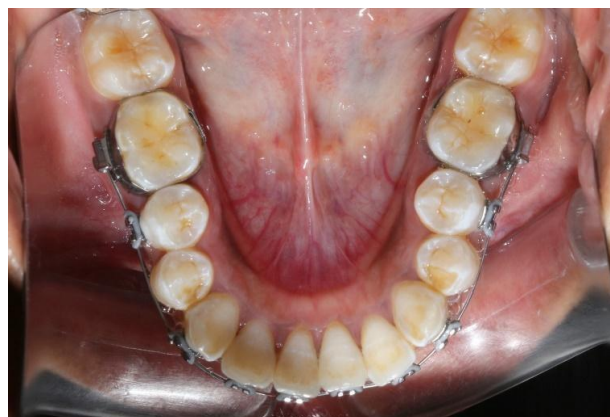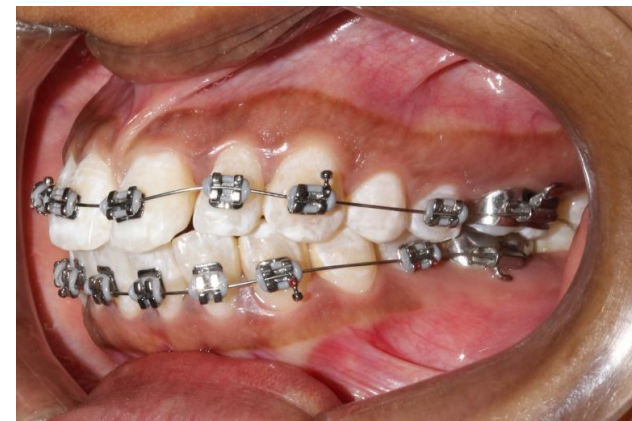
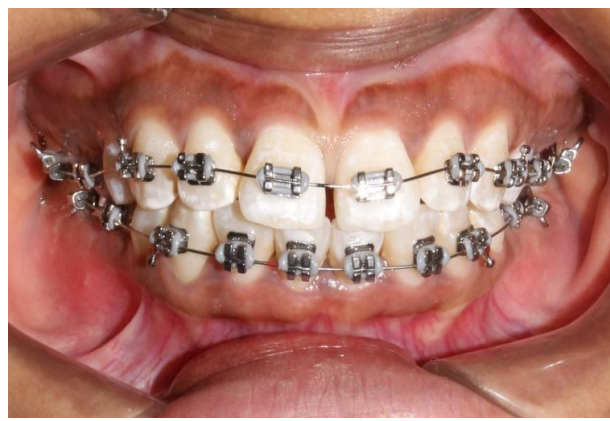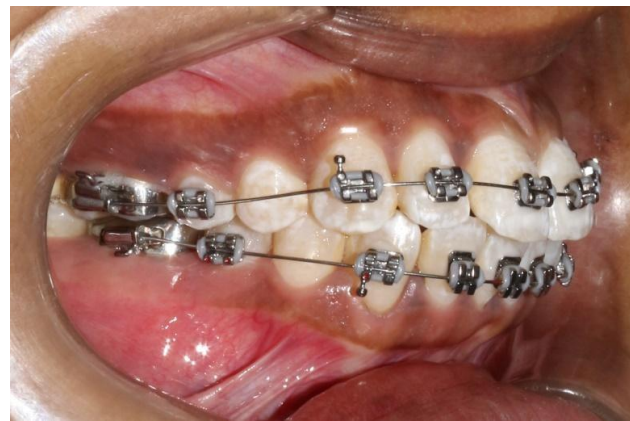NAME: Kavitha
AGE: 20 Years/F
OP No: 202110120018



STRAP UP



NAME: Kavitha
AGE: 20 Years/F
OP No: 202110120018

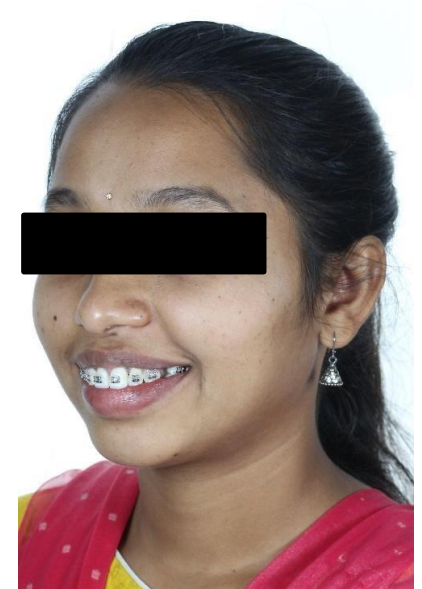
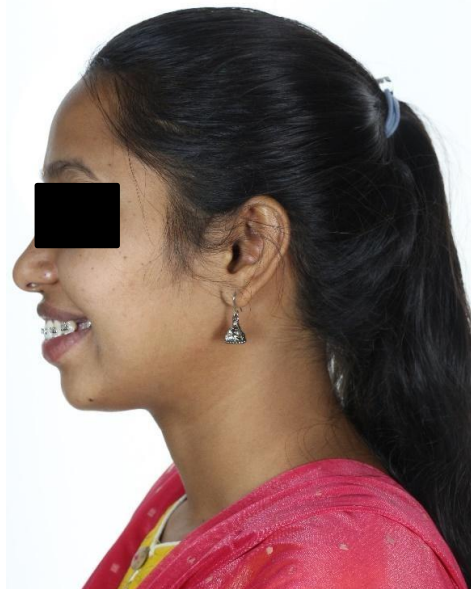
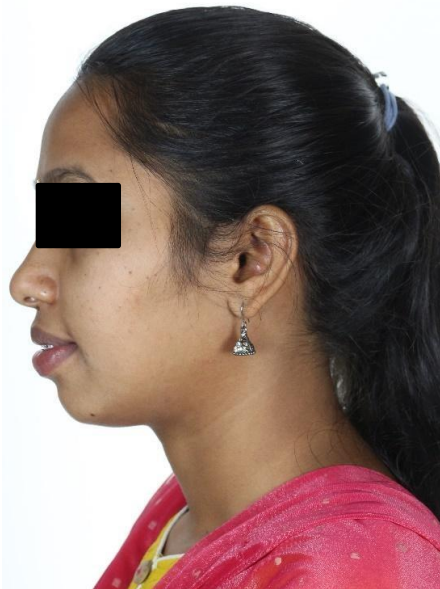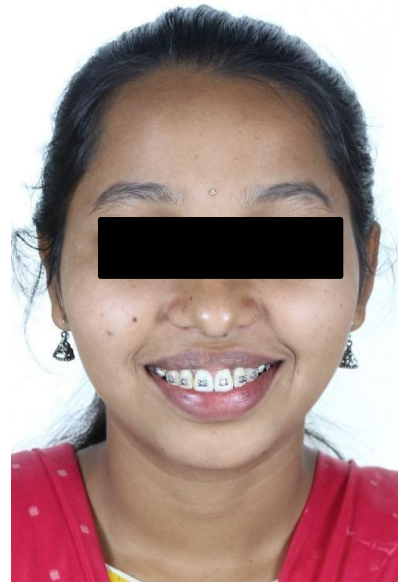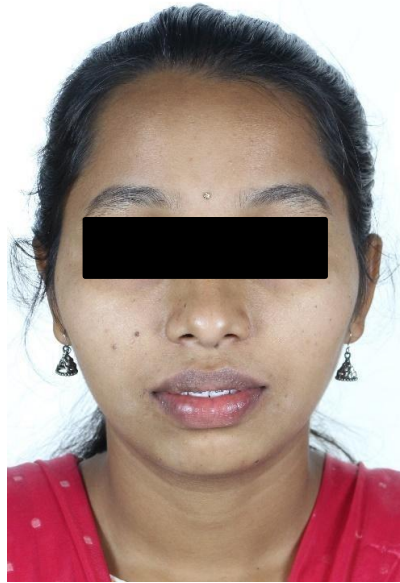**LEVELLING
AND
ALIGNING**

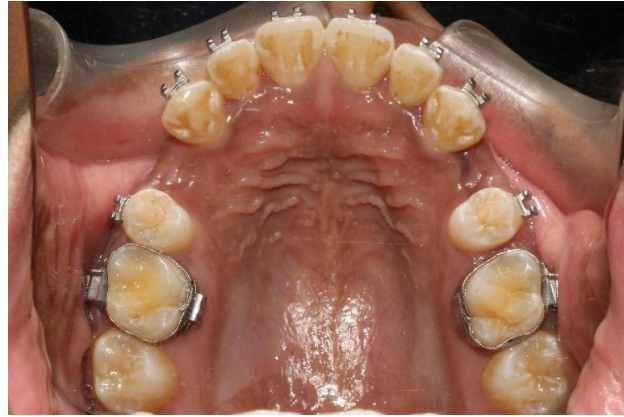NAME: Kavitha

AGE: 20 Years/F

OP No: 202110120018



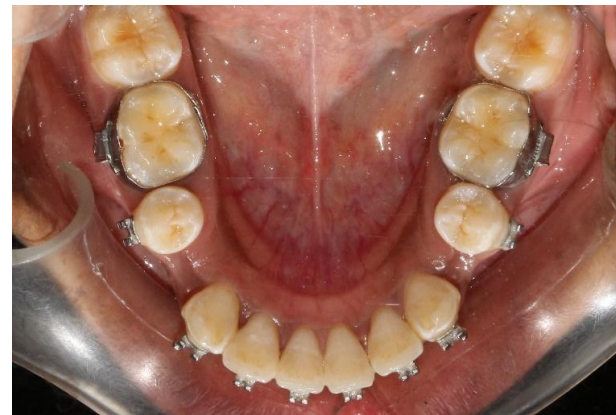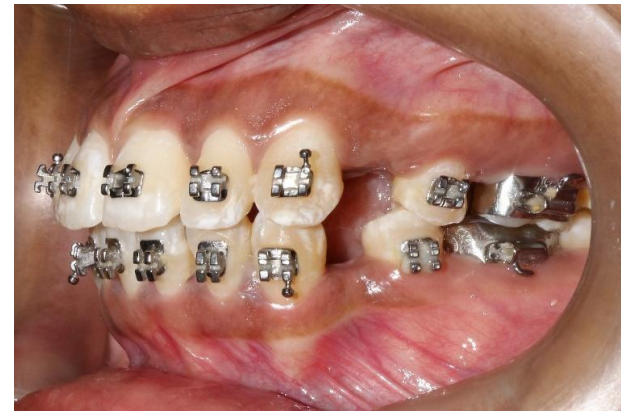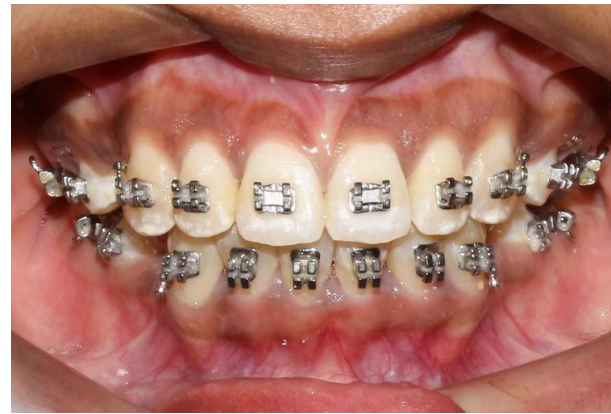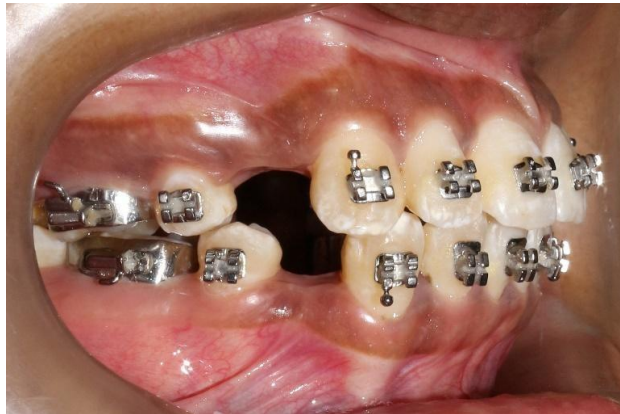**LEVELLING
AND
ALIGNING**



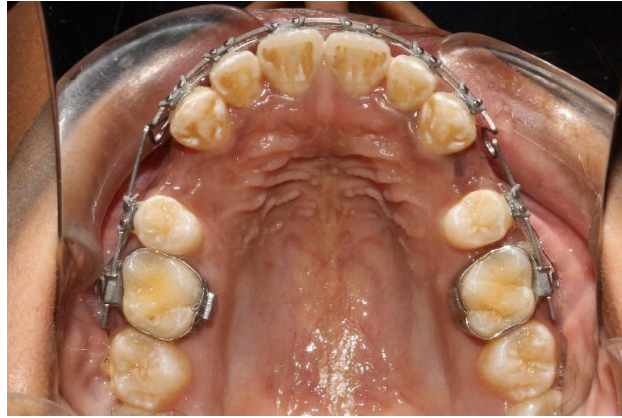
NAME: Kavitha

AGE: 20 Years/F

OP No: 202110120018



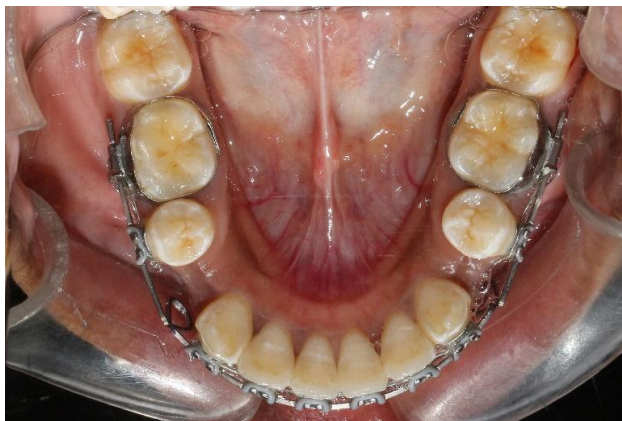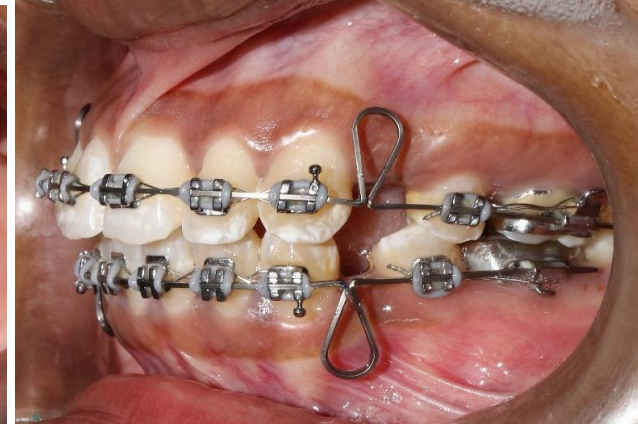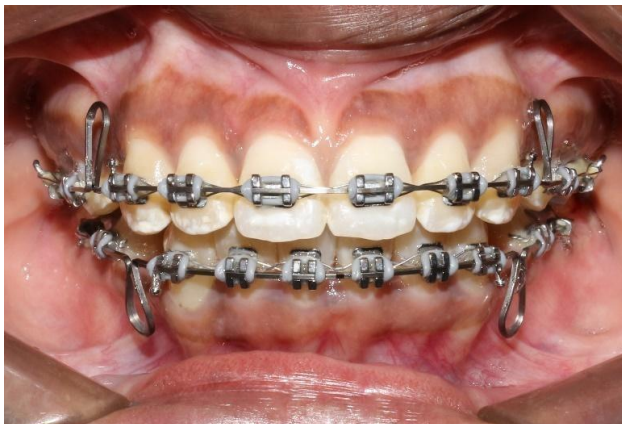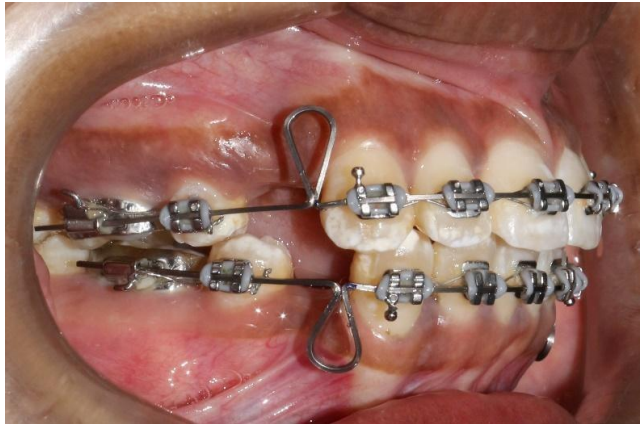
RETRACTION



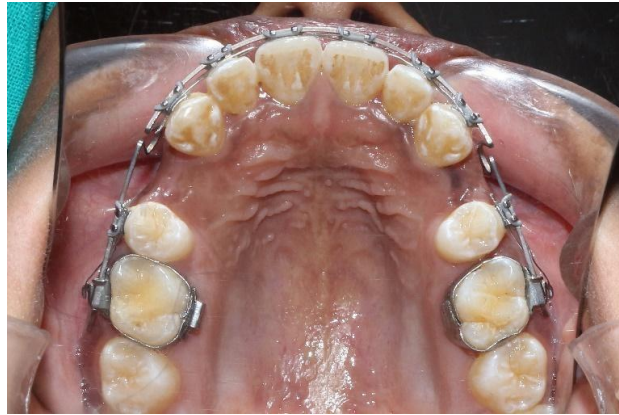NAME: Kavitha

AGE: 20 Years/F

OP No: 202110120018



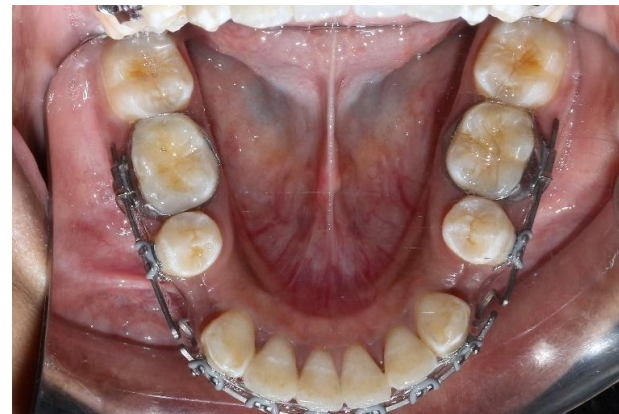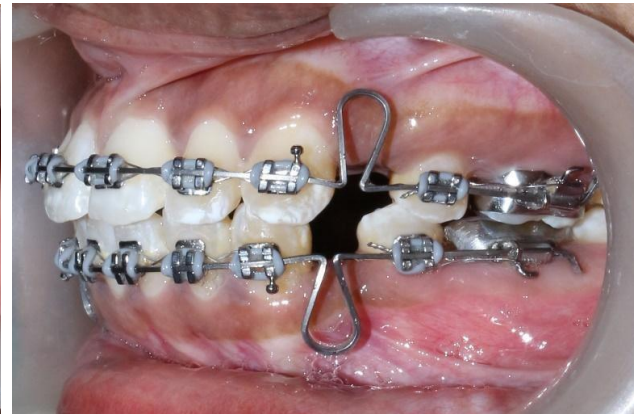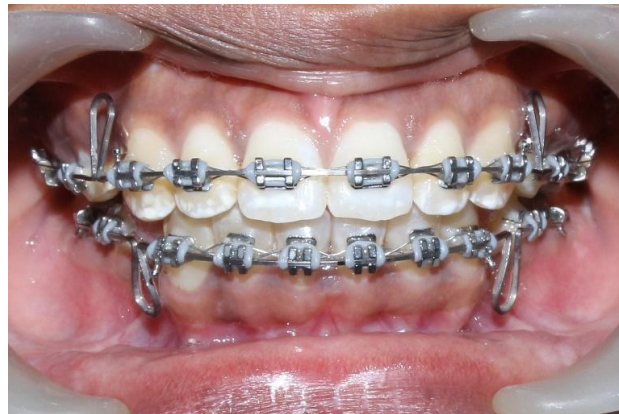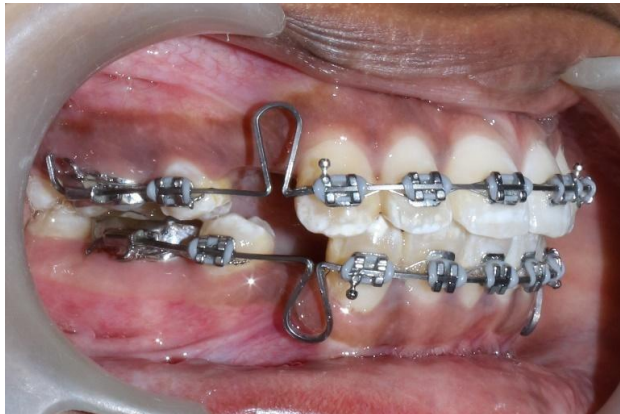LOOP ACTIVATION



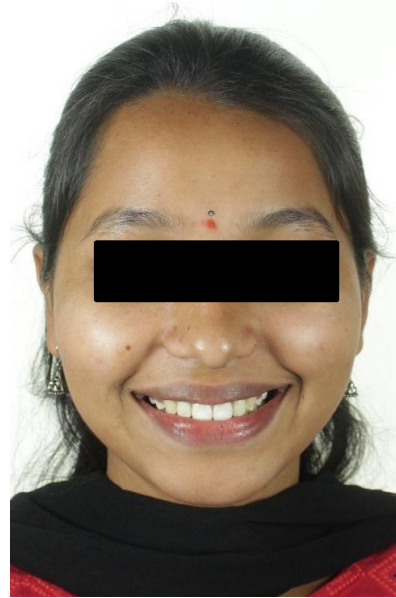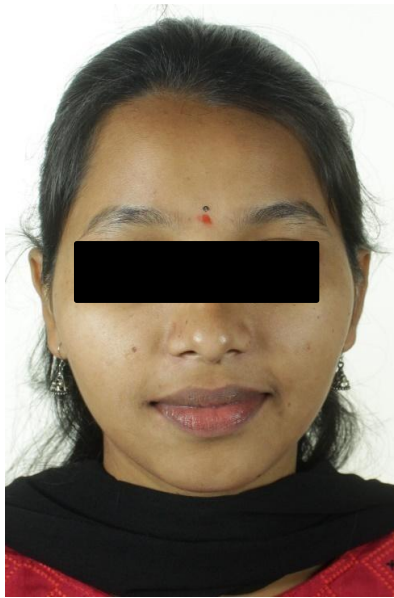NAME: Kavitha

AGE: 20 Years/F

OP No: 202110120018



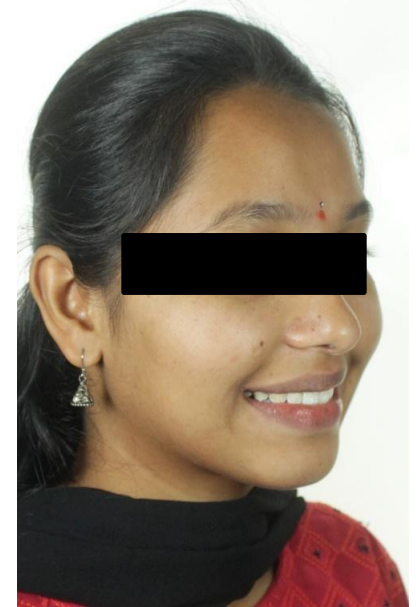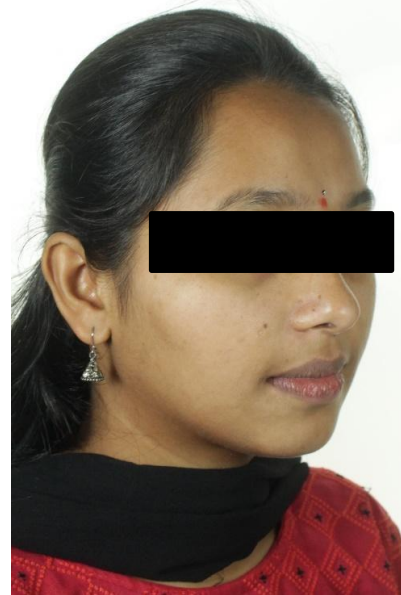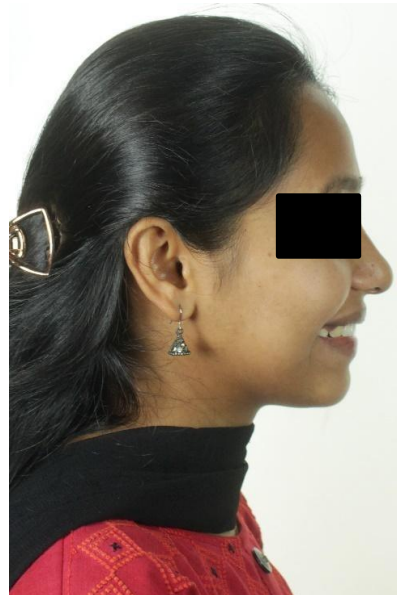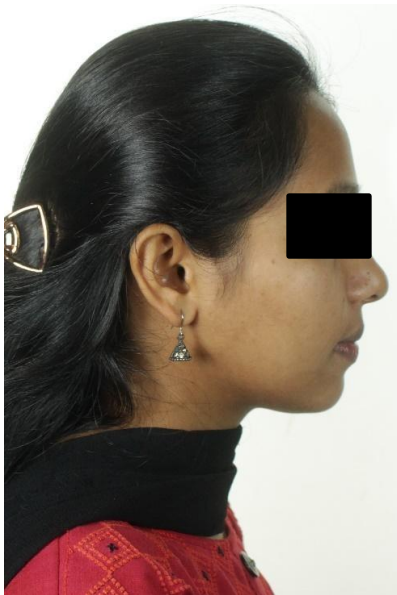POST DEBOND



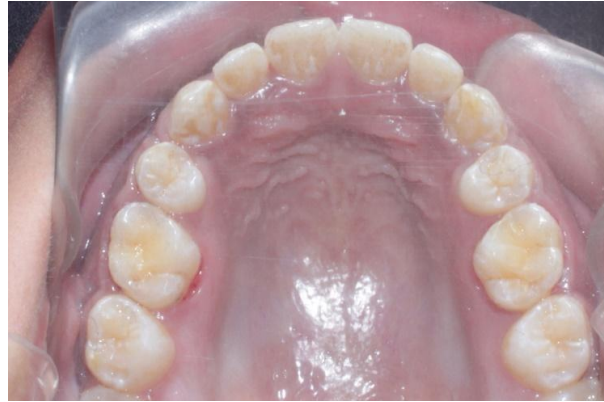NAME: Kavitha

AGE: 20 Years/F

OP No: 202110120018



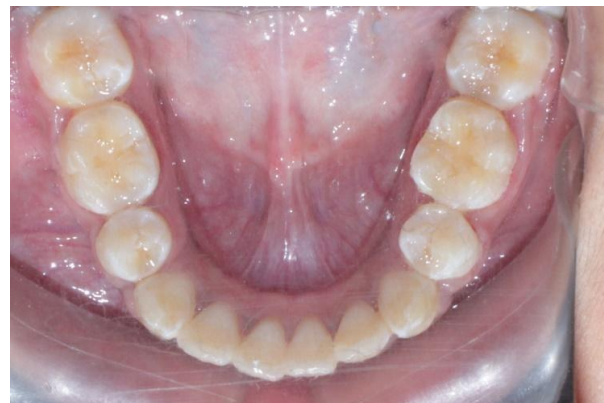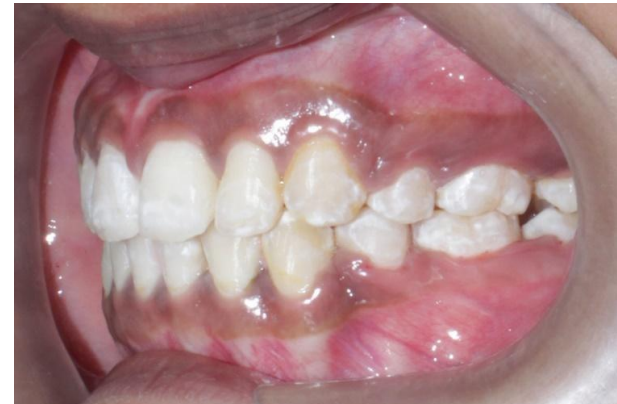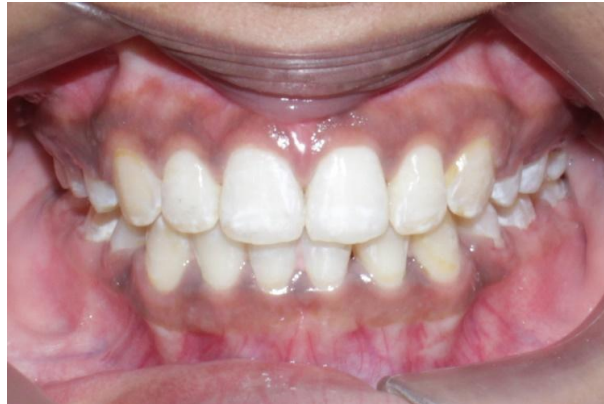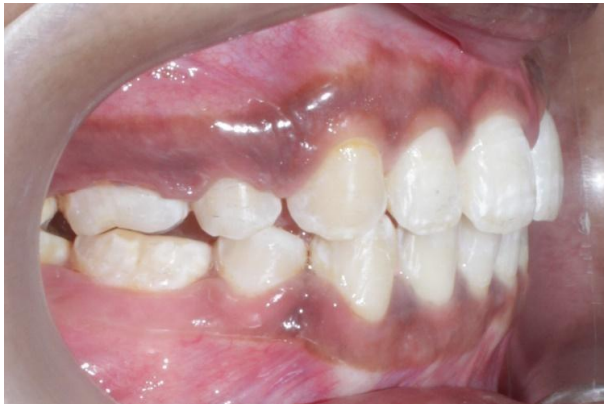**POST
DEBOND**



NAME: Kavitha

AGE: 20 Years/F

OP No: 202110120018



CASE X:

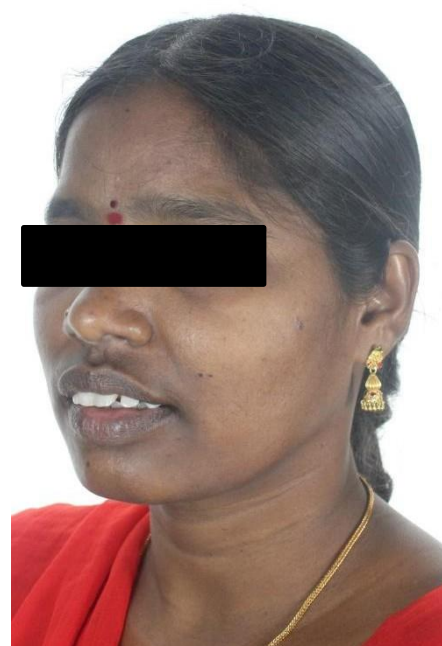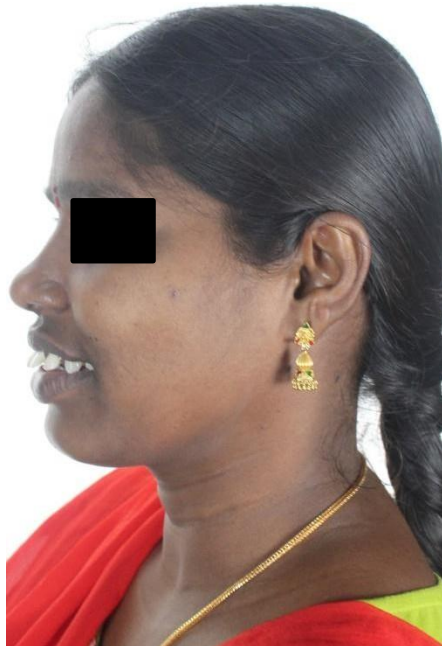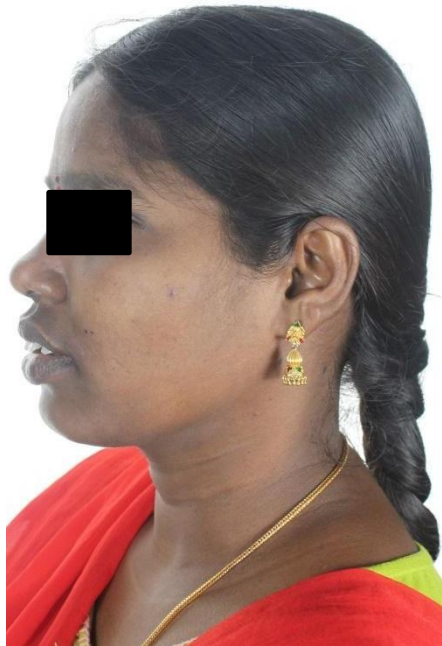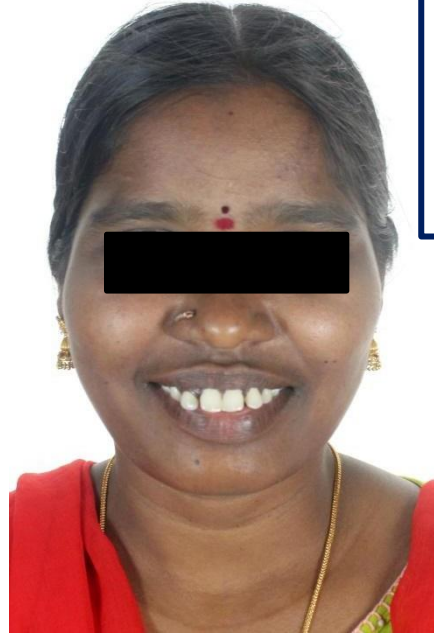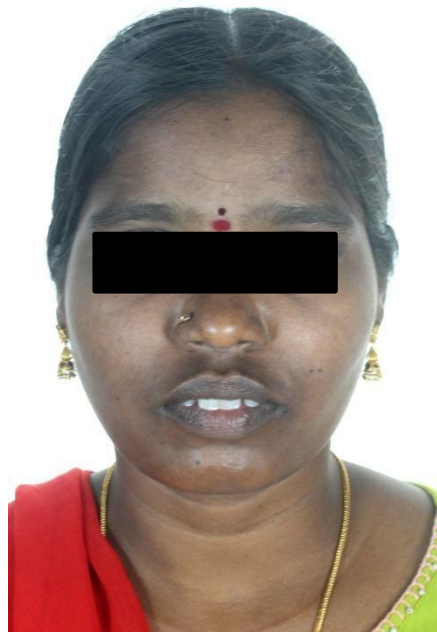NAME; SRI VANI; AGE: 32YEARS/ FEMALE; OPNO: 202111290072

**DIAGNOSIS: ANGLES CLASS I MALOCCLUSION WITH
BIMAXILLARY PROTRUSION**

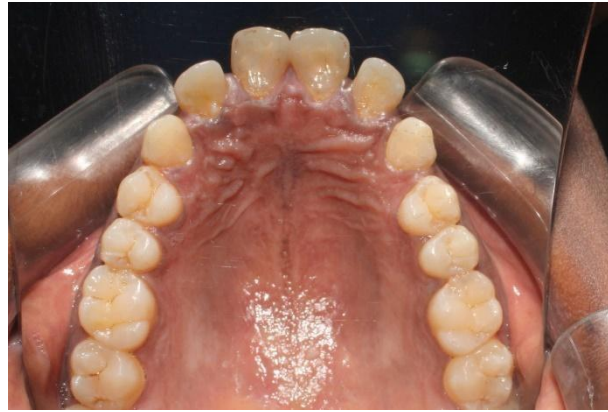**TREATMENT PLAN :NON EXTRACTION TREATMENT PLAN
WITH ADULT ORTHODONTICS**

**EXTRA ORAL
PRE TREATMENT
PHOTOS**

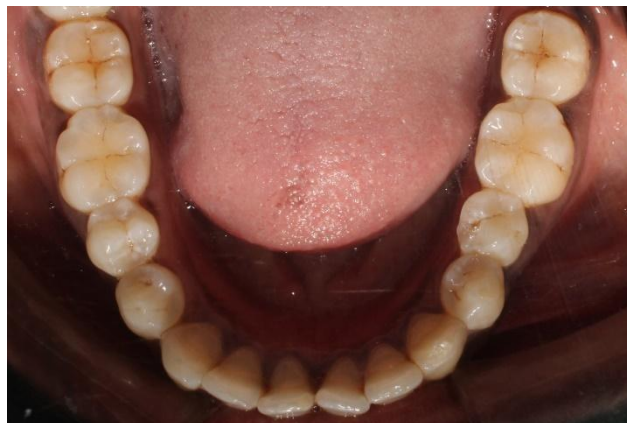
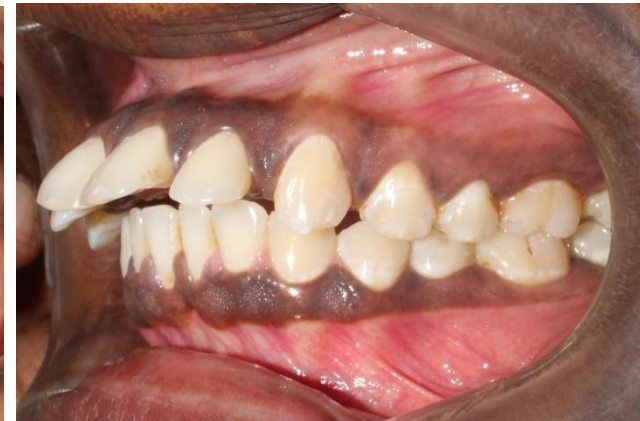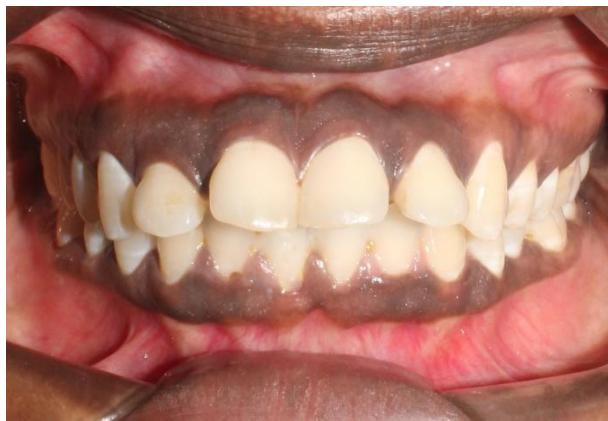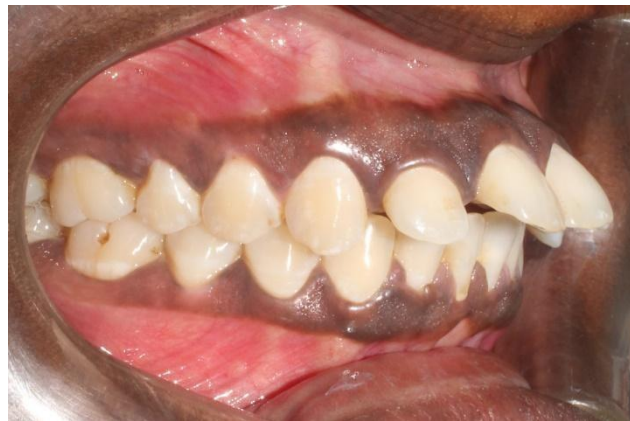NAME: Srivani
AGE: 32 Years/F
OP No: 202111290072



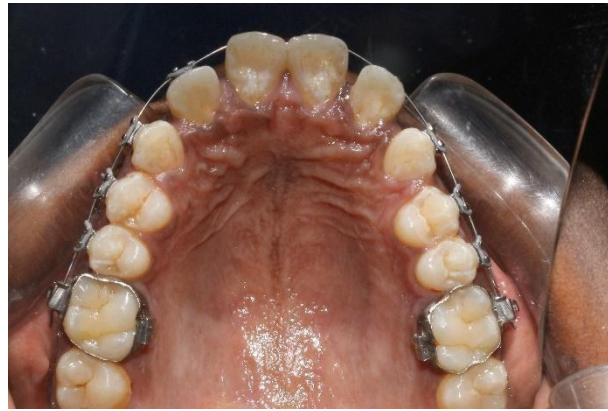INTRA ORAL
PRE TREATMENT
PHOTOS



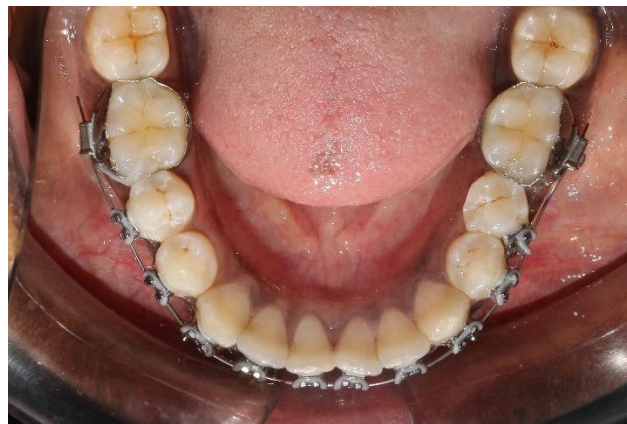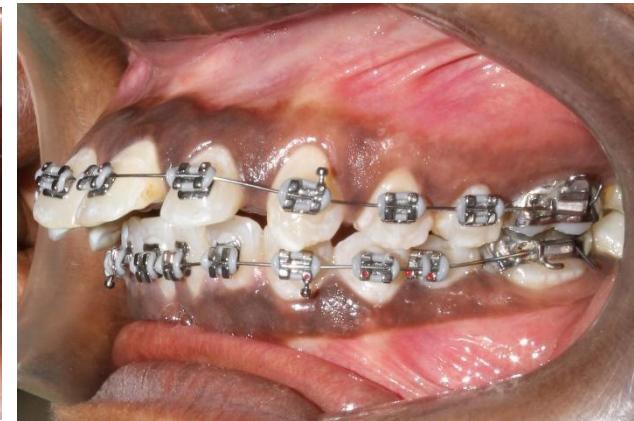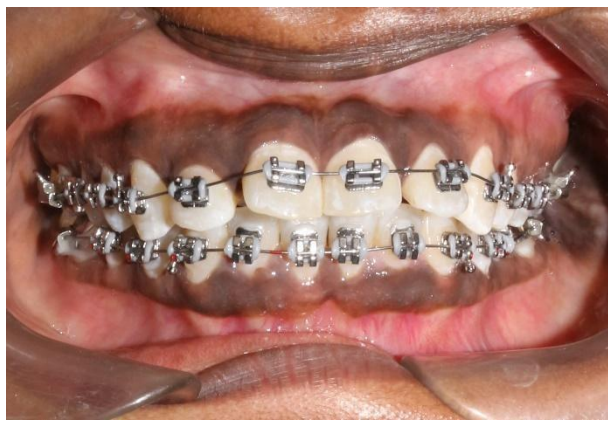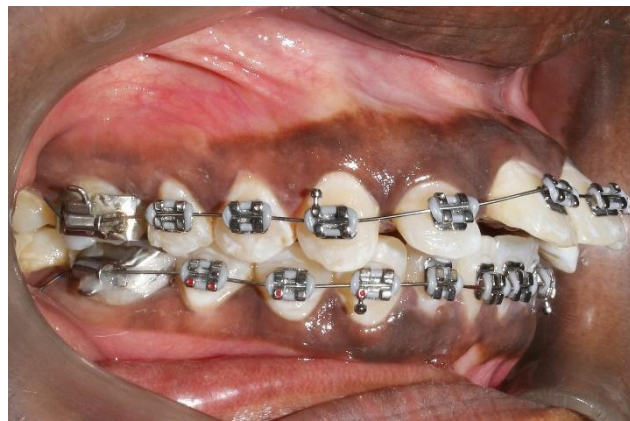
NAME: Srivani
AGE: 32 Years/F
OP No: 202111290072



STRAP UP

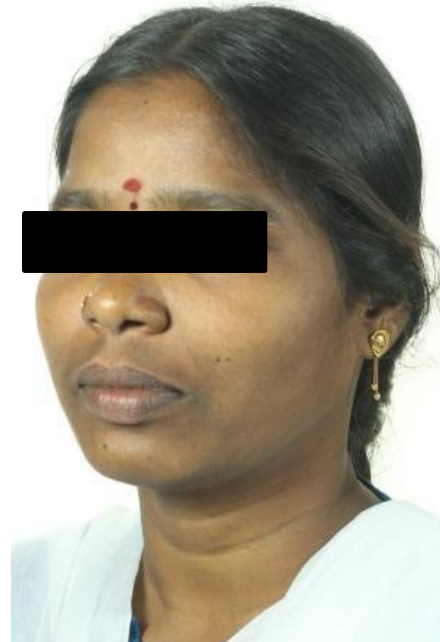
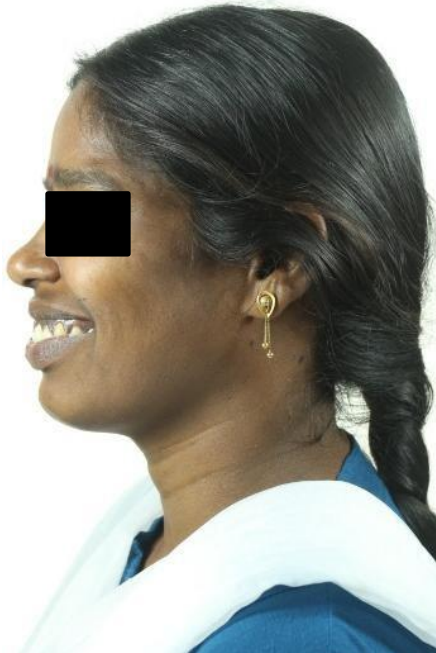
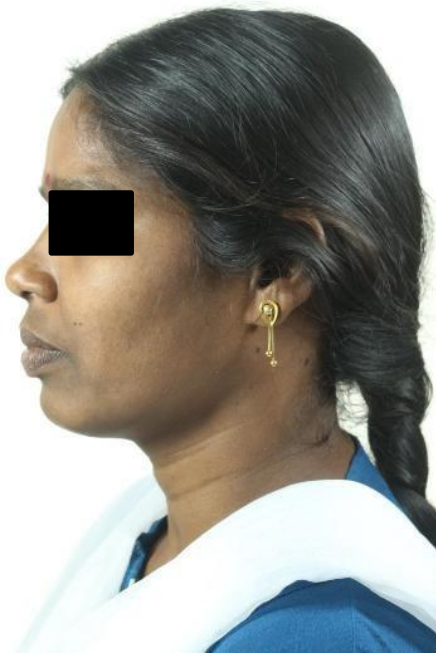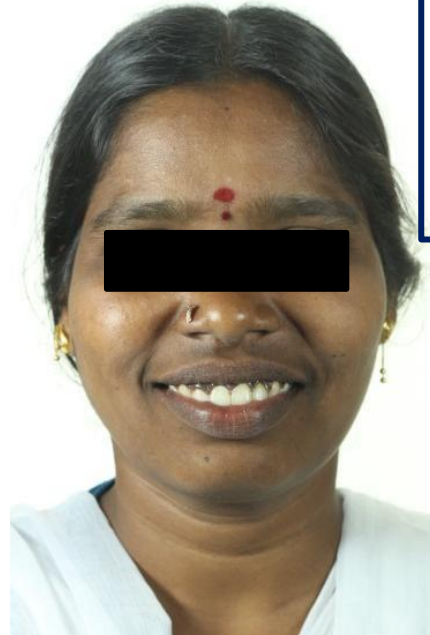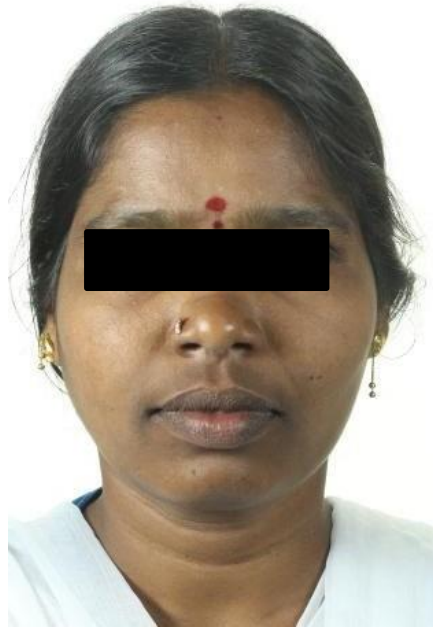NAME: Srivani
AGE: 32 Years/F
OP No: 202111290072

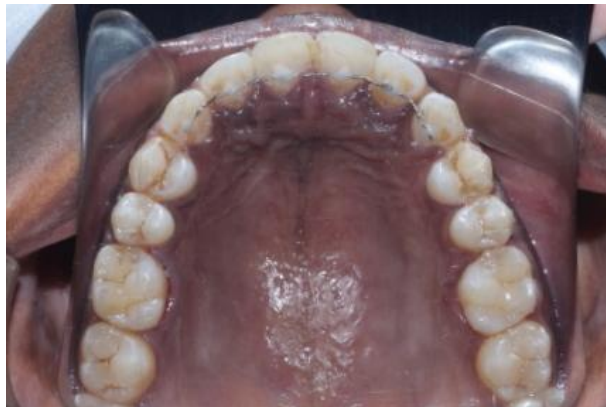

EXTRA ORAL
POST DEBOND
PHOTOS

NAME: Srivani
AGE: 32 Years/F
OP No: 202111290072



POST DEBOND



NAME: Srivani
AGE: 32 Years/F
OP No: 202111290072

