

**NAME : NITHYA**

**AGE/SEX: 3 MONTHS/F**

**IP.NO- 20241206011**

**DATE- 06/12/24**

**DIAGNOSIS: CLEFT LIP**

**TREATMENT: PRESURGICAL NASOALVEOLAR MOULDING**

**ASSISTANT SURGEONS : DR. ASMA, DR. ANUPRIYA, DR. NEELIMA**

**PREOPERATIVE PICTURES**



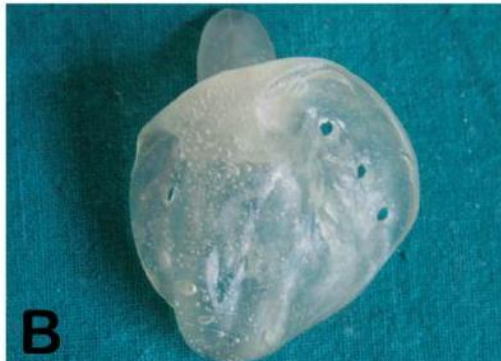**A**

**IMPRESSION**



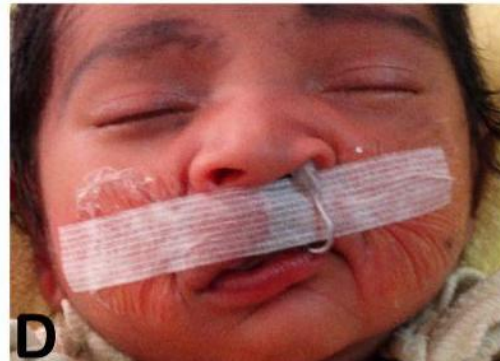**C**

**APPLIANCE**



**B**

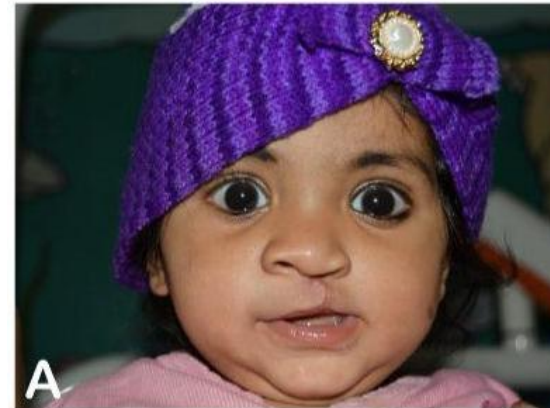**OBTURATOR**



**D**

**FIXATION**

**POST OPERATIVE PICTURES**



**A**

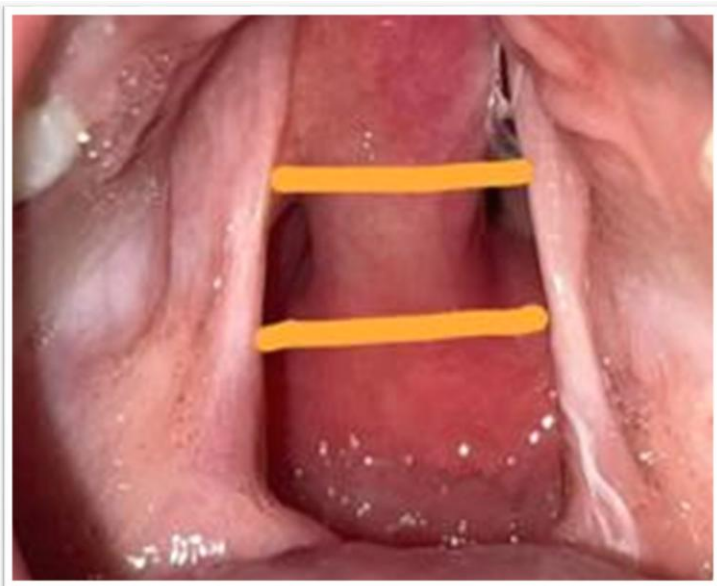


**B**

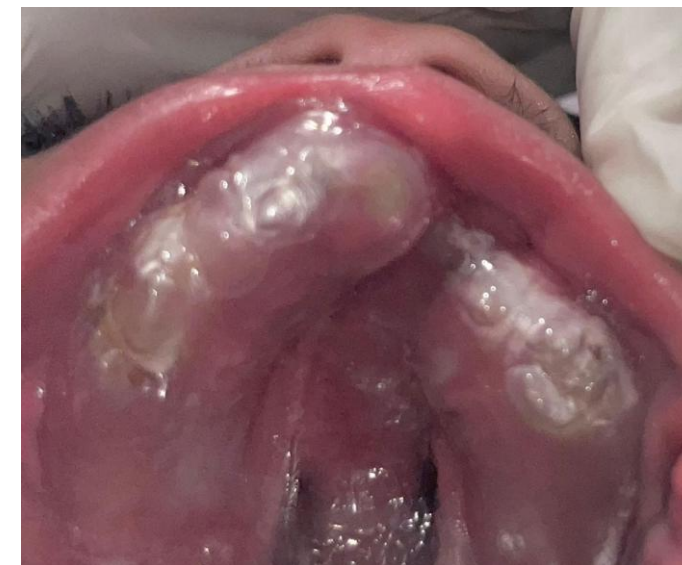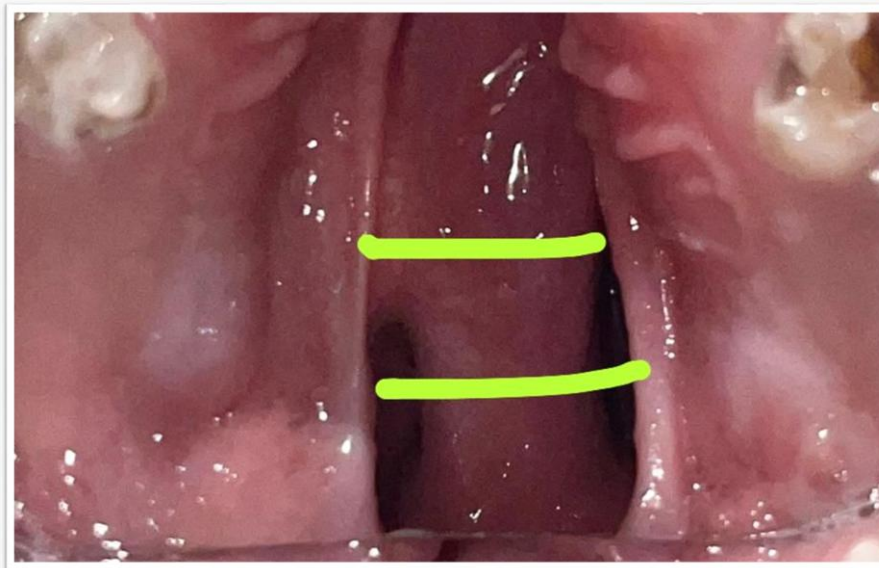
**AFTER MOULDING AND POST SURGERY FOLLOW UP**

**NAME - RIYANKSHIKA AGE/SEX – 23 MONTHS/F DATE- 28/01/26 DIAGNOSIS- CLEFT PALATE**  
**TREATMENT – CLEAR ALIGNER THERAPY FOR CLEFTT CONTRACTION .**  
**ASSISTANT SURGEONS – Dr. DR. VAISHNAVI, DR. SRINIDHI, DR. SHEELA**

**PREOPERATIVE PHOTOGRAPHS**



**POST OPERATIVE PHOTOGRAPHS**

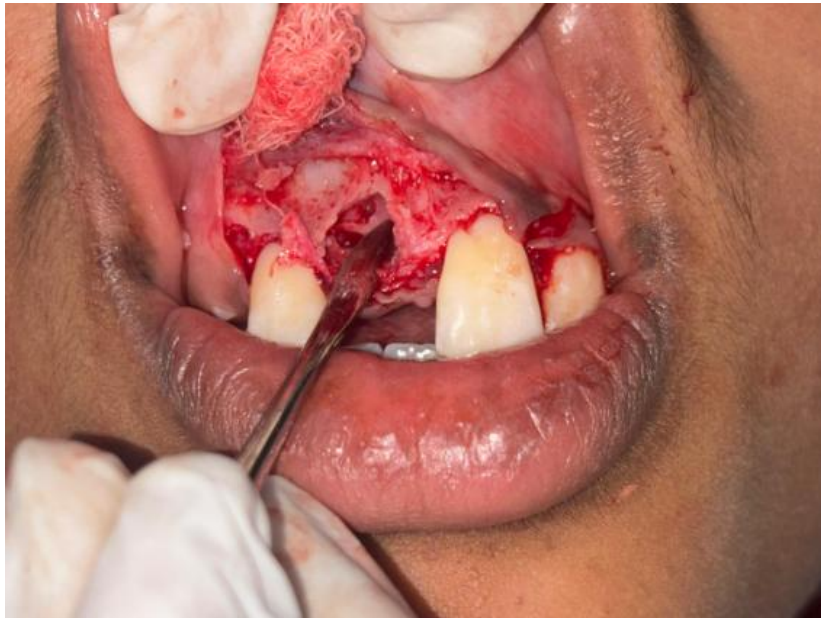

Mid-Palatal : 10 mm Posterior: 11mm

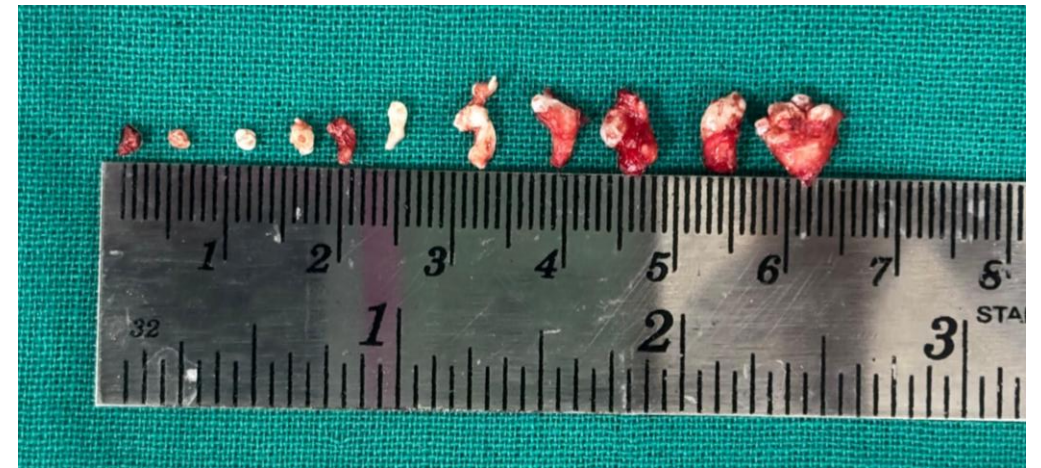**NAME - AKHILESH      AGE/SEX – 09/M   IP.NO- 202507110101   DATE- 16.07.2025**  
**DIAGNOSIS- COMPOUND ODONTOME   TREATMENT – SURGICAL EXCISION**  
**SURGEONS – Dr. SRINIVAS N CH ; ASSISTANT SURGEONS – DR. SUPREETHI, DR. KARUNYA, DR. SINDHUJA**

## **INTRAOPERATIVE PICTURES**

**SURGICAL ENUCLEATION OF  
COMPOUND ODONTOMA VIA A BUCCAL  
WINDOW APPROACH**

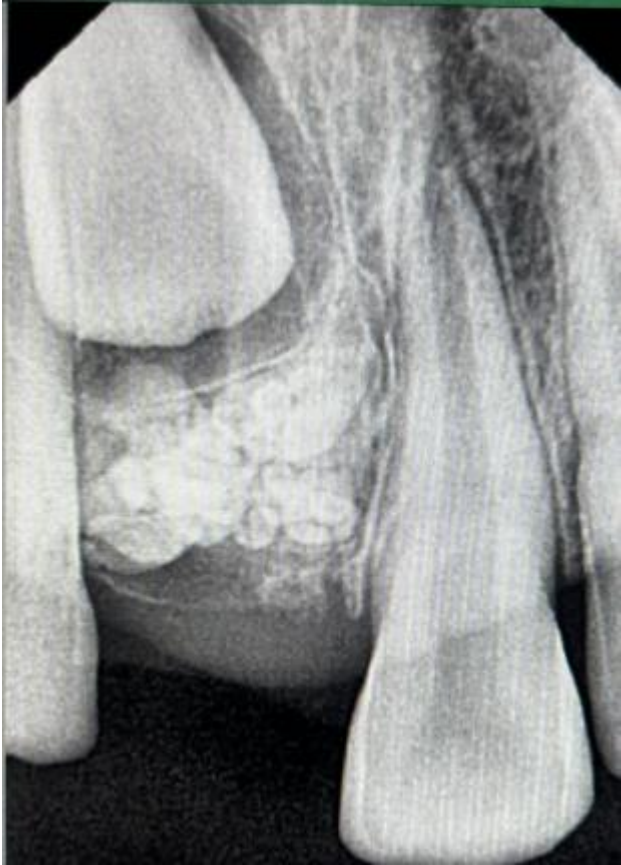


**MULTIPLE TOOTH-LIKE STRUCTURES  
CHARACTERISTIC OF A COMPOUND ODONTOMA  
RETRIEVED FOLLOWING ENUCLEATION**

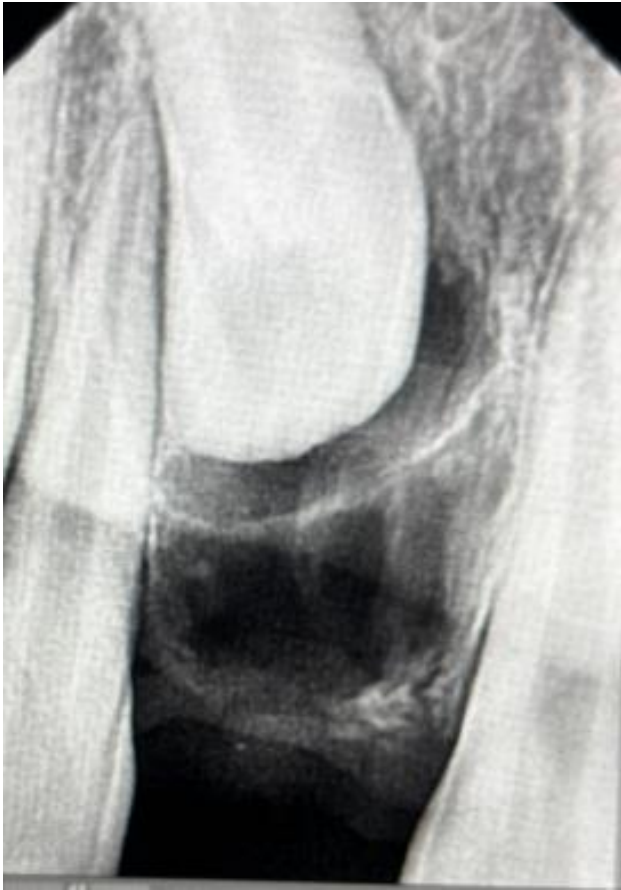

# RADIOGRAPHIC IMAGE (IOPA)

PREOPERATIVE RADIOGRAPH



POSTOPERATIVE RADIOGRAPH



**NAME - TEJA**

**AGE/SEX - 7Y/M**

**IP.NO-1666/260203**

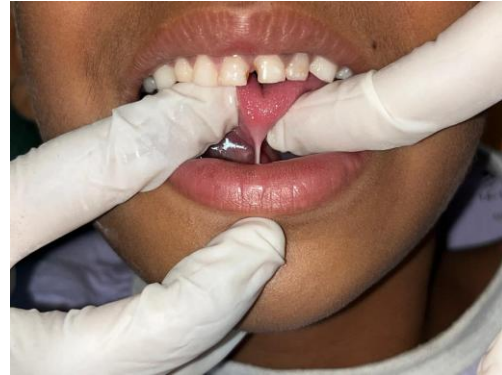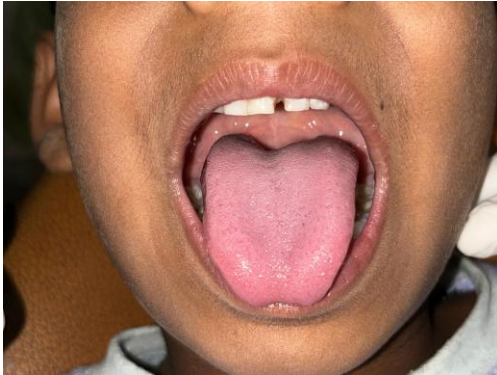**DATE-26/02/26**

**DIAGNOSIS- ANKYLOGLOSSIA**

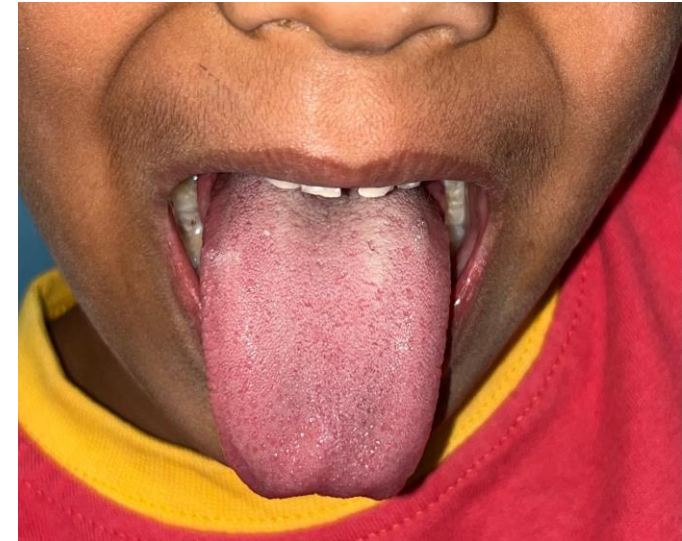**TREATMENT – LASER ASSISTED LINGUAL FRENECTOMY**

**SURGEONS – Dr. SRINIVAS N CH ; ASSISTANT SURGEONS – DR. VAISHNAVI, DR. SRINIDHI**

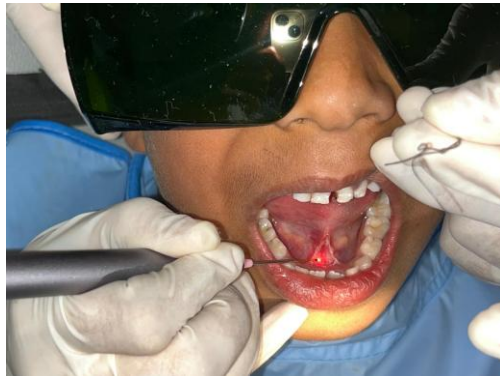### PREOPERATIVE PHOTOGRAPHS



### POST OPERATIVE PHOTOGRAPH



### INTRA OPERATIVE



**NAME :** VIGNESH    **AGE/SEX:** 11/M    **IP.NO-**1670/260301    **DATE-**04/03/26

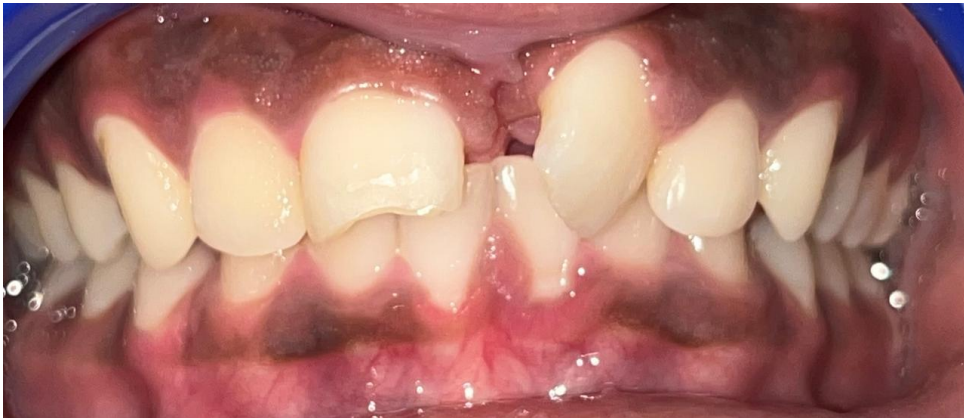**DIAGNOSIS:** ANGLE CLASS 1 MALOCCLUSION WITH ROTATED 21

**TREATMENT:** CORRECTION OF ROTATED 21 USING 2X4 APPLIANCE

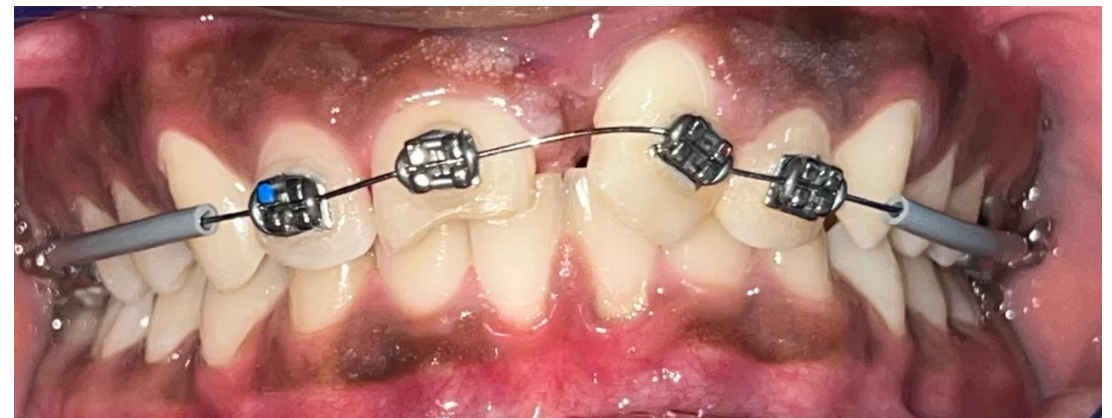
**SURGEONS:** Dr. SRINIVAS N CH

**ASSISTED SURGEONS :** DR. ASMA, DR. NEELIMA

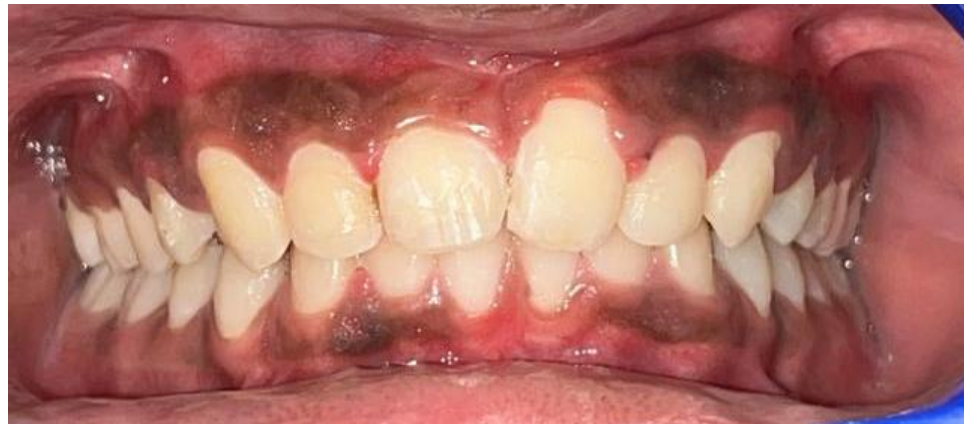**PREOPERATIVE PICTURES**



**INTRA OPERATIVE PICTURES**



**POSTOPERATIVE PICTURES**



**NAME :** VIGNESH    **AGE/SEX:** 11/M    **IP.NO-**1670/260301    **DATE-**04/03/26

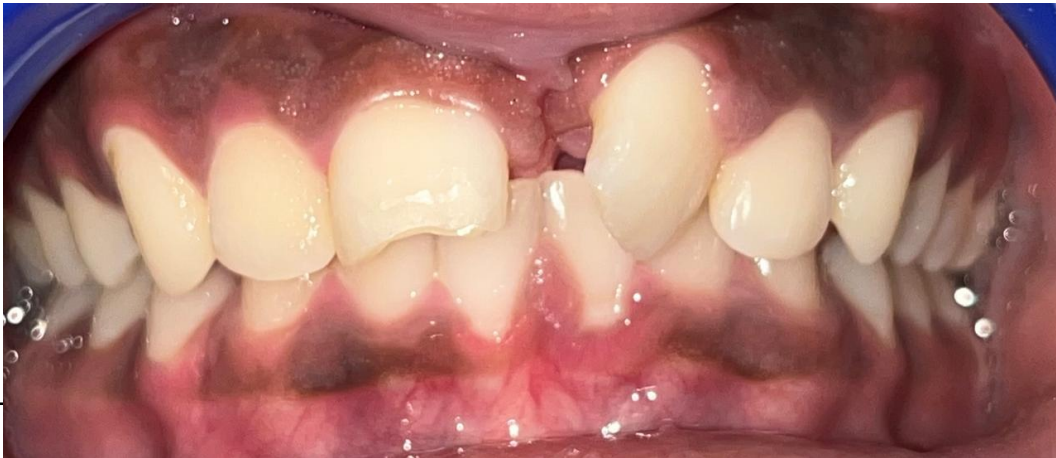**DIAGNOSIS:** ANGLE CLASS 1 MALOCCLUSION WITH ROTATED 21

**TREATMENT:** CORRECTION OF ROTATED 21 USING 2X4 APPLIANCE

**SURGEONS:** Dr. SRINIVAS N CH

**ASSISTED SURGEONS :** DR. ASMA, DR. NEELIMA

**PREOPERATIVE PICTURES**



**INTRA OPERATIVE PICTURES**

