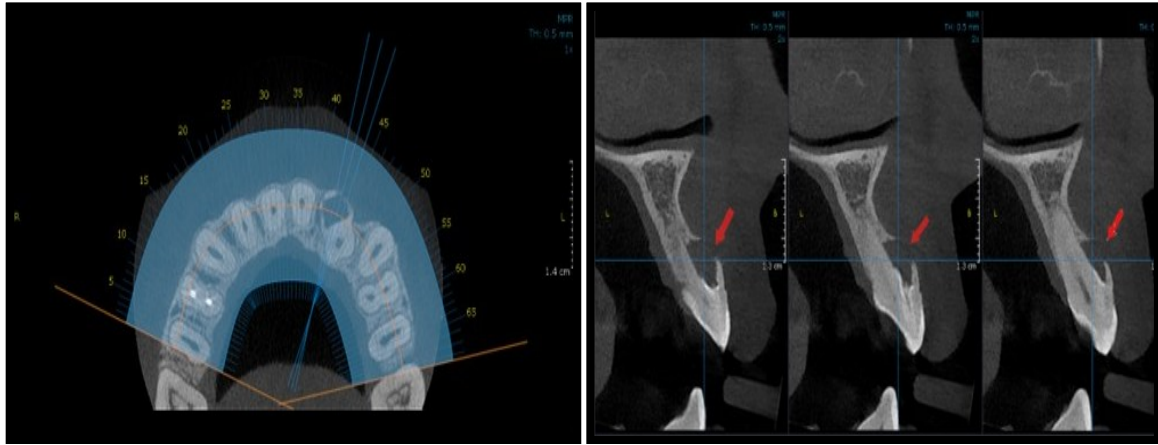
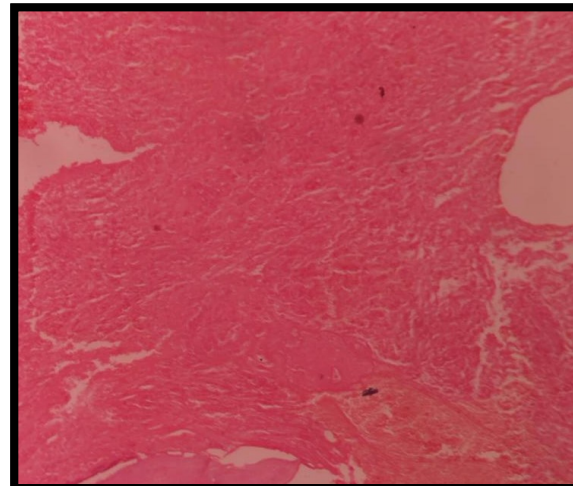
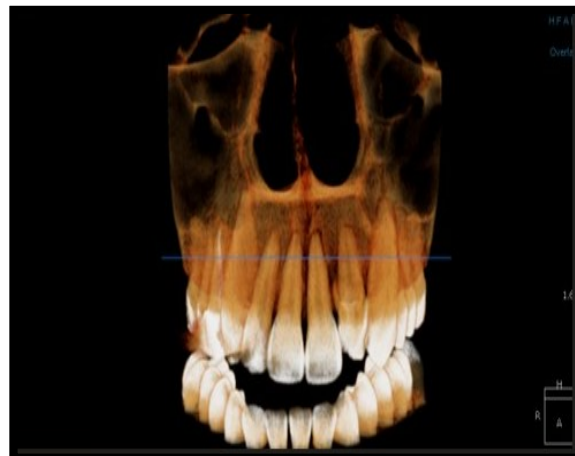
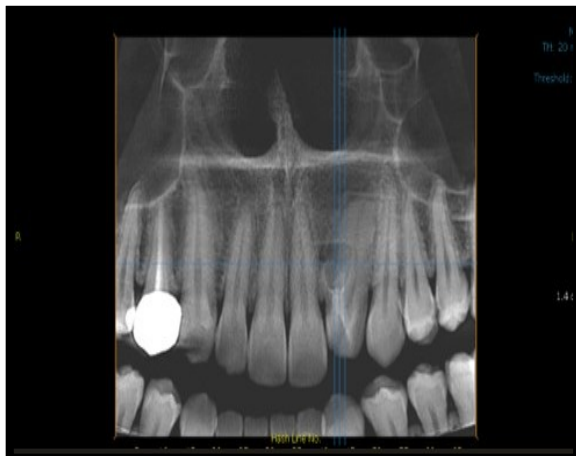
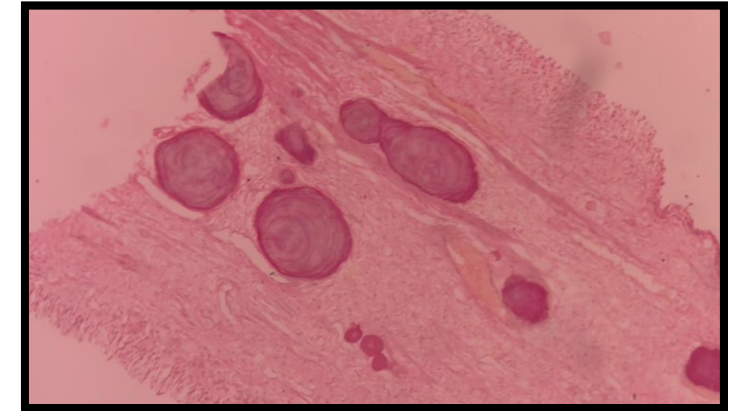
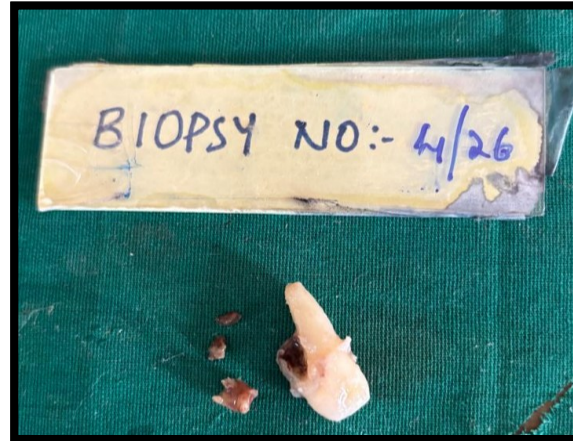


NAME:M.SREENIKA **AGE/SEX:**21/FEMALE **OP NO-**202601050110 **BIOPSY NO:** 4/26 **DATE:** 4/01/26
DIAGNOSIS: LATERAL RADICULAR CYST ASSOCIATED WITH DENS INVAGINATUS
STAFF INCHARGE:DR.G.ASHALATA
PG INCHARGE: DR. V.SHAILUSHA(III)YR, DR.T.AKHILA(II)YR, DR.SUMAYYA(I)YR

RADIOGRAPHIC PICTURES



GROSSING PICTURE HISTOPATHOLOGICAL PICTURES



NAME : POOJA

AGE/SEX : 33/F

IP.NO: 202603110087

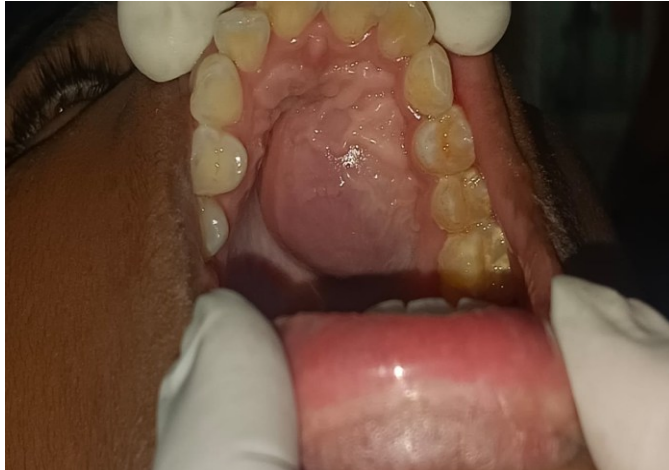
BIOPSY NO: 64/26

DATE : 14/03/26

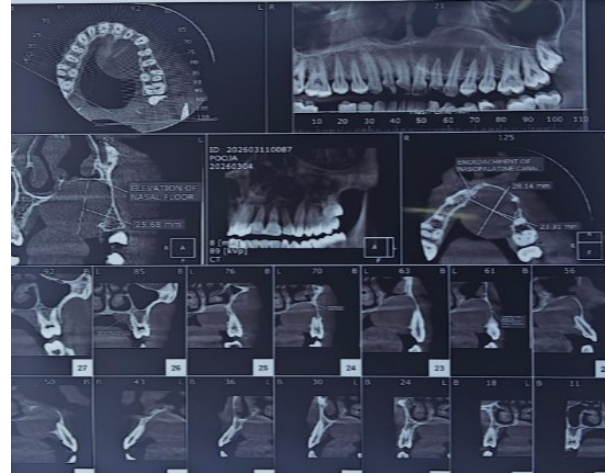
DIAGNOSIS : ACTINOMYCOSIS

STAFF INCHARGE : DR.A. BHARGHAVI KRISHNA **PG INCHARGE :** DR. B. SUMATHI

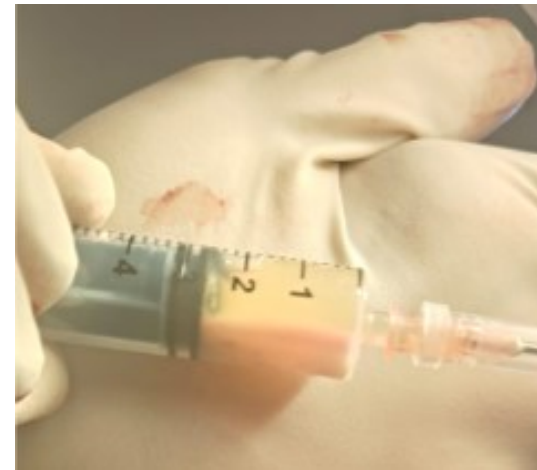CLINICAL PICTURES



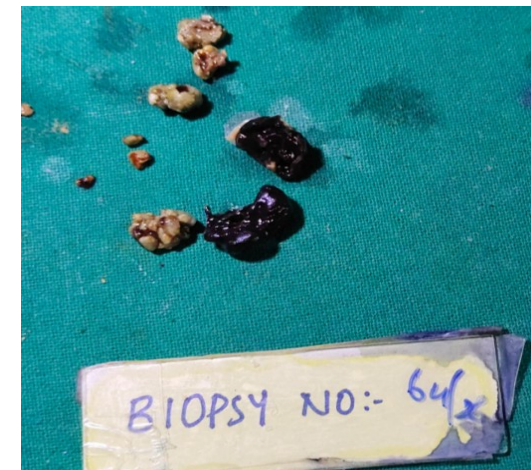
RADIGRAPHIC PICTURES



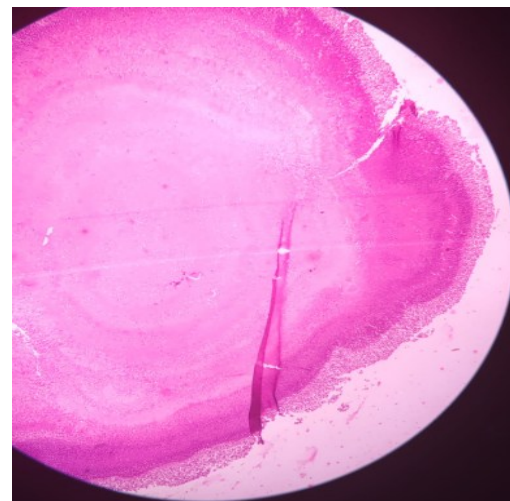
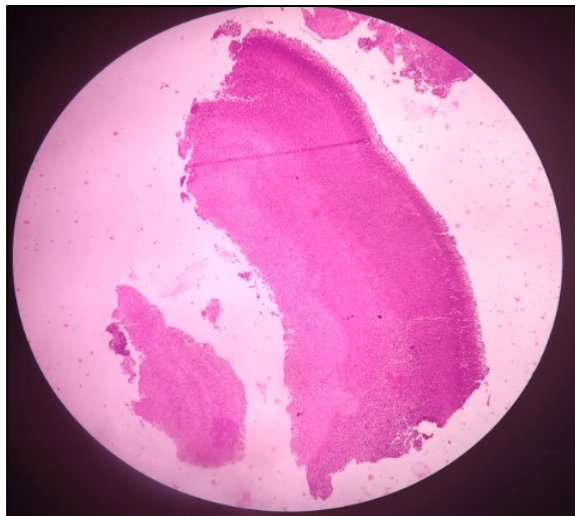
ASPIRATION LIQUID



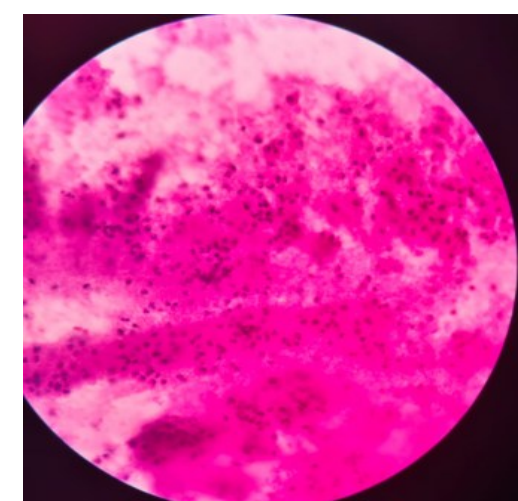
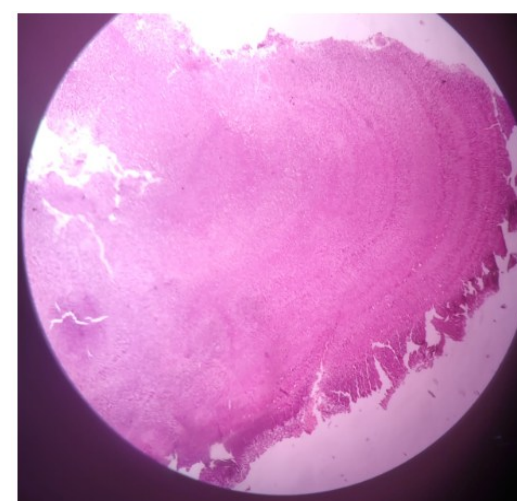
GROSSING PICTURE



HISTOPATHOLOGICAL PICTURES : BIOPSY



HISTOPATHOLOGICAL PICTURE : CYTOLOGY



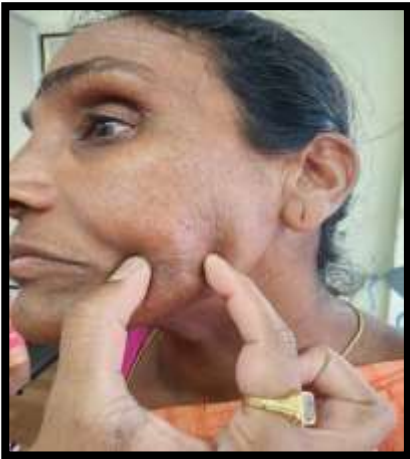NAME: Radha **AGE/SEX:** 40/F **OP.NO-** 202604080100 **BIOPSY NO:**81/26 **DATE:** 8/4/26

DIAGNOSIS: XANTHOGRANULOMATOUS REACTION

STAFF INCHARGE: DR.P. VENKAT BHAGIRATH, DR.D. JYOTHSNA

PG INCHARGE: DR. T. AKHILA, DR. S. JYOTSNA

CLINICAL PICTURES



GROSSING PICTURES



HISTOPATHOLOGICAL PICTURES

