

CASE 1: VERTICAL TUNNELLING TECHNIQUE USING e-PRF & XENOGRAFT

Name: Nagapothana **Age/ sex:** 29/M **Op no :** 202511270004

Diagnosis: Localized periodontitis

Treatment: Vertical tunneling technique using E-Prf and xenograft irt 32,42

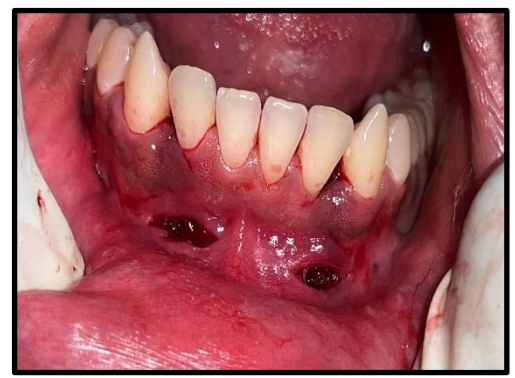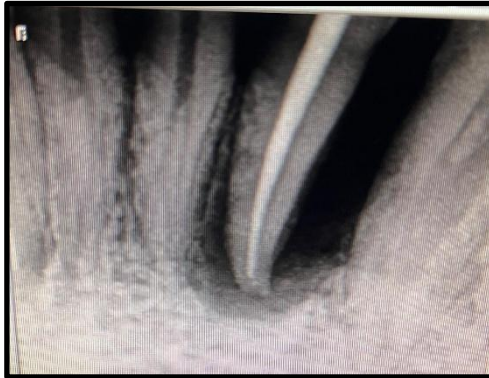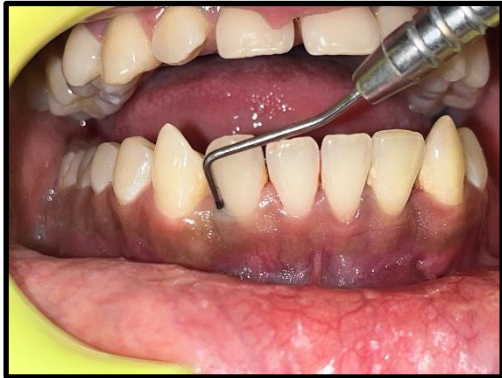Professor: Dr J Surya Prasanna

Post graduate: Dr Greeshma

PREOPERATIVE

PRE-OP RADIOGRAPH

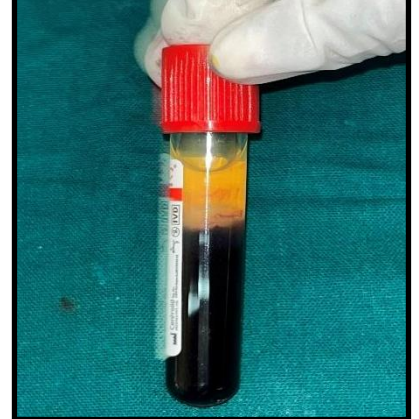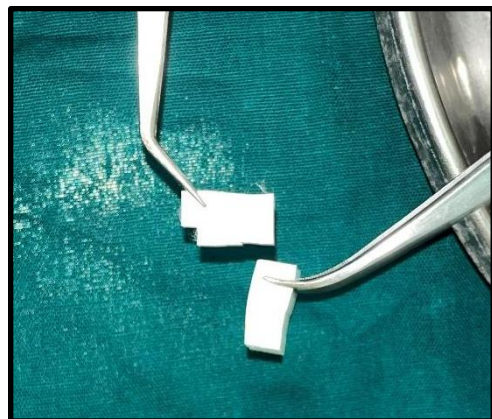
INCISION



MEMBRANE

E-PRF-PREP

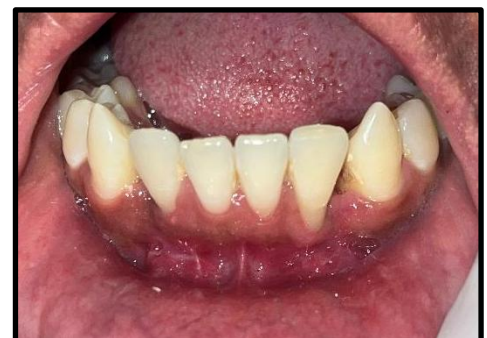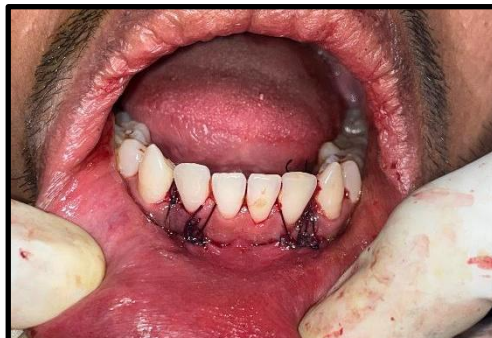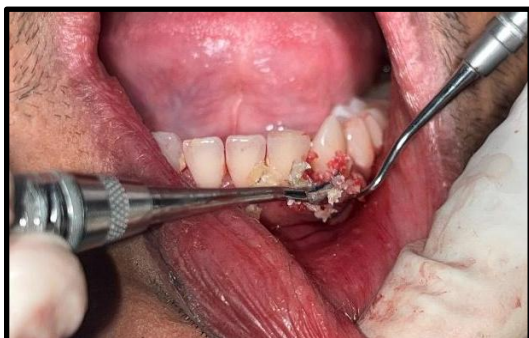E-PRF



e-PRF + GRAFT PLACED

SUTURING

POST-OPERATIVE



CASE 2: RECESSION COVERAGE USING DE-EPITHELIALIZED GRAFT

NAME: SURESH AGE/SEX: 25/M OP NO.: 202510130067

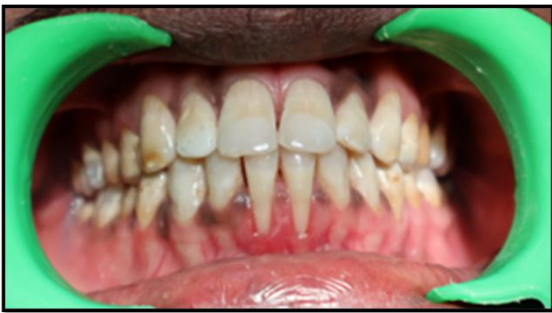DIAGNOSIS: GINGIVAL RECESSION

TREATMENT: DE-EPITHELIALIZED FREE GINGIVAL GRAFT FOR RECESSION COVERAGE

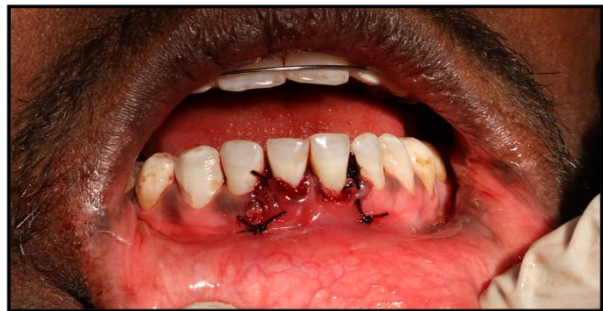PROFESSORS: Dr K. REKHA RANI

POSTGRADUATE: Dr G SHIVANI

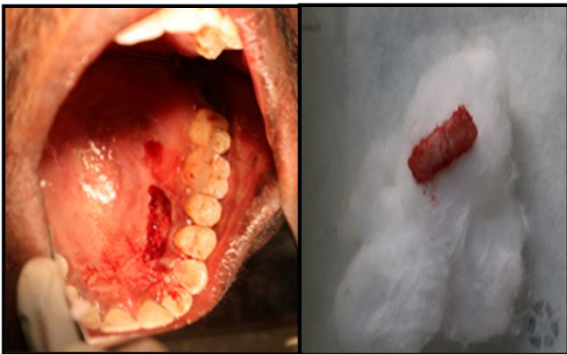PRE OPERATIVE



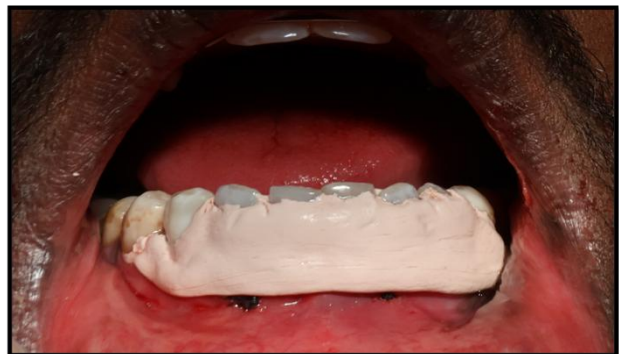SUTURING DONE



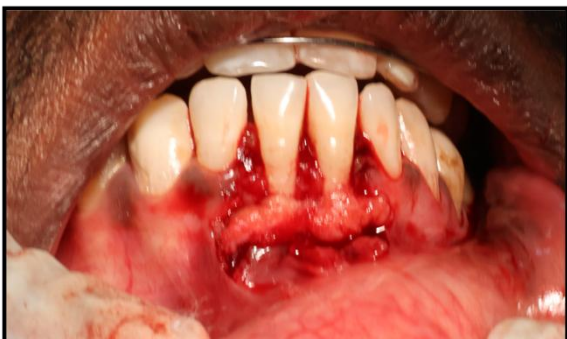FREE GINGIVAL GRAFT FROM DONOR SITE



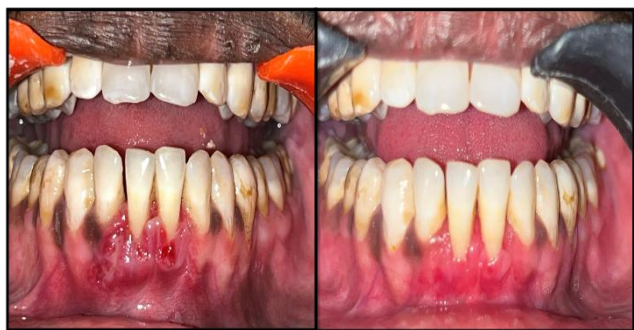COE-PACK PLACED



GRAFT PLACEMENT



FOLLOW UP (2WEEK & 4WEEK)



CASE 3: SURGICAL EXCISION OF PERIPHERAL OSSIFYING FIBROMA

NAME: VENKATESHWARULU **AGE/SEX:** 44/M **OP NO.:** 202501232441

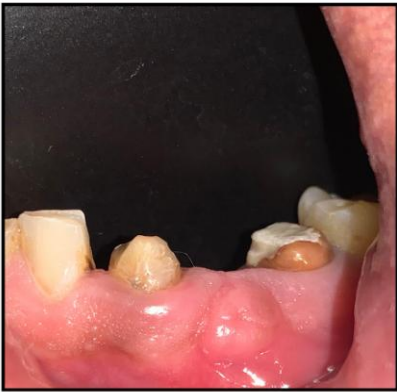DIAGNOSIS: PERIPHERAL OSSIFYING FIBROMA

TREATMENT: OPEN FLAP DEBRIDEMENT FOLLOWED BY PROSTHETIC REHABILITATION

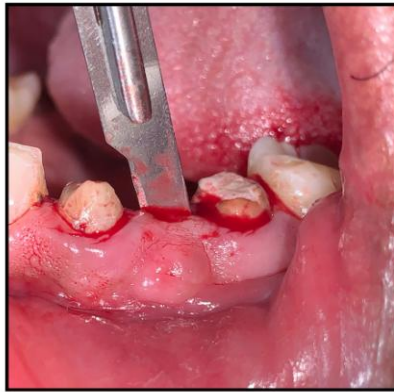
PROFESSOR: Dr. P. VEERENDRA NATH REDDY

POSTGRADUATE: Dr. MIR SUHAILUDDIN

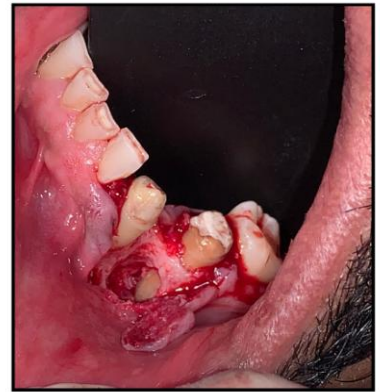PRE OPERATIVE INTRAORAL
VIEW



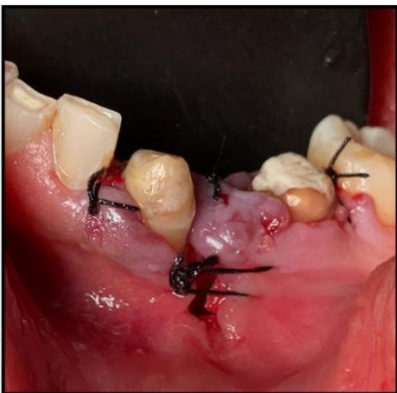INCISION



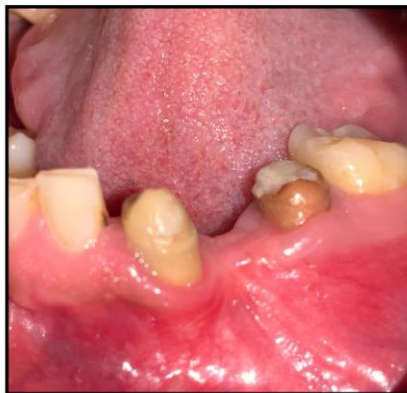SURGICAL SITE AFTER
EXCISION



SUTURE PLACEMENT



POST OPERATIVE HEALING



PROSTHETIC REHABILITATION

