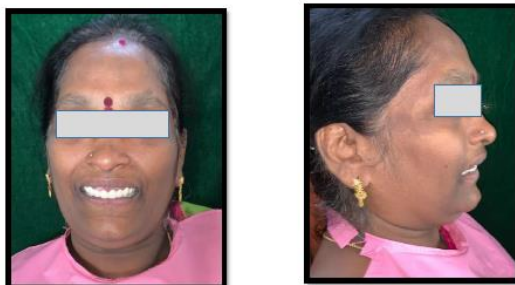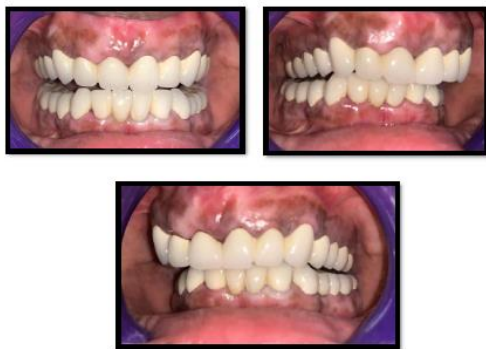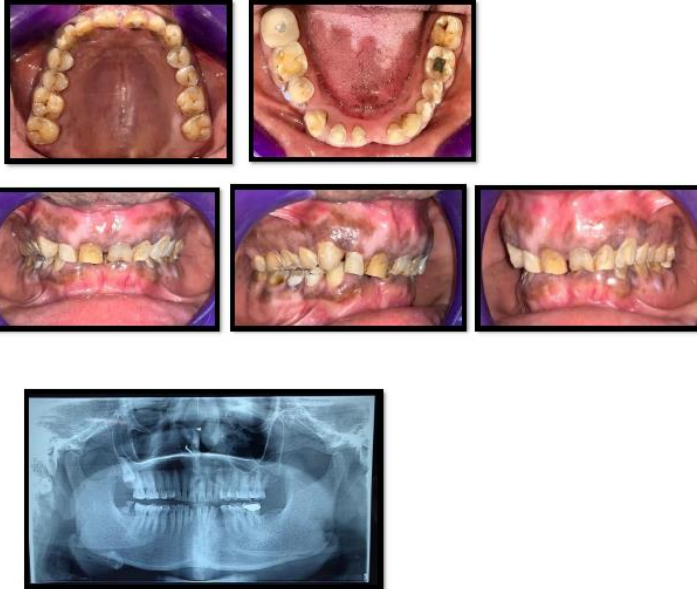


MANAGEMENT OF WORN-OUT TEETH WITH FULL MOUTH REHABILITATION

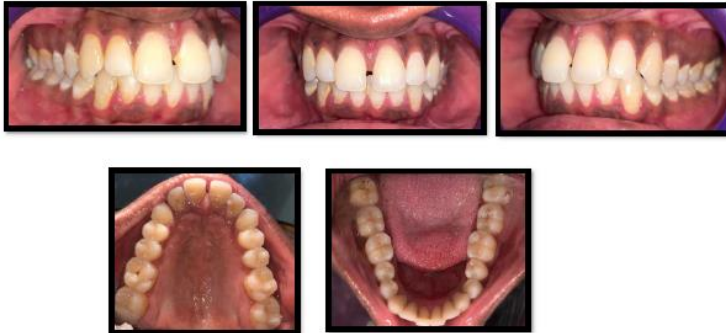PRE-OPERATIVE PHOTOGRAPHS

INTRAORAL VIEW

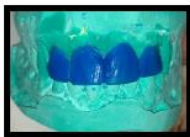

AESTHETIC REHABILITATION OF MIDLINE DIASTEMA USING VENEERS

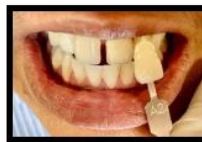PREOPERATIVE VIEW



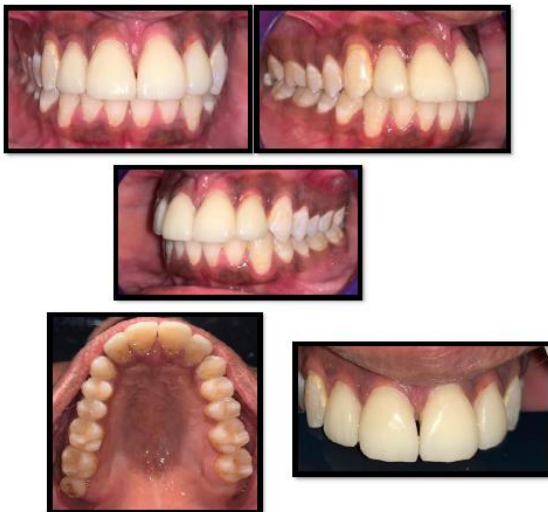WAX-UP



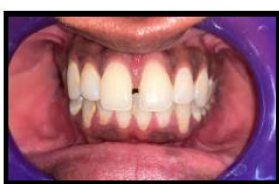SHADE SELECTION



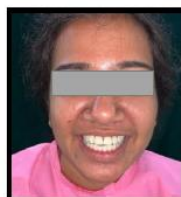POST OPERATIVE VIEW



BEFORE



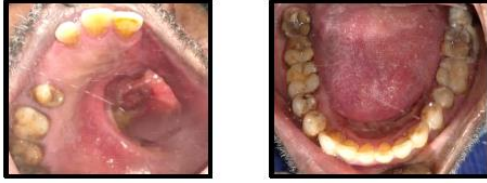AFTER



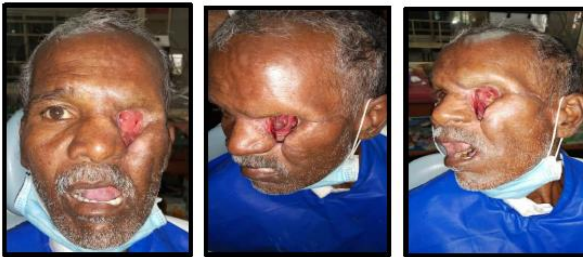**ORBITAL PROSTHESIS AND OBTURATOR**

PATIENT NAME: NAGAPPA  
AGE :58 YEARS/MALE  
2012260031

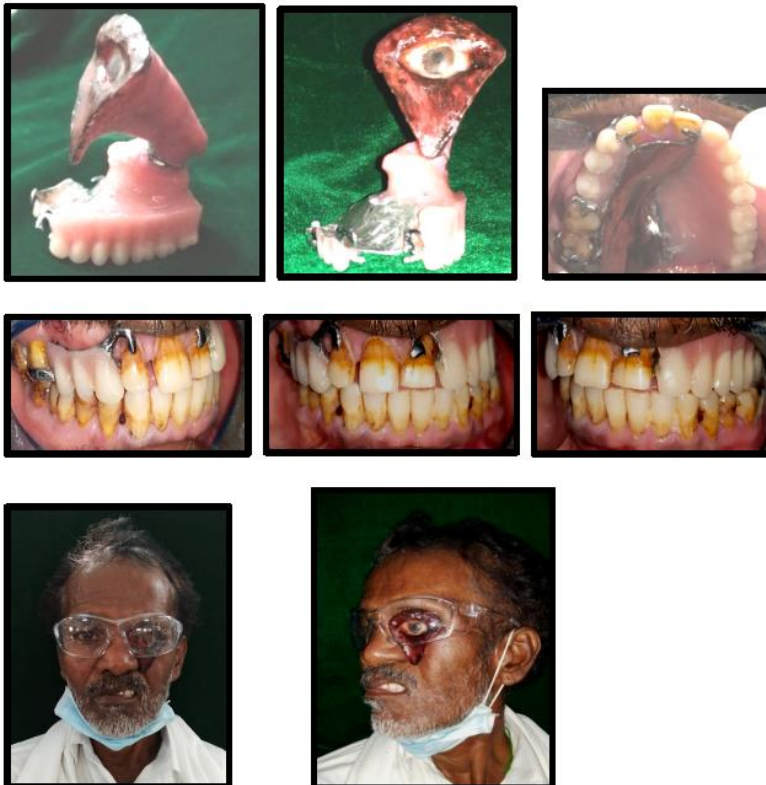**RAL VIEW**



**EXTRA ORAL VIEW**

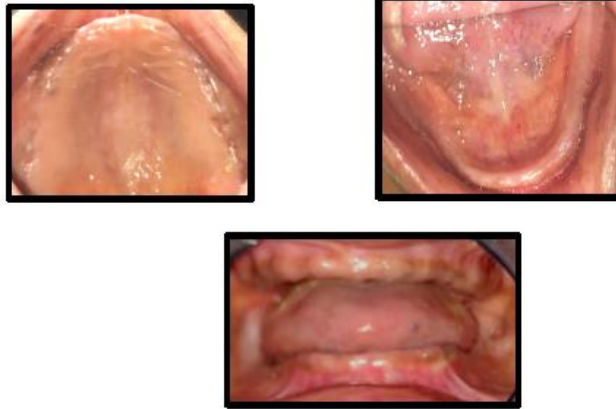


**MAGNETIC ATTACHMENT BETWEEN ORBITAL PROSTHESIS AND OBTURATOR**

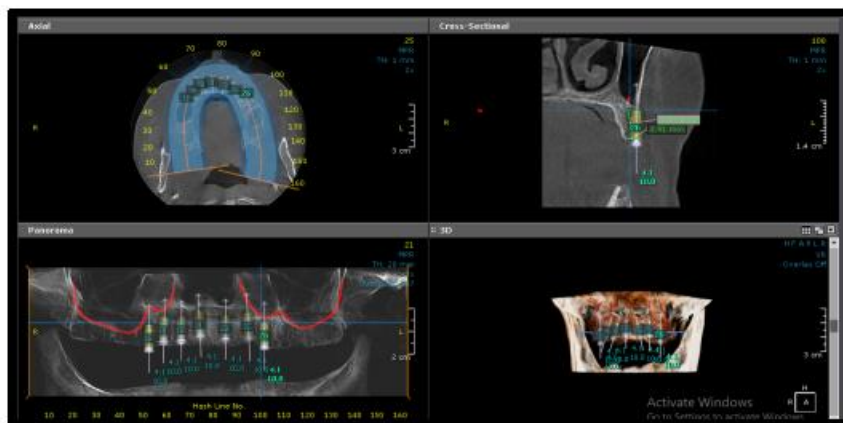
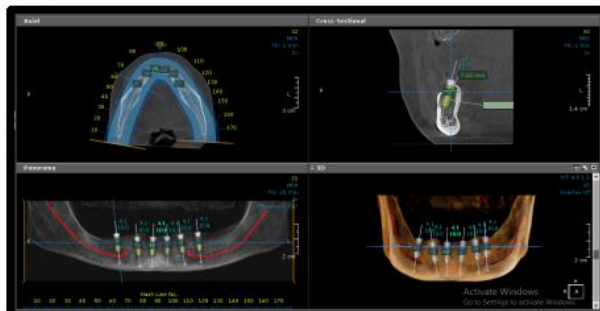


# FULL MOUTH REHABILITATION WITH IMPLANTS

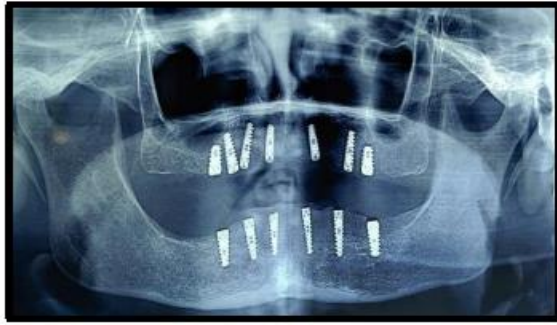## PRE-OPERATIVE INTRAORALVIEW



## CBCT PLANNING







**OPG AFTER IMPLANT PLACEMENT IN MAXILLARY ARCH**

**METAL CERAMIC BRIDGE CEMENTATION DONE**

